



IFSSH Scientific Committee on Skin Coverage

Chair: Maurizio Calcagni (Switzerland)

Committee: Roberto Adani (Italy)
Sylvie Carmes (France)
Christian Dumontier (France)
David Elliot (United Kingdom)
Thomas Giesen (Switzerland)

Report submitted October 2014

Skin coverage in hand reconstruction is a challenging and vast chapter in Hand Surgery and to cover every aspect of it in a report is simply not feasible. Therefore this report focuses on a few specific topics.

The coverage of anatomical districts like the fingertips is common ground for the Hand Surgeon worldwide, but in the last ten years different refinements have been published in order to optimize the reconstruction of this organ. Nevertheless, in many emergency departments the amputation of badly injured fingertips, including the thumb, remains the preferred treatment. The main focus of this report is to counter this tendency, providing alternatives to the surgeons.

Large defects to the digits involving more than one segment, defects to the palm and to the dorsum of the hand are currently debated in international meetings. The use of skin substitutes vs. the use of extremely refined microsurgical procedures vs. classic island flaps is the basis of animated discussions, which are also influenced by cultural and socio economic factors around the world. This report offers the views of six different surgeons from four different countries, in the hope of animating discussions and to suggest new approaches.

FINGERTIP RECONSTRUCTION: The role of conservative treatment

Sylvie Carmes and Christian Dumontier, France

As fingertip injuries are by far the most frequent finger injuries, one could expect that guidelines now exist to help emergency doctors as well as specialists to choose between treatment options. This is not yet the case. Treatment options in literature vary from the simplest conservative treatment to the most sophisticated microsurgical reconstruction. Regarding conservative treatment, some questions still arise:

What does conservative treatment mean?

In most publications, conservative treatment means lavage and debridement under local anaesthesia. Protrusive bone, if present, is removed by 2mm to 5mm under the level of soft-tissue. Dressings using paraffin tulle changed every two or three days has been extensively used with good results (Chow and How, 1982. Ipsen et al., 1987). However as the authors had often experienced difficulty in removing such dressings, which may damage the underlying granulation tissue, experiments have been made using bacitracine ointment (Lamon et al., 1983), Hyphecan (Hyphecan Care Limited, Kwai Chung, Hong Kong), polyurethane foam (Williamson et al., 1987), silver sulphadiazine (de Boer and Collinson, 1981; Riyat et al., 1997). In some series, dressing changes were made 2-4 times a day (Farrell et al., 1977).

As early as 1977 (Fox et al., 1977) occlusive dressings leaving a moist environment have also been proposed and Mennen (Mennen and Wiese, 1993) presented his experience in 1993 without debridement and the use of "Opsite" (Smith and Nephew Corporate,

London, UK) changed only every week. His technique and results have been reproduced by others in large series (Mühldorfer-Fodor et al., 2013). The idea behind it is that fluid and enzyme around the tip promote healing.

What are the expected results?

Results have been studied in a small series of 17 cases (Farrellet al., 1977) to a larger series of 200 cases (Mennen and Wiese, 1993; Muehldorfer et al., 2013) with 3 to 6 months follow-up. One series reporting 20 cases at 2 to 6 years follow-up showed similar results as those series with a shorter follow-up. Some of these series were prospective (Chow and How 1982; Ipsen et al., 1987, Williamson et al., 1987).

Healing time took 3 to 5 weeks on average with extremes between 2 to 12 weeks, with larger injuries and exposed bone taking a longer time to heal than less severe injuries. According to the dressing protocol 3 to 29 dressing changes were necessary.

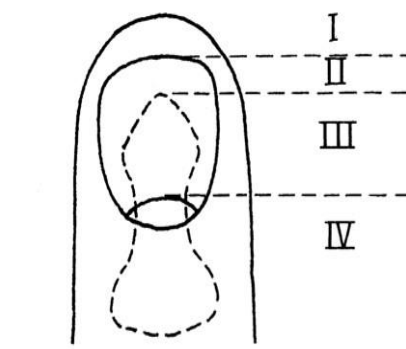
Accordingly return to work took from 2 to 60 days with an average of 20 days

Most series reported no infection. Only in Lee's series (3%) and Lamon's (8%) were minor infections reported. Pulp sensitivity was considered normal in 50% to 80% of patients. When measured, Weber's two point discrimination was increased by 1mm average in Ipsen's series, it was between 2.25mm and 4.1mm in Riyat's series, or double compared to normal (6mm vs 3mm) in Lamon's series.

Results were considered good to excellent in 90% to 100% of cases. Authors insisted on the remodeled "fingerprint" and barely visible scars, regular perspiration, and very limited disability. Pulp tenderness was present in about 20% of cases (Riyat et al., 1997; Ipsen et al., 1987) but was less frequent than with other methods. Pulp shortening or problems were few, while nail dystrophies were considered frequent, varying between 25% to 60% (Chow et al., 1982; Ipsen et al., 1987; Riyat et al., 1997). Only half of them were disabling. Nail dystrophies were reported in only 50% of cases if the injury is in the distal third of the sterile matrix (Chow et al., 1982).

Which type of conservative treatment is superior to the others?

None has really proved superior. In Allen's type I and II injuries (Fig 1 - below), dressing change was less painful in the silver sulphadiazine group compared to Paraffin, while at 3 weeks the fingertip was more sensitive. Healing was faster in the paraffin group, but shrinkage and shortening was also more evident (Riyat et al., 1997). It seems that occlusive dressing without initial debridement is simpler to use, results in more comfortable dressing, and dressing change. Occlusive dressings may result in less wound contraction and a more cosmetically acceptable outcome.



When should conservative treatment not be used?

This is the major question. Particular emphasis is placed on involvement of distal phalangeal bone and nail matrix. However there is a high disparity in the literature that comes from variation in the injuries themselves with respect to orientation, tissue quality, vascularity, and patient factors such as age, hand use and occupation, smoking history, and concurrent diseases.

What is obvious is that, when compared to other treatment modalities, conservative treatment is always favourable. Results of conservative treatment were superior to other types of treatment including flaps, with less pain and stiffness, less disability, faster healing time and fewer complications in Chow's series of 200 cases. There were no differences in functional and aesthetic outcomes at one year follow up in Söderberg's series. When comparing 7 types of treatment, simple dressings gave excellent results in Ma's series (Ma et al., 1982). Recently, Van den Berg (Van den Berg et al., 2012) found that the outcome of treatment of Allen II, III, and IV fingertip injuries (Fig 1) was irrespective of the treatment chosen. From the literature it appears that bone exposure is not a major problem if the bone is not protruding. However, except for the most simple sterile nail matrix injuries, nail dystrophies will not be avoided with conservative treatment. Using Evans PNB classification (Table 1), Muneuchi (Muneuchi et al., 2005) found that the boundaries between surgical treatment and conservative treatment were PNB 386, 666 and 700.

Table 1: The PNB Classification for fingertip amputation

PULP	0	No injury
	1	Laceration
	2	Crush
	3	Loss-distal transverse
	4	Loss-palmar oblique partial
	5	Loss-dorsal oblique
	6	Loss-lateral
	7	Loss-complete
NAIL	0	No injury
	1	Sterile matrix laceration
	2	Germinal + sterile matrix laceration
	3	Crush
	4	Proximal nailbed dislocation
	5	Loss-distal third
	6	Loss-distal two thirds
	7	Loss-lateral
	8	Loss-complete
BONE	0	No injury
	1	Tuft fracture
	2	Comminuted non articular fracture
	3	Articular fracture
	4	Displaced basal fracture
	5	Tip exposure
	6	Loss-distal half
	7	Loss-subtotal (tendon insertion intact)
	8	Loss-complete

No new treatment modalities have emerged in the last ten years. What is now obvious is that there was a period of enthusiasm for fingertip reconstruction using flaps, “with evidence that reconstruction with one of the many available flaps will generally yield satisfactory results with adequate soft tissue coverage, preservation of tip length and contour, return of protective sensation, and minimal donor-site morbidity“ (Bickel and Dosanjh, 2008). However, with the use of flaps, up to 35% of complications have been encountered (Henry, 2008) and published results are not superior to those obtained with conservative treatment. This means that in the early 21st century, if two thirds of the distal phalanx remains, or if the nail bed defect ranges from one third to one half there is no need for surgical treatment.

David Elliot, UK

Perhaps the single most important and useful technique of digital reconstruction is the exploitation of the astonishing ability of the skin of the digits to close defects of considerable size by a combination of wound contraction and re-epithelialisation to give a cosmetic and functional result which cannot be bettered by any surgical procedure. This ability is well recognised and exploited in the management of digital tip injuries (Allen 1980; Chow and Ho 1982; Lee et al 1995; Mennen and Wiese 1993). In a moist environment, in the absence of infection, this occurs relatively quickly, not only at the tips but also on the other aspects of the digits. Galen recognised this almost two millennia ago and, two millennia before Galen, the Smith papyrus describes several hundred means of achieving healing of skin wounds by covering them with mixtures of honey and animal fats in ancient Egypt. Skin grafting of all defects of the digits has been a particular feature of plastic surgical management of hand injuries during the last fifty years which is often unnecessary and introduces further morbidity and delay of mobilisation. Healing open wounds under dressings avoids the creation of secondary donor sites and the patient can be encouraged to move if the bandaging is reduced to the minimum necessary to provide a moist environment for the raw area. The opportunity of dressing changes is used to encourage movement under water. This is both comfortable and helps debride the wounds. A further advantage of open wound management is that the oedema which is responsible for much of the long-term morbidity of digital injuries is not retained in the digit but leaks out of the open wound during early mobilisation. While the dogma of skin grafting has been dispelled for digital tip injuries without bone exposure, it is, unfortunately, still common practice in many hand surgery units to graft all skin defects of other parts of the digits.

If skin can replace itself under moist antiseptic dressings, then operating to achieve skin cover, per se, is a dubious indication for surgery. However, we do require well-vascularised subcutaneous soft tissue to provide adequate protection of the bone at the digital tip, if exposed. With slight bone exposure, the bone may be nibbled back until it is covered by subcutaneous pulp tissue. The skin wound is then healed by secondary intention under moist antiseptic dressings. In doing this, we have accepted very slight digital shortening in exchange for a simple plan of management. In most other circumstances, we are committed to moving flaps. In a ragged injury with significant bone exposure, there may be lengths of soft tissues adjacent to the amputation stump

which are adequately vascularised and of sufficient size to provide bone cover: these “opportunistic flaps” can be used to convert the tip into a skin wound which can be healed by dressings (Fig 2).

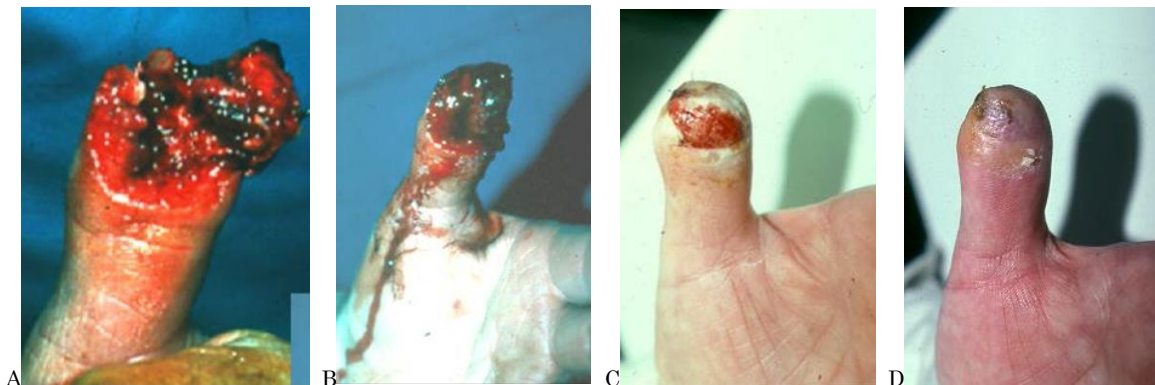

Figure 2: (A,B) Thumb primarily closed with opportunistic flap leaving a large raw area with no bone exposure. (C,D) Healing following daily moist dressing change

Where such opportunity for simple reconstruction of the digital tip does not exist, finger length can be maintained at that of the amputation by the use of flap reconstruction of the stump. Homodigital reconstruction involves rearrangement of the soft tissues of the injured digit to achieve healing without seeking tissue for reconstruction from outside that digit (Mouchet and Gilbert, 1982; Schiund et al., 1985; Foucher et al., 1989). While this concept of reconstruction has definite advantages of reconstructing ‘like with like’ and avoiding further scarring and morbidity elsewhere on the hand or body, the availability of donor tissue within an injured digit is obviously limited. Many of the injuries for which homodigital advancement flaps are used are palmar oblique with the amputation removing both skin and subcutaneous soft tissue distally to expose the bone but removing only skin proximally. We do not excise the pulp which is denuded of skin cover but use it as the leading edge of the advancement flap(s), so lengthening the flap and reducing the extent to which it must be advanced. This technique does not allow direct skin to nail approximation but achieves cover of the distal bone with soft tissue. The digital tip is, thus, converted into an injury which can be epithelialised under dressings. A secondary benefit of this method of advancing homodigital flaps is that the process of epithelialisation helps to round off the digital tips and improves their final appearance.

FINGERTIP RECONSTRUCTION: The Traumatic nail complex

Sylvie Carmes and Christian Dumontier, France

In this short report, we will only focus on acute nail complex injuries and will not discuss reconstruction or the treatment of associated phalangeal fractures.

Since the publications of Zook and Shepard in the 80’s (Zook, 1981; Shepard, 1983), few publications have been presented regarding the high frequency of nail complex trauma.

Most of them are technical tips that improve both the safety of the treatment and the quality of the functional as well as aesthetic results.

Nail traumas represent 8% of all finger injuries in adults and 5% to 6% of child trauma (Duthie and Adams, 1984; Guy, 1990; Ardouin et al, 1997). The middle finger and thumb are the digits most frequently involved. A crushing mechanism is the most frequent cause of the lesion. In one personal series of almost 200 cases (Carmès et al. under submission), surgical exploration found: 47 isolated lesions of the nail plate (25%), 103 nail bed lesions (55%), 14 matrix (+/- bed) lesions and 23 nail bed hematomas (12.3%). In 134 cases (71.65%) there was an associated lesion: of the pulp in 50 cases (26.7%), of the distal phalanx in 29 cases (15.5%), an associated pulp and phalangeal lesion in 49 cases (26.2%) and another lesion of the finger or hand in 22 cases (11.8%). The associated lesion was on the same finger in 128 cases.

Should all nail trauma be treated?

Nail complex and fingertip injuries are frequently associated. Although conservative treatment usually gives good results for pulp injuries, nail dystrophies are always present (up to 60% of cases) except for the most minor injuries involving less than a third of the distal nail bed (Chow, 1982; Ipsen, 1987). Only half of them were disabling. We believe that nail injuries should be treated as a separate entity, whatever the treatment of associated lesions may be, as inadequate treatment may lead to severe disabling sequelae while early treatment usually gives good to excellent results (Ardouin et al, 1997; Inglefield et al.,1995; Shepard, 1990).

Nail plate injuries

Nail plate injuries are the less severe lesions and one should ask whether or not the nail plate should be replaced. O'Shaughnessy et al. found no difference whether or not the nail plate was replaced (O'Shaughnessy, 1990), however Zook recommended replacement and found that its non-replacement gave less satisfactory results (Zook et al., 1984). Recently, nail replacement in paediatric cases has been challenged and Miranda (2013) considered its replacement as more detrimental than absence of nail plate or substitute. We use sutures that do not pass through the nail complex but only pass through the lateral side of the pulp. Others do not fix the nail plate anymore and have found that the plate quickly adheres to the nail bed and will stay in place if the dressing is changed carefully. (Tos, 2012).

If one chooses to replace the nail plate when absent or destroyed, among the many substitutes that have been proposed, we use, as do others (Tos et al., 2009), the bubble trap (reservoir) of a perfusion set, as the natural curvature is adapted to most nails. This substitute is sterile, inexpensive, and easily available in emergency and elective operating theatres. A small hole in its proximal part is made to allow for drainage.

Nail haematomas

There are many discussions about the best treatment option for subungual nail haematomas (Mignemi et al., 2013). Only large subungual haematomas present with lesions that are amenable to repair (Simon and Wolgin, 1987) but surgical exploration is still questionable (Seaberg et al., 1991). We have chosen to explore those patients whose subungual hematomas were over 50% of the surface of the nail plate; this is a current trend today as the quality of nail edges is regarded as more important than the percentage of hematoma (Sommer and Brown, 2011).

Nail bed and/or matrix wounds

Zook (1981; 1984) and Shepard (1983, 1990) emphasized the need for meticulous repair using loops and small sutures (6/0 or under). To get access to the underlying tissue, removal of the nail plate is mandatory. Partial removal can be done for nail tumor surgery but is not indicated in trauma cases.

To get access to the nail matrix, surgical incision at the junction of the proximal and lateral nail wall, as described by Kanavel, is necessary. One of the incisions can be prolonged over the second phalanx if a rotation-advancement flap is needed to reconstruct the proximal nail wall.

Large debridement is not necessary due to the good vascularization of the tissues and approximation sutures are all that is needed as the nail bed or matrix do not glide over the distal phalanx. All nail bed/matrix fragments are preserved and replaced as free grafts in order to attain an optimal final result. Any irregularities of the wound edges of the nail bed or matrix should be avoided. We believe that moulding the repair using the nail plate or a substitute is a useful adjunct. We have no experience with the use of cyanoacrylate for the repair of nail bed wounds.

Nail fold reconstruction

Nail fold integrity is needed in order to have a normal nail shape. Reconstruction is made using local flaps, most of them being designed for burn injuries.

However in distal finger amputation, the nail is shortened and this is sometimes badly tolerated from an aesthetic point of view. This is why Bakhach (1998) proposed a proximal-sliding eponychial flap to lengthen the visible portion of the nail plate. Merlino et al. (2011) reported 28 cases with a little technical modification. Chinese authors reported over 300 cases by simply resecting the distal free edge of the eponychium (proximal wall) (Wang and Yuan, 2012). Whatever the technique chosen, aesthetically it is worthwhile lengthening the visible part of the nail plate in distal transverse amputations of the fingertip that are unsuitable for replantation.

Loss of substance of nail bed / matrix

These are more severe injuries and according to Shepard (1983, 1990), nail bed loss should be treated with split-thickness nail bed grafts, taken either from the same finger (rarely possible in our experience) or the great toe (which leaves about 25% of patients with some nail dystrophies). Sometimes a bank finger, when the injured finger is not available for replantation, may be used as a donor site.

However, nail bed replacement has been challenged by Ogo (1987) and Ogunro (Ogunro, 1989, Ogunro and Ogunro, 2007) who believe that a nail plate substitute may instigate spontaneous healing. It is likely that small losses of substance do not need grafting, however we do still consider nail bed grafting for loss of substance of at least one-third of the nail bed. However, Lemperle (Lemperle et al., 2003) used the potential "regeneration process of the nail" in 11 patients and reported satisfactory results.

For distal loss of substance of the nail bed, we described with Foucher a distally de-epidermised VY volar flap to "graft" the distal loss of substance of the nail bed (Dumontier et al., 1992). We still use this technique as it is simple and easy to perform and the results justify trying it.

Nail matrix loss of substance will lead to the most dystrophic nails, especially if the eponychium is injured. Translation flaps (Schernberg and Ameil, 1987) may be used in the most severe cases, but with average results at most. We have no experience with nail matrix graft done in emergency except with the use of a bank finger. For a matrix graft, full-thickness graft is necessary.

FINGERTIP RECONSTRUCTION: Flap reconstruction

David Elliot, UK

The Neurovascular Tranquilli-Leali

The type of flap reconstruction which is appropriate for digital tip reconstruction depends on the extent and configuration of the tip loss. In those amputations which are oblique, the direction and degree of obliquity are also of significance in our choice of flaps.

In transverse amputations beyond the mid-nail level and dorsal oblique amputations beyond the proximal nail fold, a Tranquilli-Leali or Atasoy flap works well (Tranquilli-Leali 1935; Atasoy et al 1970). The flap remains vascularised through small vessels, beyond the trifurcations of the digital arteries, within the subcutaneous pulp tissue lateral to the body of the flap. This flap can achieve the slight advancement needed to suture the skin to the nail in such cases. However, with greater losses of finger length and in palmar oblique injuries, even at this level, this flap is too small and cannot advance sufficiently to create a well-rounded digital tip with adequate bone cover.

In those palmar and sagittal oblique fingertip amputations which have a slope of 30 degrees, or less, we use a variant of the Tranquilli-Leali flap which we have called the "Neurovascular Tranquilli-Leali" flap (Elliot et al., 1995). This flap has the same shape as the original flap but is larger, extending to, or across, the DIP joint crease proximally. It is islanded on both neurovascular pedicles. The incisions of the V cross the distal interphalangeal joint crease at an angle and thus do not cause contractures. When designing the flap one takes the V incisions out almost to the lateral nail folds distally. Having made the flap wide, the leading edge of the flap after advancement is wider than the original fingertip. Unless the lateral corners of the flap are excised, this results in an ugly broad end to the digit. Cutting off the lateral corners and allowing the resulting raw edges and tip to epithelialize not only narrows the digital tip but also rounds it to achieve a good appearance. Many of the injuries for which these advancement flaps are being used are palmar oblique with the amputation removing both skin and subcutaneous soft tissue distally to expose the bone but removing only skin proximally. We do not excise the pulp which is denuded of skin cover but use it as the leading edge of the advancement flap(s), so lengthening the flap and reducing the extent to which it must be advanced. This technique does not allow direct skin to nail approximation but achieves cover of the distal bone with soft tissue. The digital tip is, thus, converted into an injury which can be epithelialised under dressings. A secondary benefit of this method of using advancement flaps is that the process of epithelialisation helps to round off the digital tips and improves their final appearance. Although all of the advancement flaps we use are designed as a 'V' at their proximal extremity and were conceived to close proximally as a 'Y' after the flap has moved distally, the proximal donor defects are usually left open to close under dressings as closing the vertical limb of the 'Y' tightens the finger proximal to the vascular pedicles of the flaps.

Generally, even in very distal amputations of suitable shape, the bipedicle Tranquilli-Leali or Atasoy flap does not work well on the thumb because of the inflexibility of the subcutaneous soft tissues. The neurovascular Tranquilli-Leali flap also moves less freely than on a finger, partly because of the fibrous nature of the subcutaneous tissues of the thumb and partly because of what has been described as the 'vertical dimension' of the thumb, that is its palmar-dorsal width at the tip (Gaul, 1987). On fingers, it can be used to reconstruct defects with a palmar slope of up to 30 degrees; on the thumb it can only reconstruct defects with bone exposure which are dorsally facing, transverse or palmar facing with less than 10 degrees of slope.

This flap can be used for stump reconstruction of any length of amputated finger or thumb and we find this version of the Tranquilli-Leali flap much more useful than the original.

For more sloping palmar oblique defects, we use two alternatives. To reconstruct the thumb tip, we use O'Brien's modification of the bipediced Moberg flap (Moberg, 1964; O'Brien, 1968) with the addition of a 'V' tail proximally instead of a skin graft (Elliot and Wilson, 1993). There is no danger in raising Moberg-type flaps on the thumb, as the dorsal skin of the thumb has a separate blood supply. However, on the fingers, there is a risk of loss of the dorsal skin if the lateral incisions of the palmar flap cut the dorsal branches of the digital arteries feeding the dorsal skin (Snow, 1967). More recently, this

flap has been re-described by Kojima et al (1994) but preserving the dorsal arterial branches, so making it safe for use in the fingers. For more sloping palmar oblique defects of the fingertip, we use the single pedicle, an extended version of the Segmüller flap (Segmüller, 1976) or the Venkataswami flap (Venkataswami and Subramanian, 2000).

The Segmüller Flap

Homodigital advancement flaps are of particular value in respect of their ability to replace the missing fingertip after amputation with similar and innervated soft tissues, while retaining digital length at, or near to, that of the level of amputation. The lateral V-Y flap, based on the small vessels of the distal digital pulp tissue, was first described as a unilateral flap by Geissendorfer (1943) and, later, used as bilateral flaps by Kutler (1947) and others. The Geissendorfer/Kutler flap was designed as a triangle on the lateral aspect of the distal segment of the finger with the apex of the triangle proximal and the flap raised on the microcirculation of the subcutaneous pulp tissue beyond the trifurcation of the neurovascular bundle. It continues to be described in most textbooks and continues to disappoint with its failure to advance as much as shown in line drawings. The minor modification described by Shephard (1983) is only a little better. A larger, but less well known, lateral V-Y flap, with the apex taken back to the DIP joint crease and islanded on the neurovascular bundle was first described in Switzerland by Segmüller (Segmüller, 1976) and again, independently in South Africa, by Biddulph (1979). This flap is more useful, being more mobile and capable of greater advancement. However, these flaps remain confined to the terminal segment of the finger, so still have limited potential for advancement. Lanzetta et al (1995) reported the use of longer Segmüller flaps in 5 cases with good results. Independently, over the same period, we also developed flaps based on the Segmüller principle, but extending proximally into the middle and, even, into the proximal segment of the digit, to achieve larger flaps which are capable of greater advancement and, so, greater versatility (Smith and Elliot, 2000). The extended version of the flap is of particular use in the treatment of extensive volar-sloping defects of the tips of the digits for which the shorter bipedicle flaps are not appropriate. The latter paper analyses the results of 100 such fingertips reconstructed with the extended flap. Foucher and his colleagues analysed a similar number of flaps of this kind but raised without the V-Y tail, with skin graft reconstruction of the proximal donor defect, with similar results (Schiund et al., 1985; Foucher and al., 1989).

The extended version of the Segmüller flap involves the use of a larger triangular flap, also raised as an island on the neurovascular pedicle, but with the apex of the flap at the PIP crease. The base of the flap is the proximal margin of the tip defect and the lateral boundary is the mid-lateral line of the finger. The third side of the flap is marked to join the flap apex (proximally) to the base of the flap in the mid-line of the finger. The flap extends only to the midline of the finger and differs in this respect from a Venkataswami flap ((Venkataswami and Subramanian, 2000), which is taken right across the volar aspect of the finger to the other mid-lateral line and, at least theoretically, has no innervation distally on the side opposite the neurovascular bundle on which it is raised.

Because of the volar sloping nature of the tip injuries for which these flaps are commonly used, the proximal edge of the tip defect often includes several millimetres of subcutaneous tissue without skin. This is included in the flap to increase its length and reduce the distance by which it must be advanced to the end of the digit, with the consequence that the bone at the tip of the finger may only be covered by denuded pulp tissue after flap advancement and not by pulp and skin. When this is the case, the tip is treated with moist antiseptic dressings for several weeks until re-epithelialisation completes tip cover.

The flap is raised from distal to proximal, starting from the lateral corner of the base of the flap. The skin incision begins down the mid-lateral line and dissection is continued medially and proximally in the plane immediately superficial to the periosteum laterally and the tendon sheath more medially. Using this approach, the digital artery on the dorsal surface of the neurovascular bundle is immediately identified from its deep surface on the underside of the flap and, thereafter, protected. All of the fibrous septa which connect the dermis to the periosteum and tendon sheath and the vessels feeding the vinculae of the flexor tendons at both interphalangeal joints are divided. The sloping medial side of the flap is incised through skin and those fibres immediately deep to the dermis are also divided to mobilise the flap. The most difficult part of the dissection is at its apex, at the PIP joint level, as the neurovascular bundle is directly deep to the meeting point of the lateral and medial incisions, and tethered by the branch of the artery running medially to feed the vincula of the flexor tendons, with little room for scalpel error without damaging the pedicle of the flap. It is safer to extend the lateral midline incision proximally down the proximal phalangeal segment of the finger, find the neurovascular bundle proximal to the apex of the flap, then follow the bundle distally to the apex of the flap at the PIP joint crease. It is necessary to completely island the flap on the neurovascular pedicle with a cuff of fat around the palmar surface of the artery and nerve to maintain venous drainage. When the neurovascular bundle is divided from its medial feeding branch to the vincula of the flexor tendons, the flap will be felt to 'jump' up to a centimetre distally. The flap is then advanced without tension and loosely sutured to cover the bone of the digit tip. Commonly, part of the mid-lateral margin of the flap is left unsutured to avoid tension from post-operative oedema. This wound subsequently heals by secondary epithelialisation under moist antiseptic dressings.

A single flap is usually raised on the blind side of the finger, unless the particular shape of the tip defect determines otherwise. In some injuries, a single flap provides sufficient tissue to reconstruct the digital tip but, in others, two flaps are necessary and a second flap is raised on the other neurovascular bundle and advanced (Fig 3). The finger is splinted dorsally with the PIP joint slightly flexed for the first 72 hours to take tension off the pedicle. However, this position is not maintained beyond this length of time as there is a risk of volar plate contracture of the PIP joint following use of all of the longer advancement flaps. After 72 hours, specific measures are taken by the therapists to avoid this, extension exercises and/or splinting sometimes being necessary for several weeks or, occasionally, months.

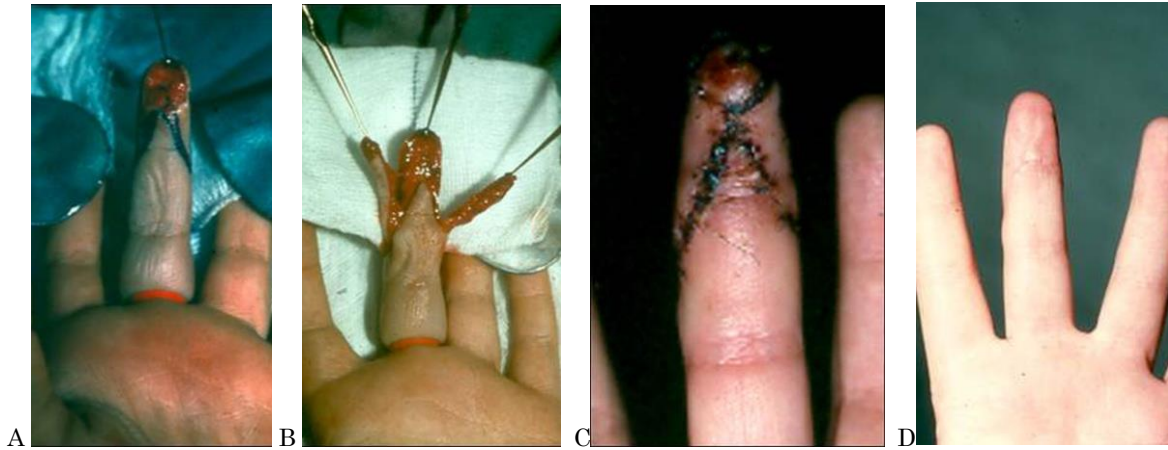

Figure 3: (A) Volar oblique amputation of the index finger. (B,C) Coverage with a double Segmüller flap. (D) Final result at 3 months

Commendable features of the extended Segmüller flap are its versatility, ease of use and reliability. It is a single stage reconstruction which borrows from no other part than the already injured recipient digit. While requiring careful technique, it requires no microsurgical expertise and is well within the capabilities of most hand surgeons. It can be used to treat digital tip defects of variable size, shape and slope. The flap is suitable for any transverse or oblique loss of the distal segment, however steeply sloping the latter, with the length of the flap being tailored to the size of the tissue loss. Where one flap provides insufficient tissue bulk at the tip after advancement, a second can be brought into use. Like all homodigital flaps, this flap is useful in multidigital injuries in which adjacent digits are not available as a source of flaps. It can also be moved dorsally to reconstruct nailbed loss or, in combination with other flaps, for more complex reconstruction of combined tip and dorsal injuries.

Thomas Giesen, Maurizio Calcagni, Switzerland

The role of perforator flaps and free flaps for the reconstruction of fingertips.

Recent publications have widened the choice of flaps in fingertip reconstruction, raising the technical difficulty of surgical reconstruction with the aim of lowering the local morbidity related to local flaps and at the same time to improve the quality of reconstruction.

Koshima et al., recently published the use of perforator flaps to reconstruct the tip of the finger (Koshima et al., 2006, Mitsunaga et al., 2010). These flaps are based on the small perforator arteries rising from the digital artery at the middle phalanx level, allowing the coverage of the fingertip without the need to sacrifice a digital artery as in homodigital reverse flaps. In our practice these flaps have not so far found any practical application, as for the classic local flaps, the Venkataswami flap or the Segmüller flap, which offer, with a simpler technique, an equivalent skin quality that is, in contrast, immediately sensate. In our opinion there is no relevant difference in the donor site and the latter flaps are technically less demanding.

The use of free flaps for reconstruction of the fingertip has, in our practice, very limited indications. We normally return to these flaps in acute traumatic cases of volar oblique amputations if there is a major contraindication or the impossibility of using an adjacent digit. Our indication for free flaps is if there is the need to reconstruct pulp in a “cold” situation where the soft tissue cover of the fingertip is insufficient and the other digits are intact.

In those situations our first choice is a free venous flap harvested from the palmar aspect of the wrist, including skin from the thenar eminence or hypothenar eminence and the terminal branches of the lateral or medial cutaneous nerve of the forearm.

We take two parallel veins from the proximal margin of the flap, using one of them as an afferent vessel anastomosed to a digital artery and one of them as a draining vein anastomosed preferentially to a volar vein of the digit, if available (Fig 4).

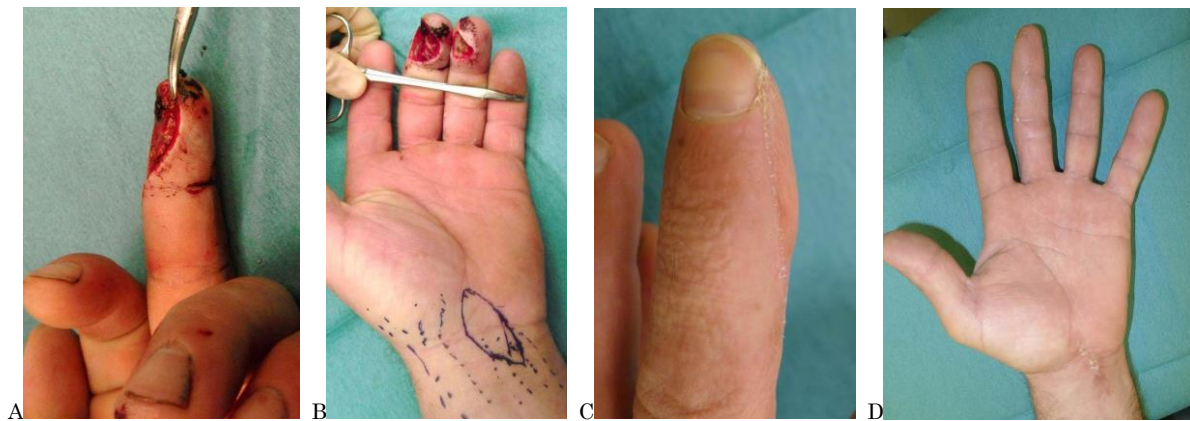

Figure 4: (A) Burr Injury to the radial side of a dominant middle finger. (B) Cover with a retrograde free venous flap from the volar aspect of the wrist including some glabrous skin from the hypothenar eminence. (C,D) Result at 3 months with donor site

The skin of these flaps is similar to the skin of the pulp and the harvesting of these flaps is technically easy.

We have very limited experience of the use of free thenar flaps and their modifications (Yang et al., 2010) based on the palmar branch of the radial artery and including terminal branches of the cutaneous nerves of the distal forearm and of the proximal hand. The reliability of these flaps was questionable and the harvesting more demanding; therefore we abandoned this technique.

In cases of small defects to the pulp we prefer the hemipulp free flap from the second toe (Kimura and Saito, 2006). In cases of composite defects including bone we prefer composite flaps from the great toe.

LARGE DEFECTS TO THE DIGITS

Roberto Adani, Italy

Refinements of the heterodigital island flap

The heterodigital flap comes from the standard cross-finger flap (Gourdin and Pangman, 1950), which is considered a random pattern regional flap employing the dorsal skin of an adjacent finger to provide soft tissue coverage to resurface a volar finger defect including pulp loss. To achieve recovery of sensitivity, the dorsal digital nerves (one or both) are included and sutured to the digital nerves of the injured finger (Lassner et al., 2002; Shao et al., 2009). There are two main disadvantages related to this technique: it is a two-stage procedure, and it requires finger immobilisation for up to three weeks. The heterodigital arterialized flap represents an evolution of the above methods: it is transferred from the lateral surface of a nearby digit including only the digital artery without the digital nerve. To reduce donor site morbidity the flap is harvested from the lateral side of the middle phalanx with the vascular pedicle located on the palmar side of the flap (Hirase et al., 1992; Leupin et al., 1997). The cosmetic result of the grafted donor area is more acceptable because the defect is over the midlateral line without affecting the palmar aspect of the finger. Moreover the dorsal branch of the digital nerve raising from the main nerve at this level can be used to innervate the flap with acceptable sensory recovery (Adani et al., 2010).

With large skin digital pulp defects of the middle finger it is not always easy to resurface the pulp without extending the distal incision of the flap over the DIP joint crease on the donor finger. This may damage the function and the cosmetic appearance of the donor finger pulp. The heterodigital island flap with reverse-flow vascularisation (Adani et al., 1999; Adani et al., 2005) may answer such a problem. With this flap the pedicle is isolated up to its bifurcation in the palm and the common digital artery between the injured finger and the flap-donor finger is ligated just before its bifurcation. The Y-like vascular bifurcation then turns into a V shape and the two converging branches of the digital arteries become a single vascular pedicle for the flap, increasing its original length. The vascularization is supplied by a reversed flow through the proximal transverse digital palmar arch of the injured finger allowing the flap to cover the defect completely. The heterodigital flap achieves acceptable sensory recovery: the mean static two-point discrimination test (s2PD) over the reconstructed pulp is about 9mm and the mean dynamic two-point discrimination test (m2PD) 7mm (Adani et al., 1999; Adani et al., 2005). These results are very similar to those reported by other authors (Hirase et al., 1992; Leupin et al., 1997) using the same donor area. No sensory deficit was reported in the donor fingers with the direct and the reverse heterodigital pedicle flaps.

The heterodigital neurovascular island flap is indicated for large losses of finger pulp when a direct island flap could be too small to cover the defect and represents a suitable option instead of the reverse homodigital island flap or free flaps (Fig 5). The reverse-flow type may be employed for large loss of pulp to the index and middle finger. This

procedure is not recommended in cases of severe crushing injury involving multiple finger pulp losses because of the possible damage to the vascular network including the proximal or middle transverse digital palmar arches.

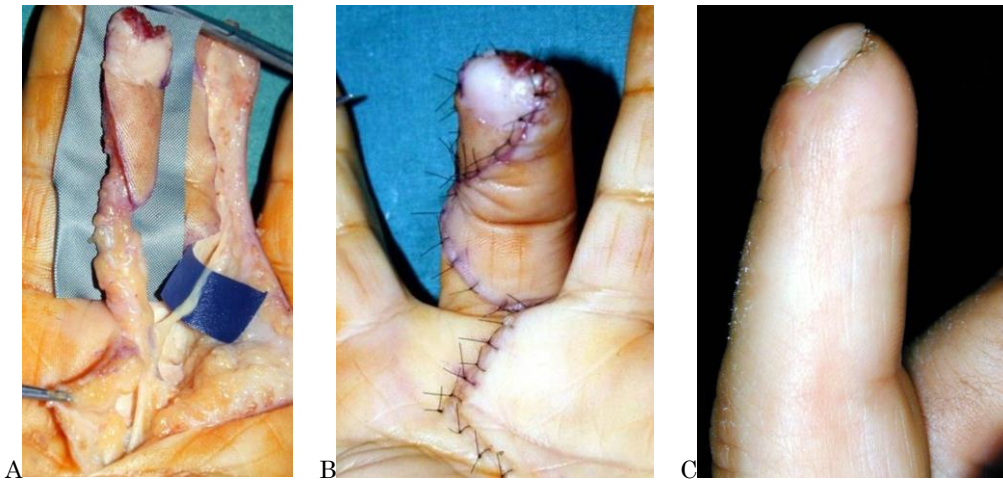


Figure 5: (A) Heterodigital Flap based on the radial digital artery of the ring finger. (B) Coverage of a two segment defect to the middle finger and (C) final result.

Thomas Giesen and Maurizio Calcagni, Italy

Retrograde arterialized free venous flaps

Although the literature is encouraging with regard to the survival rate of arterialized free venous flaps, previously reported difficulty in healing owing to early venous congestion and subsequent epidermolysis has prevented their widespread application.

Recent papers from Lin et al and from the authors of this section (Lin et al., 2010; Giesen et al., 2014) have demonstrated that if a shunt situation between the arterial and venous system created by the flap is avoided by the means of a valve (retrograde arterial flow against the valves) or a ligature, these flaps are more predictable and might become a first line choice in hand reconstruction.

In two segment defects of the digits, the choice of local flaps might be limited to the Quaba flap with the modification illustrated by Vuppalapati (Vuppalapati et al., 2004), large heterodigital flaps or distant flaps from the forearm and the groin. These options might not fit a complex traumatic situation or a specific anatomic area such as the ulnar side of the little finger, and might leave long scars to the forearm or force the patient into a cumbersome immobilized position.

Free venous flaps offer different advantages in terms of a pliable and thin skin that fits easily around the contours of the hand. They are easy to harvest and because they are usually taken from the same forearm under tourniquet, the harvesting time takes, in our experience, around 30 minutes. The donor site morbidity is reduced when compared to forearm island flaps as the scar is only as big as the dimension of the flap without the need to expose or sacrifice any arterial vessel. They can be harvested as composite flaps

including nerves and tendons for more complex reconstruction and, as reported in the fingertip section, they can include glabrous skin from the thenar or hypothenar eminence.

In our department we use the retrograde technique for arterialized free venous flaps, with the arterial flow running against the valves. With this choice the feeding vessel and the draining vessel are left on the same side of the flap, facilitating anastomoses.

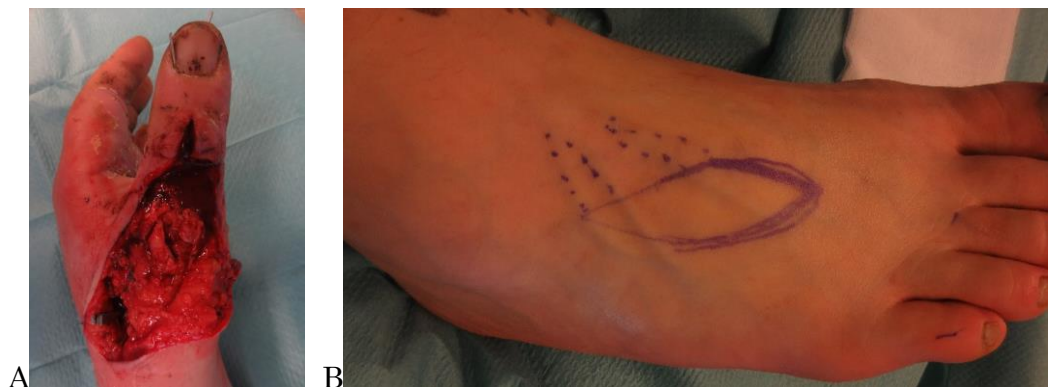The position of the flap that is going to be harvested on the forearm is influenced mainly by the criteria of calibre matching the recipient artery and veins: for large defects of the digits we normally use the common digital artery of the fingers or the dorsal branch of the radial artery after its division into two branches between the dorsal aspect of the base of the 1st and 2nd metacarpal bones. To match this calibre the flap is harvested from the middle third of the forearm.

The position of the flap might also be influenced by the need to harvest a composite flap with tendons, usually the palmaris longus or the flexor carpi radialis, and nerves, usually the lateral cutaneous nerve of the forearm. The presence of hair is one more factor influencing the harvesting site.

The flap is harvested by incising the skin on the outside of the line obtained with the defect template in order to obtain a slightly larger flap than required. This technical step is due to the postoperative swelling we observed occurring in the first 48 hours, as already pointed out by Woo et al in 2007.

We usually wash the vein that is going to be arterialized with heparin-saline solution prior to anastomosis in order to exclude the presence of a valve in the pedicle before it enters the flap. For the same reason we normally take the cuff of fat tissue from around the vessels. After the arterial anastomosis, if a shunt situation is observed and the chosen draining vein is pulsating, we now look for the communicating branch between the feeding and the draining vessel and ligate it with a clip, as described by Lin (Lin et al., 2010).

In the literature, several papers have been published recently with refinements in this technique and the use of different donor sites like the dorsum of the foot (Fig 6) (Yu et al., 2012), introducing the idea of the possibility for these flaps to become routine procedures in hand reconstruction



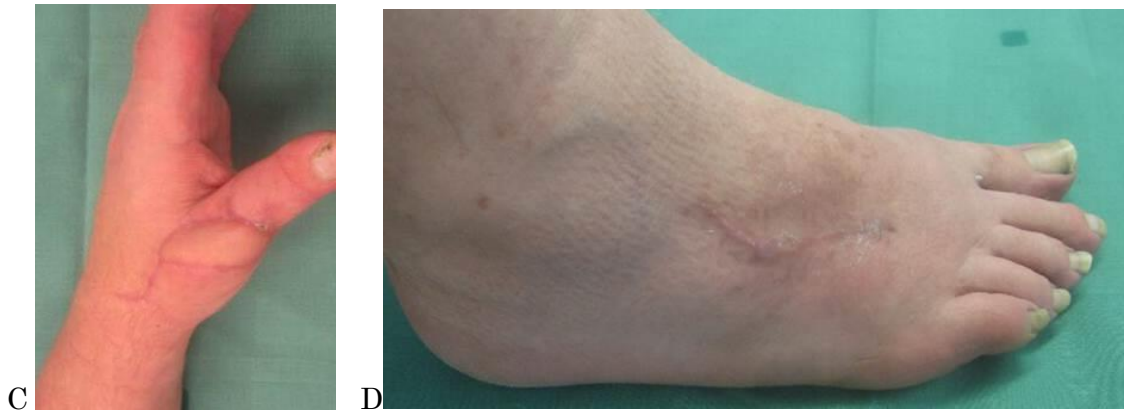


Figure 6: (A) two segment defect to the P1 and distal metacarpal of the dorsum of a replanted thumb. (B) Plan of a retrograde free venous flap from the dorsum of the foot in a obese patient. (C) Result at three months and (D) donor site at three months.

LARGE DEFECTS OF THE HAND

Roberto Adani, Italy

The role of the ALT in the coverage of large defects in the hand, the palm and the dorsum

Fasciocutaneous flaps are most frequently used to cover hand defects (Saint-Cyr and Gupta, 2007). Many factors should be considered when choosing a flap. The most significant are the cosmetic match of the skin surrounding the defect, the donor site morbidity and the simultaneous approach to wound debridement and flap harvesting (Scheker and Ahmed, 2007). In the last decade the anterolateral thigh flap has received considerable interest (Javaid and Cormack, 2003; Adani et al., 2005; Adani et al., 2006) from hand surgeons and represents a good alternative to other fasciocutaneous flaps. The anterolateral thigh flap shows several advantages: simultaneous flap elevation and preparation; shorter operative time; longer vascular pedicle (approximately 10cm long); larger skin paddle. Despite its versatility, the anterolateral thigh flap has some potential drawbacks: the greatest concern has been variability of the perforators and flap reliability (Wang et al., 2005). Large clinical series show that almost all patients will have an adequate vessel for supplying the flap and Doppler examination can accurately identify the perforators preoperatively, planning the flap accurately. The flap should be thinned to approximately 3mm to 4mm by removing a considerable amount of fatty tissue before it is transferred onto the hand. This allows an optimal match between the donor tissue and the area to be reconstructed with the flap. Despite flap thinning, additional debulking could still be necessary to improve the final cosmetic result, particularly in Caucasian patients whose thigh characteristics differ from patients of Asian origin. Defects of the donor site smaller than 7cm - 8cm in width can be closed primarily without a skin graft. In this case the scar is less noticeable than with other flaps harvested from the arm or forearm. The donor site scars associated with skin grafts of larger defects may preclude its use, particularly in female patients. The ALT

flap is recommended in very large defects of the dorsum of the hand and the wrist; if employed for palm reconstruction, it requires aggressive thinning and a secondary debulking to reach an acceptable appearance.

The current role of the forearm flap for reconstruction of the palm and dorsal hand

The radial forearm flap may be used to cover the dorsal aspect of the hand. The sacrifice of a major artery in an already traumatized hand and the donor site result, which is not always satisfactory, represent the major drawbacks of this surgical procedure. However if this flap can resurface medium-sized defects with direct closure of the donor site and without jeopardizing the vascularisation of the hand, this approach may still be useful in the armamentarium of hand surgeons. In our practice the radial forearm flap is mainly used with direct closure of the donor site avoiding the need for skin graft. These problems can be partially solved by the radial artery perforator flap used as either a fasciocutaneous flap or an adipofascial flap (Page and Chang, 2006; Ho and Chang, 2010; Saint-Cyr et al., 2010.) The retrograde radial fascia-fat forearm flap removes only the fascia and fat layers of the forearm tissue leaving the radial artery and the forearm skin intact. The perforator flaps show some disadvantages: the pedicle is relatively bulky after rotation, which makes direct closure dangerous, and their pivot point is located more proximally than in the traditional radial forearm flap making it difficult to extend and cover the distal dorsal aspect of the hand completely. For these reasons they can be used only to treat moderate-sized defects and they should be considered very carefully in patients with complex hand injuries to the forearm with possible damage to the perforators of the radial artery. Another possibility is to divide the radial forearm flap into different sections, following the perforators, by using a long narrow flap which allows primary closure of the donor site (Mateev et al., 2009). The use of the radial forearm flap with large skin defects (more than 20cm²) is more restricted because of the poor donor site result. Attempts to minimize the donor site morbidity have been widely reported in literature using different types of skin grafts (Zuidam et al., 2005; Ito et al., 2005.), regional advancement flaps (Ahn et al., 2007; Lane et al., 2013) or special types of skin substitutes (Rowe et al., 2006; Murray et al., 2011). The radial forearm flap finds a specific indication for use for the thenar region because it provides thin and pliable skin; on the contrary, it is not ideal for the hypothenar and central region of the palm, where stability cannot be achieved with this type of flap.

REFERENCES

- Adani R, Busa R, Scagni R, Mingione A. The heterodigital reversed flow neurovascular island flap for fingertip injuries. *J Hand Surg.* 1999, 24B: 431-6.
- Adani R, Giesen T, Inguaggiato M. Heterodigital flaps for severe pulp defects. In TP Dubert Ed. *Primary Care of Complex Injuries of the Hand and Wrist.* Kostantaras Medical Publications Athens, 2010, 317-22.
- Adani R, Marcoccio I, Tarallo L, Fregni U. First web space reconstruction by the anterolateral thigh flap. *J Hand Surg Am.* 2006, 31A: 640-6.
- Adani R, Marcoccio I, Tarallo L, Fregni U. The reverse heterodigital neurovascular island flap for digital pulp reconstruction. *Tech Hand Up Extrem Surg.* 2005, 9: 91-5.
- Adani R, Tarallo L, Marcoccio I, Cipriani R, Gelati C, Innocenti M. Hand reconstruction using the thin anterolateral thigh flap. *Plast Reconstr Surg.* 2005, 116: 467-73.
- Ahn HC, Choi MS, Hwang WJ, Sung KY. The transverse radial artery forearm flap. *Plast Reconstr Surg.* 2007, 119: 2153-60.
- Allen MJ. Conservative management of finger tip injuries. *The Hand.* 1980, 12: 257-65.
- Ardouin T, Poirier P, Rogez JM. Fingertips and nailbed injuries in children. Apropos of 241 cases. *Rev Chir Orthop Reparatrice Appar Mot.* 1997, 83: 330-4.
- Atasoy E, Ioakimidis E, Kasdan ML, Kutz JE, Kleinert HE. Reconstruction of the amputated finger tip with a triangular volar flap. *J Bone Joint Surg Am.* 1970, 52: 921-6.
- Bakhach J. Eponychial flap. *Ann Chir Plast Esthet.* 1998, 43: 259-63.
- Bickel KD, Dosanjh A. Fingertip Reconstruction. *J Hand Surg Am.* 2008, 33: 1417-9.
- Biddulph SL. The neurovascular flap in finger tip injuries. *The Hand.* 1979, 1: 59-63.
- Buckley SC, Scott S, Das K. Late review of the use of silver sulphadiazine dressings for the treatment of fingertip injuries. *Injury.* 2000, Jun 31: 301-4.
- Chow SP, Ho E. Open treatment of fingertip injuries in adults. *J Hand Surg Am.* 1982, 7: 470-6.
- Dumontier C, Tilquin B, Lenoble E, Foucher G. Reconstruction of distal loss of substance in the nail-bed by a de-epithelialized flap from the digital pulp. *Ann Chir Plast Esthet.* 1992, 37:553-9.
- de Boer P, Collinson PO. The use of silver sulphadiazine occlusive dressings for fingertip injuries. *J Bone Joint Surg Br.* 1981, 63: 545-7.

Duthie G, Adams J. Meshed adhesive tape for the treatment of crushed fingers in children. *J Hand Surg Br*, 1984, 9: 41.

Elliot D, Moiemmen NS, Jigjinni VS. The neurovascular Tranquilli-Leali flap. *J Hand Surg Br*. 1995, 20: 815-23.

Elliot D, Wilson Y. V-Y advancement of the entire volar soft tissue of the thumb in distal reconstruction. *J Hand Surg Br*, 1993, 18: 399-402.

Farrell RG, Disher WA, Nesland RS, Palmatier TH, Truhler TD. Conservative management of fingertip amputations. *JACEP*. 1977, 6: 243-6.

Foucher G, Smith D, Pempinello C, Braun FM, Citron N. Homodigital neurovascular island flaps for digital pulp loss. *J Hand Surg Br*, 1989, 14: 204-8.

Fox JW 4th, Golden GT, Rodeheaver G, Edgerton MT, Edlich RF. Non-operative management of fingertip pulp amputation by occlusive dressings. *Am J Surg*. 1977, 133: 255-6.

Gaul JS. A palmar-hinged flap for reconstruction of traumatic thumb defects. *J Hand Surg Am*. 1987, 12: 415-421.

Geissendörfer H. Beitrag zur Fingerkuppenplastik. *Zentralbl Chir*. 1943, 70: 1107-8.

Giesen T, Forster N, Künzi W, Giovanoli P, Calcagni M. Retrograde arterialized free venous flaps for the reconstruction of the hand: review of 14 cases. *J Hand Surg Am*. 2014, 39: 511-23.

Gourdin M, Pangman WJ. The repair of surface defects of fingers by trans-digital flaps. *Plast Reconstr Surg*. 1950, 5: 368-71.

Guy RJ. The etiologies and mechanisms of nail bed injuries. *Hand Clin*. 1990, 6: 9-19.

Henry M. Specific complications associated with different types of intrinsic pedicle flaps of the hand. *J Reconstr Microsurg*. 2008, 24:221-5.

Hirase Y, Kojima T, Matsuura U. A versatile one-stage neurovascular flap for fingertip reconstruction: the dorsal middle phalangeal finger flap. *Plast Reconstr Surg*. 1992, 90: 1009-15.

Ho A, Chang J. Radial artery perforator flap. *J Hand Surg Am*. 2010, 35: 308-11.

Inglefield CJ, D'Arcangelo M, Kolhe PS. Injuries to the nail bed in childhood. *J Hand Surg Br*, 1995, 20: 258-61.

Ipsen T, Frandsen PA, Barfred T. Conservative treatment of fingertip injuries. *Injury*. 1987, 18: 203-5.

- Ito O, Igawa HH, Suzuki S, Muneuchi G, Kawazoe T, Saso Y et al. Evaluation of the donor site in patients who underwent reconstruction with a free radial forearm flap. *J Reconstr Microsurg*. 2005, 21: 113-7.
- Javaid M, Cormack G. Anterolateral thigh free flap for complex soft-tissue hand reconstruction. *J Hand Surg Br*. 2003, 28:21-7
- Kimura N, Saitoh M. Recovery of disused replanted digits by second toe hemipulp flap transfer. *Plast Reconstr Surg*. 2006, 117: 507-13.
- Kojima T Kinoshita Y Hirase Y Endo T, Hayashi H. Extended palmar advancement flap with V-Y closure for finger injuries. *British Journal of Plastic Surgery*. 1994, 47: 275-9.
- Koshima I, Urushibara K, Fukuda N, Ohkochi M, Nagase T, Gonda K, Asato H, Yoshimura K. Digital artery perforator flaps for fingertip reconstructions. *Plast Reconstr Surg*. 2006, 118: 1579-84
- Kutler W. A new method for finger tip amputation. *JAMA*. 1947, 133: 29-30.
- Lamon RP, Cicero JJ, Frascone RJ, Hass WF. Open treatment of fingertip amputations. *Ann Emerg Med*. 1983, 12: 358-60.
- Lane JC, Swan MC, Cassel OC. Closure of the radial forearm donor site using a local hatchet flap: analysis of 45 consecutive cases. *Ann Plast Surg*. 2013, 70: 308-12.
- Lanzetta M, Mastropasqua B, Chollet A, Brisebois N. Versatility of the homodigital triangular neurovascular island flap. *J Hand Surg Br*. 1995, 20: 824-9.
- Lassner F, Becker M, Berger A, Pallua N. Sensory reconstruction of the fingertip using the bilaterally innervated sensory cross-finger flap. *Plast Reconstr Surg*. 2002, 109: 988-93.
- Lee LP, Lau PY, Chan CW. A simple and efficient treatment for fingertip injuries. *J Hand Surg Br*. 1995, 20: 63-71.
- Leupin P, Weil J, Buchler U. The dorsal middle phalangeal finger flap. *J Hand Surg Br*. 1997, 22: 362-71.
- Lemperle G, Schwarz M, Lemperle SM. Nail regeneration by elongation of the partially destroyed nail bed. *Plast Reconstr Surg*. 2003, 111: 167-72.
- Lin YT, Henry SL, Lin CH, Lee HY, Lin WN, Lin CH, Wei FC. The shunt-restricted arterialized venous flap for hand/digit reconstruction: enhanced perfusion, decreased congestion, and improved reliability. *J Trauma*. 2010, 69: 399-404.

Ma GFY, Cheng JCY, Chan KT, Chan KM, Leung PC. Fingertip injuries--a prospective study on seven methods of treatment on 200 cases. *Ann Acad Med Singapore*. 1982, 11: 207-13.

Mateev M, Ogawa R, Trunov L, Moldobaeva N, Hyakusoku H. Shape-modified radial artery perforator flap method. Analysis of 112 cases. *Plast Reconstr Surg*. 2009, 123: 1533-43.

Mennen U, Wiese A. Fingertip injuries management with semi-occlusive dressing. *J Hand Surg Br*, 1993, 18: 416-22.

Merlino G, Carlucci S. A simple modification of the Bakhach's eponychial flap for nail lengthening after fingertip amputation. *J Plast Reconstr Aesthet Surg*. 2011, 64: e265-6.

Mignemi ME, Unruh KP, Lee DH. Controversies in the treatment of nail bed injuries. *J Hand Surg Am* 2013, 38: 1427-30.

Miranda BH, Vokshi I, Milroy CJ. Pediatric nailbed repair study: nail replacement increases morbidity. *Plast Reconstr Surg*. 2012, 129: 394e-6e. (Erratum in *Plast Reconstr Surg*. 2012, 129: 1028)

Mitsunaga N, Mihara M, Koshima I, Gonda K, Takuya I, Kato H, Araki J, Yamamoto Y, Yuhei O, Todokoro T, Ishikawa S, Eri U, Mundinger GS. Digital artery perforator (DAP) flaps: modifications for fingertip and finger stump reconstruction. *J Plast Reconstr Aesthet Surg*. 2010, 63: 1312-7.

Moberg E. Aspects of sensation in reconstructive surgery of the upper extremity. *J Bone Joint Surg Am*. 1964, 46: 817-25.

Mouchet A, Gilbert A. Covering distal amputations of the finger using homodigital neurovascular island flaps. *Ann Chir Main*. 1982 1: 180-182.

Mühldorfer-Fodor M, Hohendorff B, Vorderwinkler KP, van Schoonhoven J, Prommersberger KJ. Treatment of fingertip defect injuries with a semiocclusive dressing according to Mennen and Wiese. *Oper Orthop Traumatol*. 2013, 25: 104-14.

Muneuchi G, Tamai M, Igawa K, Kurokawa M, Igawa HH. The PNB classification for treatment of fingertip injuries: the boundary between conservative treatment and surgical treatment. *Ann Plast Surg*. 2005, 54: 604-9.

Murray RC, Gordin EA, Saigal K, Leventhal D, Krein H, Heffelfinger RN. Reconstruction of the radial forearm free flap donor site using Integra artificial dermis. *Microsurgery*. 2011, 31: 104-8.

O'Brien, B. Neurovascular island pedicle flaps for terminal amputations and digital scars. *Br J Plast Surg*. 1968, 21: 258-61

Ogo K. Does the nail bed really regenerate? *Plast Reconstr Surg*. 1987, 80: 445-7.

Ogunro EO. External fixation of injured nail bed with the INRO surgical splint. *J Hand Surg Am.* 1989, 14: 236–41.

Ogunro O, Ogunro S. Avulsion injuries of the nail bed do not need nail bed graft. *Tech Upper Extrem Surg.* 2007, 11: 135–8.

O'Shaughnessy M, McCann J, O'Connor TP, Condon KC. Nail re-growth in fingertip injuries. *Ir Med J.* 1990, 83: 136-7.

Page R, Chang J. Reconstruction of the hand-soft tissue defects: alternatives to the radial forearm perforator flap: vascular analysis and clinical implications. *Plast Reconstr Surg.* 2010, 125: 1469-78.

Riyat MS, O'Dwyer G, Quinton DN. Comparison of silver sulphadiazine and paraffin gauze dressings in the treatment of fingertip amputations. *J Hand Surg Br.* 1997, 22: 530-2.

Rowe N, Morris L, Delacure M. Acellular dermal composite allografts for reconstruction of the radial forearm donor site. *Ann Plast Surg.* 2006, 57: 305-11.

Saint-Cyr M, Gupta A. Indications and selection of free flaps for soft tissue coverage of the upper extremity. *Hand Clin.* 2007, 23: 37-48.

Saint-Cyr M, Mujadzic M, Wong C, Hatef D, Lajoie A, Rohrich RJ. The radial artery pedicle perforator flap: vascular analysis and clinical implications. *Plast Reconstr Surg.* 2010, 125: 1469-78.

Scheker L, Ahmed O. Radical debridement, free flap coverage, and immediate reconstruction of the upper extremity. *Hand Clin.* 2007, 23: 23-36.

Schernberg F, Ameil M. Local rotational flap of the nail. *Handchir Mikrochir Plast Chir.* 1987, 19: 259-62.

Schuind F, Van Genechten F, Denuit P, Merle M, Foucher G. Homodigital neurovascular island flaps in hand surgery. A study of sixty cases. *Ann Chir Main.* 1985, 4: 306-15.

Schiund F, Van Genechten F, Denuit P, Merle M, Foucher G. Homodigital neurovascular island flaps in hand surgery. A study of sixty cases. *Ann Chir Main.* 1985, 4: 306-15.

Seaberg DC, Angelos WJ, Paris, PM. Treatment of subungual hematomas with nail trephination: a prospective study. *Am J Emerg Med.* 1991, 9: 209-10.

Segmüller G. Modification of the Kutler flap: neurovascular pedicle. *Handchirurgie.* 1976, 8: 75-6.

- Shao X, Chen C, Zhang X, Yu Y, Ren D, Lu L. Coverage of fingertip defect using a dorsal island pedicle flap including both dorsal digital nerves. *J Hand Surg.* 2009, 34:1474-81
- Shepard GH. The use of lateral V-Y advancement flaps for fingertip reconstruction. *J Hand Surg Am.* 1983, 8: 254-9.
- Shepard GH. Treatment of nail bed avulsions with split-thickness nail bed grafts. *J Hand Surg Am.* 1983, 8: 49-54.
- Shepard GH. Management of acute nail bed avulsions. *Hand Clin.* 1990, 6: 39-56
- Simon RR, Wolgin M. Subungual hematoma: association with occult laceration requiring repair. *Am J Emerg Med.* 1987, 5: 302-4.
- Smith KL and Elliot D. The extended Segmüller flap. *Plastic and Reconstructive Surgery.* 2000, 105: 1334–46.
- Snow JW. The use of a volar flap for repair of fingertip amputations: a preliminary report. *Plast Reconstr Surg.* 1967, 40: 163-8.
- Soderberg T, Nystrom A, Hallmans G, Hulten J. Treatment of fingertip amputations with bone exposure. A comparative study between surgical and conservative treatment methods. *Scand J Plast Reconstr Surg.* 1983, 17: 147–52.
- Sommer NZ, Brown RE. The perionychium. In: Wolfe SW, Hotchkiss RN, Pederson WC, Kozin SH (eds.) *Operative hand surgery.* 6th ed. Philadelphia: Elsevier, 2011, 333-53.
- Tos P, Artiaco S, Coppolino S, Conforti LG, Battiston B. A simple sterile polypropylene fingernail substitute. *Chir Main.* 2009, 28: 143–5.
- Tos P, Titolo P, Chirila N.L, Catalano F, Artiaco S. Surgical treatment of acute fingernail injuries. *J Orthopaed Traumatol.* 2012, 13: 57–62.
- Tranquilli-Leali, E. Ricostruzione dell'apice delle falangi ungueali mediante autoplastica volare pedunculata per scorrimento. *Infornistica e Traumatologia del Lavaro,* 1935, 1: 186-93.
- van den Berg WB1, Vergeer RA, van der Sluis CK, Ten Duis HJ, Werker PM. Comparison of three types of treatment modalities on the outcome of fingertip injuries. *J Trauma Acute Care Surg.* 2012, 72: 1681-7.
- Venkataswami R, Subramanian N. Oblique triangular flap: A new method of repair for oblique amputations of the fingertip and thumb. *Plast Reconstr Surg.* 2000, 66: 296-300.
- Vuppalapati G, Oberlin C, Balakrishnan G. "Distally based dorsal hand flaps": clinical experience, cadaveric studies and an update. *Br J Plast Surg.* 2004, 57: 653-67.

Wang HT, Fletcher JW, Levin SL. Use of the anterolateral thigh free flap for upper-extremity reconstruction. *J Hand Surg Am.* 2005, 30: 257-61.

Wang L, Yuan SY. A simple and direct procedure for excision of peripheral skin above the nail root to enable nail lengthening after fingertip amputation. *J Plast Reconstr Aesthet Surg.* 2012, 65: e265-6.

Williamson DM, Sherman KP, Shakespeare DT. The use of semipermeable dressings in fingertip injuries. *J Hand Surg Br.* 1987, 12: 125-6.

Woo SH, Kim KC, Lee GJ, Ha SH, Kim KH, Dhawan V, Lee KS. A retrospective analysis of 154 arterialized venous flaps for hand reconstruction: an 11-year experience. *Plast Reconstr Surg.* 2007, 119: 1823-38.

Yang JW, Kim JS, Lee DC, Ki SH, Roh SY, Abdullah S, Tien HY. The radial artery superficial palmar branch flap: a modified free thenar flap with constant innervation. *J Reconstr Microsurg.* 2010, 26: 529-38.

Yu G, Lei HY, Guo S, Huang JH, Yu H. Dorsalis pedis arterialized venous flap for hand and foot reconstruction. *Chin J Traumatol.* 2012, 15: 32-5.

Zook EG. The perionychium: anatomy, physiology, and care of injuries. *Clin Plast Surg.* 1981, 8: 21-31.

Zook EG, Guy RJ, Russell RC. A study of nail bed injuries: causes, treatment, and prognosis. *J Hand Surg Am.* 1984, 9: 247-52.

Zuidam JM, Coert JH, Hofer SO. Closure of the donor site of the free radial forearm flap: a comparison of full-thickness graft and split-thickness skin graft. *Ann Plast Surg.* 2005, 55: 612-6.