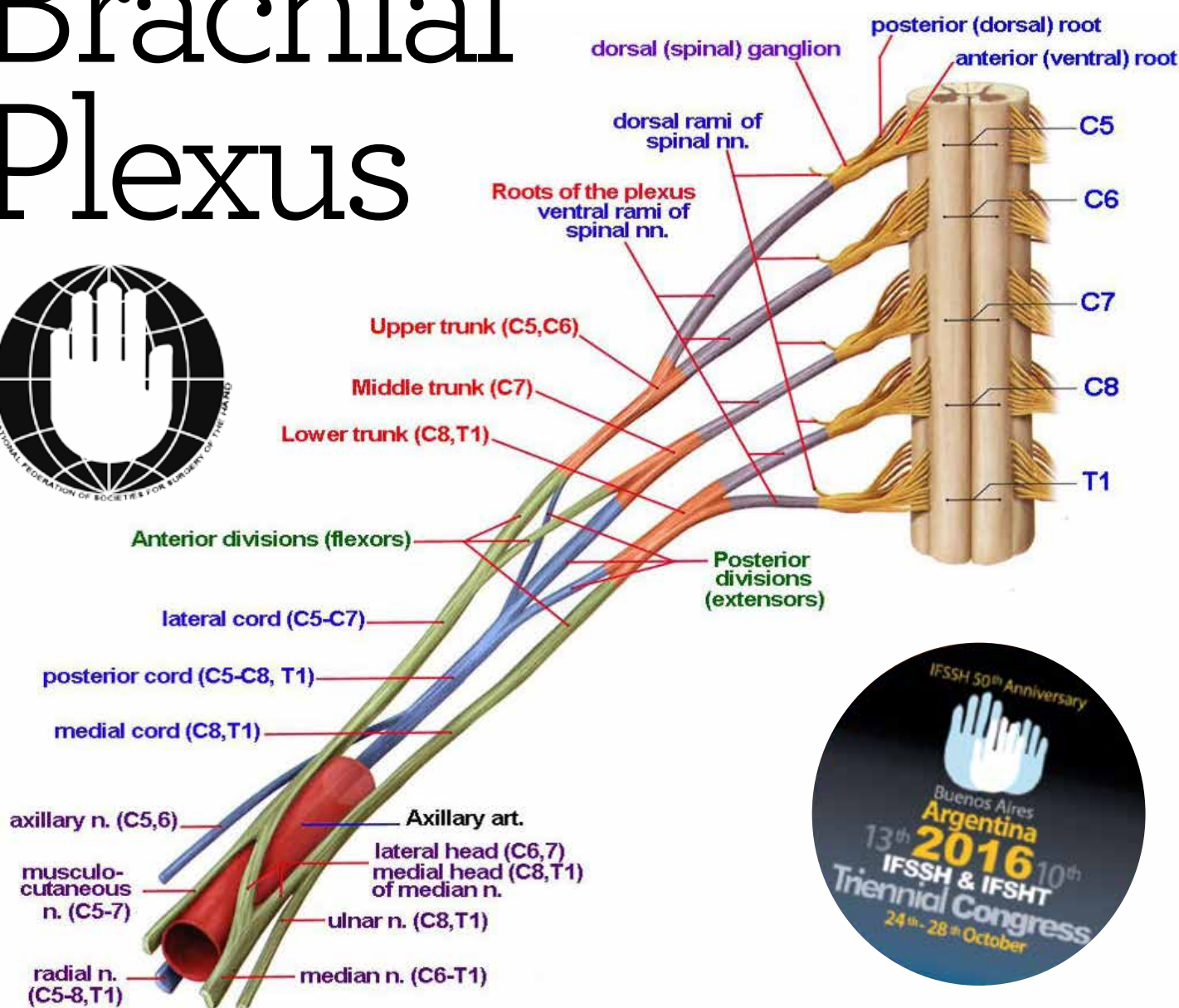


# ifssh ezine

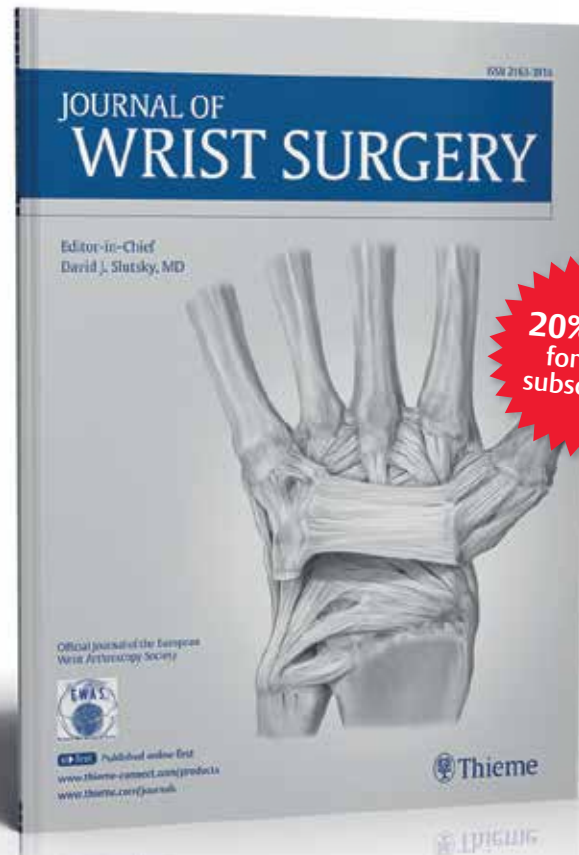
CONNECTING OUR GLOBAL HAND SURGERY FAMILY

SPECIAL FEATURE:  
CREATING A NEW  
SURGICAL SPECIALITY  
HAND THERAPY  
3D PRINTING FOR  
CUSTOMIZED WRIST SPLINTS

## Brachial Plexus



A quarterly peer-reviewed periodical covering all aspects of wrist surgery and small bone surgery of the hand



**20% OFF**  
for new  
subscribers

## Journal of Wrist Surgery

Editor-in-Chief: D. Slutsky

2016/Volume 5/4 issues p.a./ISSN 2163-3916

### USA and Canada

Individuals: \$197 \$158

Institutions: \$564

Contact customerservice@thieme.com

### Mexico, Central and South America

Individuals: \$215 \$172

Institutions: \$564

Contact customerservice@thieme.com

### Africa, Asia, Australia and Europe

Individuals: €154 €123

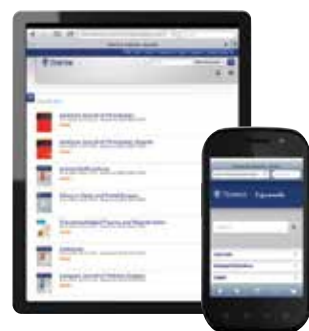Institutions: €427

Contact customerservice@thieme.de

(Please add shipping charges: €40.00)

### Bangladesh, Bhutan, India, Nepal, Pakistan and Sri Lanka

Contact customerservice@thieme.in for subscription rates in INR.



## SUBSCRIBE NOW AND STAY UP-TO-DATE IN 2016

Visit [www.thieme.com/journals](http://www.thieme.com/journals) in order to subscribe or renew your subscription.

Take full advantage of your individual subscription by registering online at [www.thieme-connect.com/products](http://www.thieme-connect.com/products):

- Individual subscribers get free online access to current and back issues of their journal(s)
- Advanced online access for select journals via the eFirst service
- Compatibility with smartphones and mobile devices
- Search across our entire library of journals via optimized faceted search

**ORDER TODAY** <http://www.thieme.com>

Special introductory rates are only valid for new subscribers and are limited to the first year of subscription. Only qualified professionals and students are eligible for individual subscriptions. Orders from individuals must include the recipient's name and private address, and be paid by private funds.



Become a fan at [www.facebook.com/thiemepublishers](http://www.facebook.com/thiemepublishers).



Follow us @ThiemeNY



## 4 EDITORIAL

IFSSH EZINE -

Submission Policy and Information

## 6 SECRETARY-GENERAL REPORT

2016 IFSSH Delegates Council Meeting

Marc Garcia-Elias – Secretary General

## 8 SPECIAL FEATURE

Creating a new surgical speciality  
in a state health care system

- Frank D Burke

## 12 PIONEER PROFILES

• Daniel C. Riordan

• Harold E Kleinert

## 14 LETTER TO THE EDITOR

• Daniel J. Nagle MD

## 16 COMMITTEE REPORT

IFSSH Scientific Committee

on Brachial Plexus Injury

## 31 HAND THERAPY

3D Printing for Customized Wrist Splints:  
past, present and future

## 36 MEMBER SOCIETY UPDATES

- The American Society for Surgery of the Hand (ASSH)
- American Association for Hand Surgery (AAHS)
- The South African Society for Surgery of the Hand
- British Society for Surgery of the Hand
- Netherlands Society of Surgery of the Hand
- Spanish Society for Hand Surgery (SECMA)
- Switzerland Society for Hand Surgery
- Venezuelan Society for Hand Surgery
- Singapore Society for Hand Surgery
- Portuguese Hand Surgery Society - SPOCMA

## 48 PEARLS OF WISDOM

David Warwick

## 50 JOURNAL HIGHLIGHTS

- Journal of Hand Surgery European Volume
- Journal of Hand Surgery (American)
- The Journal of Hand Surgery (Asian-Pacific)
- Journal of Hand Therapy
- Journal of Wrist Surgery

## 58 UPCOMING EVENTS

List of global learning events and conferences  
for Hand Surgeons and Therapists



# IFSSH EZINE - SUBMISSION POLICY AND INFORMATION

The IFSSHazine is the official mouthpiece of the International Federation of Societies for Surgery of the Hand (IFSSH), and is sent free of charge every three months (February, May, August, November) to many thousands of Hand Surgeons and Hand Therapists worldwide.

Any IFSSH Member Society may use the Ezine to announce their activities or share information regarding their Society. This is gratis and can be organised by contacting [administration@ifssh.info](mailto:administration@ifssh.info). The magazine's philosophy is "for the members by the members".

All announcements or advertisements which are not officially endorsed or sponsored by a Member Society may be placed in the Ezine as long as the advertisement relates to the Hand and aligns with the IFSSH Charter. The current fee is US\$ 300 per full size page per issue, or US\$ 1000.00 for 4 issues. All advertisements have to be of high definition, ready to be published as is, and will be placed without editing. The advertiser thus

takes full responsibility for the advertisement and the response that may flow from placing it in the Ezine. Furthermore, the IFSSH does not endorse nor take any responsibility for the content or claims made in such advertisements.

When submitting news and advertisements, please be aware of the following publishing schedule and specifications:

Specifications for full page adverts

- Dimensions: 190mm x 272mm (216mm x 303mm with bleed)
- Format required: High resolution pdf (all photos in artwork must be CMYK, 300 dpi)
- All hyperlinks with text/photos that need hyperlinking need to be specified when artwork is sent through

Deadline for submissions  
All submissions should reach us not later than the 10th of the month prior to publication ie 10 January, 10 April, 10 July and 10 October. Please note we do not send reminders.

Previous issues of the ezine are available on the IFSSH website: [www.ifssh.info](http://www.ifssh.info).

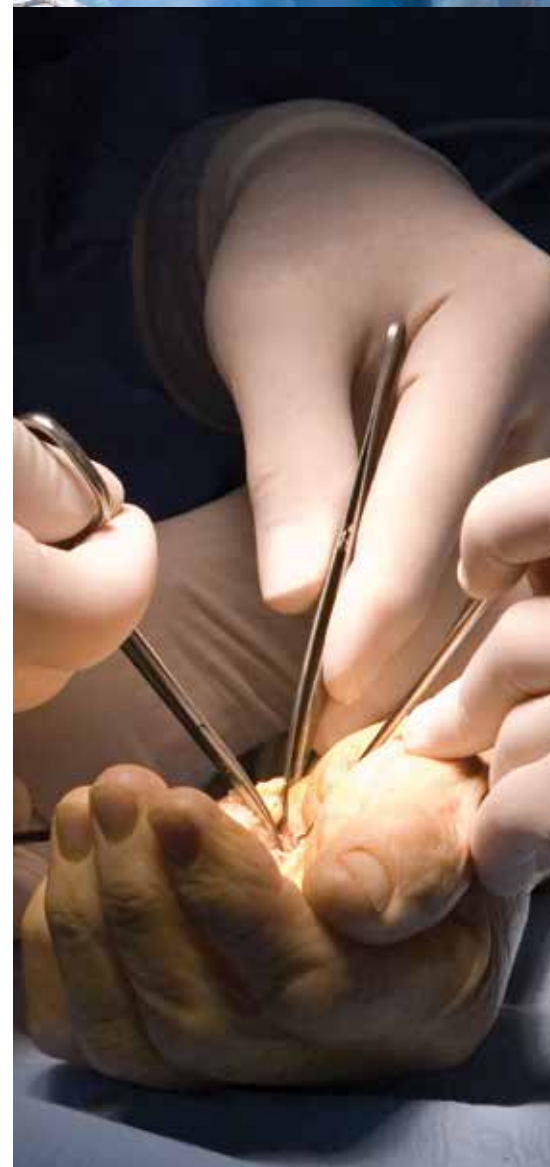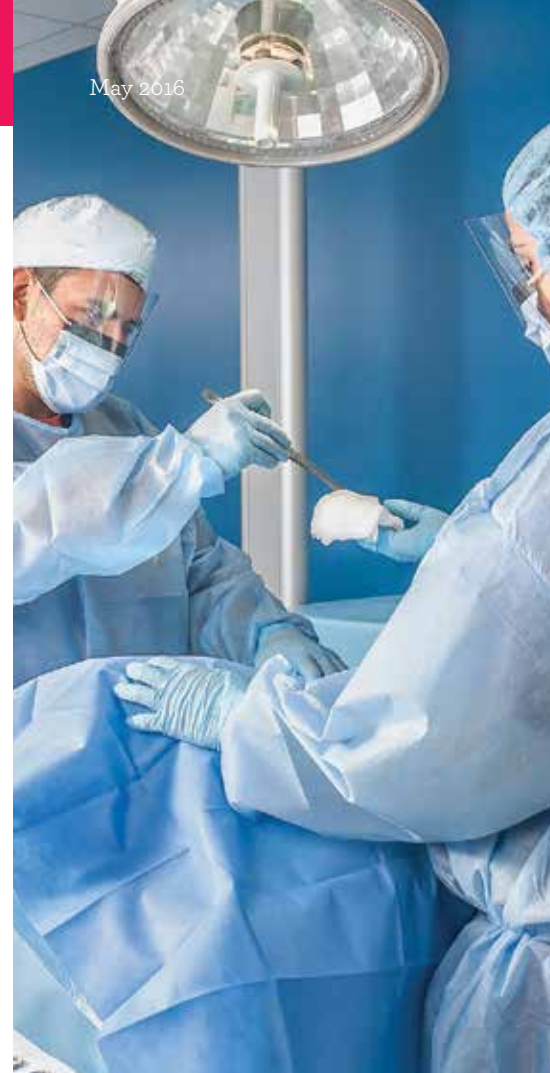Please contact [administration@ifssh.info](mailto:administration@ifssh.info) should you wish to make use of this offer.

We look forward to receiving your submissions.

**Prof Ulrich Mennen**  
Editor, IFSSH Ezine  
Past-President, IFSSH  
Email: [ezine@ifssh.info](mailto:ezine@ifssh.info)



May 2016



## Cadaveric Human Specimens for your Medical Research, Training or Educational Needs

When it comes to medical research, development and surgical training, experts agree that the use of human tissue is far safer and superior to textbooks, computer simulations or artificial substitutes. In the field of hand surgery, many advancements, including the world's first pediatric bilateral hand transplant, can be attributed to hours of research, training and practice using cadaver tissue.

### Where do hand surgeons and medical facilities find fresh tissue for research and training?

They work with organizations like Science Care, one of the world's largest non-transplant tissue banks with 5-accredited locations spread across the U.S. Science Care is capable of shipping custom procured tissue anywhere in the world. Science Care tissue has been used by numerous hand surgeons and training facilities across the globe, helping to impact successful surgical outcomes.

### Whatever your tissue needs are, Science Care can help. We offer:

- Safe, well documented source of human tissue specimens.
  - Tissue can be requested and supplied in multiple forms: whole bodies, extremities, internal organs, skin, FDA panels and more.
- Customized methods of tissue procurement, preparation and preservation are available to match your study and program goals.
- A complete medical and social history of the donor with each human tissue specimen.
- Specially packaged specimens with worldwide shipping.

### How can YOU utilize cadaveric specimens for your research, training and educational needs?

#### Call or Email us today:

[research@sciencecare.com](mailto:research@sciencecare.com) | 844 825 3480

From Outside the U.S., call: 1 602 288 0047

Visit us Online: <http://research.sciencecare.com>



Science Care®

# 2016 IFSSH Delegates' Council Meeting

This year's annual IFSSH Delegates' Council Meeting will be conducted in Buenos Aires, in conjunction with the triennial IFSSH Congress - October 24-28. Full details will be provided nearer to the meeting.

## IFSSH Membership

The IFSSH currently consists of 56 member societies. We welcome applications from hand surgery societies to join the IFSSH.

The requirements for membership are:

- The applying society must be a bona fide organization whose individual members have a major interest in surgery of the hand,
- The applicant society shall have been in existence for at least two years,
- The society shall submit a list of officers and members, its constitution (or Bylaws) and the requirements for admission of members,
- Each applicant society shall be sponsored by three Council delegates.

Applications are considered by the IFSSH Executive Committee and

Delegates' Council at the annual meeting (Buenos Aires, October 2016). Societies interested in applying for membership should contact the IFSSH secretariat: [administration@ifssh.info](mailto:administration@ifssh.info).

## 2022 IFSSH Congress Host Society

The IFSSH Executive Committee has recommended that member societies from the European region\* be invited to host the 2022 triennial congress. This main scientific event of the IFSSH will be celebrated every three years in a member society country that is in good standing with the IFSSH, including payment of their annual dues.

The society hosting the event will be selected from applications six years before at the annual Delegates' Council meeting. Those societies from countries which also have a hand therapy association/society should discuss the possibility of hosting a combined meeting. The societies which are applicants must submit a formal petition to the Secretary General at least three months ahead of the Council meeting. The same documentation should be sent to each member

country delegate and IFSHT representative for evaluation at least three months before the Council Meeting.

Therefore, any European member society that is interested in hosting the 2022 IFSSH Congress should inform the IFSSH Executive of their intentions and ensure that the full bid is forwarded, as detailed in the instructions above, by July 24th 2016, for consideration at the Buenos Aires meeting.

Information regarding the application process is on the IFSSH website: <http://ifssh.info/guidelines.html>

\*The IFSSH member societies have been geographically grouped according to United Nations data. The IFSSH "European" region consists of: Austria, Belgium, Bulgaria, Czech Republic, Denmark, Finland, France, Germany, Greece, Hungary, Italy, Lithuania, Netherlands, Norway, Poland, Portugal, Romania, Russian Federation, Slovakia, Spain, Sweden, Switzerland, Turkey, United Kingdom

For the purposes of the IFSSH congress rotation system, the two

IFSSH member nations that lie within the African region - Egypt and South Africa - have been aligned with the European region and are therefore also able to bid for the 2022 Congress.

## Educational Sponsorship / IFSSH Harold Kleinert Visiting Professor

The IFSSH invites applications for funding assistance of educational projects. These may be worthy education projects of any description and are awarded funding on a competitive basis, after assessment by the IFSSH Committee for Educational Sponsorship.

In addition to the general funding available, specific grants are also available to:

- provide financial assistance to the organisation of Hand Surgery regional education courses;
- assist hand surgeons from poor or developing communities to attend an IFSSH triennial Congress through the provision of IFSSH Congress Assistance Grants; and
- promote the international exchange of hand surgery knowledge by sponsoring an IFSSH Harold Kleinert Visiting Professor to an appropriate hand surgery education programme.

General applications can be submitted for assessment at any time throughout the year, but should be received at least three months in advance of when the

funding is required. Full details of the application process, and further information regarding the specific grant categories, are on the IFSSH website: <http://ifssh.info/fellowship-grants.html>

## Future Meetings

A detailed list of national and regional hand surgery meetings is available on the IFSSH website.

The triennial IFSSH Congresses are as follows:

XIIIth IFSSH – Xth IFSHT Congress – Buenos Aires, Argentina  
October 24-28, 2016  
[www.ifssh-ifsht2016.com](http://www.ifssh-ifsht2016.com)

XIVth IFSSH – XIth IFSHT Congress – Berlin, Germany  
May, 2019

**Marc Garcia-Elias**  
Secretary-General, IFSSH  
Email: [secretary@ifssh.info](mailto:secretary@ifssh.info)



ezine  
**ifssh**  
CONNECTING OUR GLOBAL HAND SURGERY FAMILY

## IFSSH DISCLAIMER:

The IFSSH ezine is the official mouthpiece of the International Federation of Societies for Surgery of the Hand. The IFSSH does not endorse the commercial advertising in this publication, nor the content or views of the contributors to the publication. Subscription to the IFSSH ezine is free of charge and the ezine is distributed on a quarterly basis.

Should you be interested to advertise in this publication, please contact the Editor: [ezine@ifssh.info](mailto:ezine@ifssh.info)

## IFSSH EZINE EDITORIAL TEAM:

### EDITOR:

**Professor Ulrich Mennen**  
(Immediate Past President of the IFSSH)

### DEPUTY EDITOR:

**Professor Michael Tonkin**  
(President of the IFSSH)

### GRAPHIC DESIGNER:

**Tamrin Hansen**

### TO SUBSCRIBE GO TO:

[www.ifssh.info/ezine.html](http://www.ifssh.info/ezine.html)



# Creating A New Surgical Speciality

## in a state health care system

### A LONG TERM STRATEGY

When I started work as a consultant hand surgeon in the United Kingdom in 1981 there were two full time hand surgery posts; one in Glasgow and my appointment in Derby. The remainder of hand surgery care was provided by orthopaedic and plastic surgery consultants with a partial involvement in hand surgery. In 2015 there are now approximately 80 full time hand surgeons working in groups around the country and providing a 'hub and spoke' model for hand surgery care. This paper describes the manner in which these changes have occurred and the strategy employed to achieve these goals over the last 35 years. The subject will be discussed under the heading of significant milestones in the birth of a speciality.

#### 1. Parent speciality apprehension about the development of sub-specialty interests

This is inevitable at the outset.

In the case of hand surgery in the United Kingdom it was orthopaedics that exhibited considerable disquiet when a group of senior surgeons discussed setting up the 'Hand Club', an association of eventually 12 surgeons, of whom approximately half were drawn from orthopaedics and half from plastic surgery. In 1952 the matter had been discussed widely among senior surgeons, possibly in part relating to Sterling Bunnell's (Fig 1) visit to the United Kingdom previously and the establishment of an American Hand Society.

Sir Reginald Watson-Jones (Fig 2) telegraphed Guy Pulvertaft to 'Think long and carefully before supporting such a sub-speciality interest, if it led to clinical meetings which would fragment the parent speciality'. Sir Reginald considered consultants with a sub-speciality interest in spines would create a similar risk to orthopaedics and that the logical conclusion

to this fragmentation would be a society for surgeons specialising in surgery of the thymus! The irony of the situation may have been lost on Sir Reginald, who I suspect spent the first twenty years of his professional life fighting off interference in orthopaedics from general surgeons (the original parent surgical speciality) and then found himself in a similar situation to the general surgeons



Fig 1. Sterling Bunnell




Fig 2. Sir Reginald Watson-Jones

when a hand club was being mooted. Another orthopaedic surgeon complained to Guy Pulvertaft of the risk of losing hand surgery to 'rapacious plastic surgeons' and there seemed to be a common view that, although some orthopaedics surgeons did not want to do hand surgery, they did not want any other speciality to do it either! I always found in my own practice, when dealing with the progressive separation of hand surgery from orthopaedics, that you have to bring something positive to the discussion and this would obviously start with the expectation that you will take responsibility for traumatic hand surgery. If you want to be separate from orthopaedics, but cherry pick the less onerous responsibilities, it will inevitably sit poorly with one's colleagues.

#### 2. Set up a vibrant sub-speciality clinical group

Sir Reginald Watson-Jones could

not stop the evolutionary engine of change and very swiftly the Hand Club found themselves in a similar position. In 1955 Graham Stack wrote to the Hand Club on his and several other young surgeons behalf. They were all enthusiastic about hand surgery and history would prove they would make major contributions to the speciality. The names on the letter were Graham Stack, Adrian Flatt, Stewart Harrison, Donal Brooks, Dick Dawson, Robbie Robbins and Douglas Campbell-Reid. Their letter was carefully flighted, expressing their abiding interest in hand surgery and that they were keen to exchange ideas; 'We are therefore asking you, as the only existing group of hand surgeons in this country, for your help and guidance as to how these ends might be achieved?'

The Hand Club (still restricted to 12 members) met and decided they did not want to expand their group. Rebuffed, the young enthusiasts set up the 'Second Hand Club' under the extremely able secretaryship of Graham Stack (Fig 3), who seems to have had a far clearer view than most on where their efforts might lead. Membership rose rapidly, and the two clubs amalgamated in 1964.

#### 3. Produce a creditable journal to disseminate knowledge to members and more widely

Graham Stack took the minutes of the original meeting in Derby in May of 1956 and circulated them to all members. These documents

morphed into the Proceedings of the Second Hand Club, which eventually were re-edited and published as a book in 1975. Graham Stack felt a more formal journal was required and The Hand was produced in 1969 with Graham Stack as its editor and producer.




Fig 3. Graham Stack

Editorial staff slowly expanded as the journal provided a reliable income stream for what had now become the British Society for Surgery of the Hand. The journal evolved again in 1984 to the Journal of Hand Surgery (British Volume). It joined the American Journal of Hand Surgery at Volume 9 (The Americans having published since 1976). More recently it has been renamed again as the European volume of the journal, as it caters for the needs of the European Federation of Societies for Surgery of the Hand. These preliminary stages of maturation related principally to

the development of a sub-speciality interest. However, once that stage had been reached, thought could be given to creating circumstances where a new speciality would be justified. Several of the projects that I describe next were progressed simultaneously, each providing support for the others.

“we (as trained hand surgeons) believe we are cheap to run and return patients to work more swiftly and more completely”

#### 4. Seeking recognition of the concept of hand surgery as a speciality by a regulating authority

Sir Terence English, President of The Royal College of Surgeons of England, heard representations from the council of the Hand Society in 1989, supported by manpower and activity data from an established hand unit.

He supported the concept of hand surgery being an interface speciality (between plastic surgery and orthopaedic surgery) and recommended that status to the Department of Health in 1990. The Department of Health recognised hand surgery as an interface speciality in 1991.

#### 5. Training fellowships in hand surgery

These were designed by the speciality without undue difficulty. The posts offered a 100% hand surgery experience of which two thirds would be in one parent speciality (for example orthopaedics) but the remaining time would have to be spent in a plastic surgery department, as would befit an interface training experience. Eventually support for these posts was received from the Department of Health with the necessary funding.

#### 6. A sub-speciality must have an agreed curriculum of knowledge which trainees are expected to acquire and the means to gain such knowledge

In 1997 the education committee of the British Society for Surgery of the Hand started planning six two-day symposia on hand surgery. The courses were to run in a three year cycle of two symposia yearly with the entire cycle covering all relevant matters related to hand surgery. The first meeting, which was held in my house as it was centrally placed



Fig 4. Simon Kay

in the United Kingdom, was chaired by Professor Simon Kay (Fig 4) and the committee spent a considerable amount of time identifying what was considered to be the core knowledge base to be disseminated. In this matter I have always believed Professor Kay's approach to have been as visionary as Graham Stack had been at the outset of our journey. We wished to reach the trainees in Europe as well as the United Kingdom and the choice of the venue for the meetings, Manchester, was based on a print out of the more extensive flight destinations from Manchester compared to Birmingham (the other potential candidate). The courses, which started in 1999 were, and I understand remain, a great success.

The interface speciality now had trainee fellows recognised by the government, a core curriculum they were expected to master and a cycle of symposia disseminating the knowledge.

#### 7. An assessment of clinical competence

Professor Kay and the council of the Hand Society raised their eyes



Fig 5. Vivien Lees

to the next logical requirement; there would need to be a creditable evaluation of trainee's performance in their declared interest. Professor Kay initiated the process, but then passed it on to Professor Vivien Lees (Fig 5), who drove this complex project through to completion. She very prudently realised that the evaluation of knowledge and educational rigor is not our area of primary expertise and drew in educational experts from Manchester University. The Diploma of Hand Surgery was the outcome and the examination was held for the first time in 2007. I have had the opportunity to study it closely, as an external examiner, and I consider it to be a modern, fit for purpose assessment of competence.

#### CONCLUSION

Hand surgery's journey in the United Kingdom to a fully independent speciality is almost run. We remain recognised as an interface specialty between plastic surgery and orthopaedics with a reputable journal and defined curriculum of knowledge. The Hand Society has created creditable courses to teach trainees with a robust assessment of the knowledge they have acquired. Full recognition of the speciality in its own right has, to date, eluded us. That may well come from developments in Europe if sufficient countries recognise the speciality of hand surgery in its own right. It would be easy to be irritated about our semi-independent state, but I see matters otherwise. I am impressed by what I see; a vibrant society with harmony between plastic and orthopaedic surgeons; we teach and we evaluate competence.

Are there any additional ways we can advance our relevance with government? I think there would be benefit on refocussing our research and audit to include cost benefit analyses of our interventions. We should be confident enough to expose ourselves to such a challenge; we believe we are cheap to run and return patients to work more swiftly and more completely. We preserve people's independence into the retirement years. If we do provide those benefits we should

demonstrate them to government and reap the rewards that should follow.

#### References

- Robbie Robbins – Personal communications
- N J Barton 1998. The First 30 years of the British Society for Surgery of the Hand. Journal of Hand Surgery 23 B 6 711-723
- Charles Chapman. The British Society for Surgery of the Hand; in The History of the British Association of Plastic Surgeons. 1987 Churchill Livingstone Ed A F Wallace



Frank D. Burke



# DANIEL C. RIORDAN, MD



Daniel Riordan (1917–2012), clinician professor and author in orthopaedic and hand surgery, has earned his fame for his scientific and humanitarian work in the care of crippled children, patients with leprosy, and arthritic problems in the hand and upper extremity.

He pioneered new surgical procedures for hand reconstruction including tendon transfers for the paralyzed hand, finger transposition, and resection arthroplasty of the metacarpophalangeal joint.

A native of Vallejo, California, he completed his Medical Doctorate and one year of residency in general surgery and orthopaedic surgery at Stanford University School of Medicine, Palo Alto, California. Dr. Riordan served in the U.S. Army Medical Corps at Valley Forge General Hospital, Phoenixville, Pennsylvania, in the Orthopaedic and Hand Surgery Service under the guidance of Sterling Bunnell (1945 to 1947). He did a preceptorship in Nashville, Tennessee with Drs. George Carpenter and S. Benjamin Fowler and went to New York City where he was Resident and Instructor in Orthopaedic Surgery at New York Hospital, Cornell Medical Center (1948-1949).

Dr. Riordan became interested in the care of patients with Hansen's disease at the United States Public Health Service Hospital in Carville, Louisiana, where he did his landmark work and innovative procedures for the paralytic hand. In New Orleans he was on the Staff of the Southern Baptist Hospital and Touro Infirmary, Senior Visiting Surgeon at the Charity Hospital and Orthopaedic Consultant in Hand Surgery at the U.S.P.H.S. Hospital. Always interested in giving crippled children a brighter future, Dr. Riordan worked with them first in New Orleans and then in Shreveport through the Handicapped Children's and Shriner's Program. He established a Hand

Clinic at the Shriner's Hospital for Crippled Children in Shreveport which became a major referral center.

Dr. Riordan was Professor of Clinical Orthopaedics at Tulane University and Louisiana State University Schools of Medicine, and trained more than 85 Orthopaedic Residents. He has authored numerous scientific articles, textbook chapters, videotapes, and has lectured through the U.S. and in nearly every country of the world. He performed surgery in India, Africa and South America. He was the U.S. Representative to the World Health Organization for Rehabilitation of Leprosy in India (1960) and Visiting Professor in Hand Surgery at the University of Witwatersrand in Johannesburg, South Africa (1970, 1972). He was the National Consultant in Hand Surgery for the Surgeon General of the Air Force for over 15 years, and taught at military bases in Europe, Japan and Vietnam.

Riordan was an American Orthopaedic Association Traveling Fellow to England in 1955. His memberships include the American Society for Surgery of the Hand (President, 1960), Southern Medical Association (Orthopaedic Chairman, 1960), New Orleans Graduate Medical Assembly (President, 1974), Louisiana Orthopaedic Association (President, 1969), Russel Hibbs Society (President, 1972), American Academy of Orthopaedic Surgeons and American Orthopaedic Association.

He gave the Sterling Bunnell (1966) and the Sumner L. Koch (1968) Memorial Lectures, and received the President's Citation for Meritorious Service on Employment of the Handicapped for the State of Louisiana (1967) and the Orleans Paris Medical Society Outstanding Physician Award (1990). In 1992, at the fifth international congress of the International Federation of Societies for Surgery of the Hand (IFSSH) held in Paris, France, Daniel C Riordan was honoured as "Pioneer of Hand Surgery"

# HAROLD E. KLEINERT, MD



A tireless worker in all aspects of hand surgery and microsurgery, Dr. Kleinert has distinguished himself in patient care, teaching, and research. He helped pioneer the development of microsurgery and micro-instruments as applied to the specific problems of the hand. His work in primary

surgical treatment of flexor tendon injuries transformed treatment of these injuries world-wide. He established one of the early fellowship programs for hand surgery and has contributed to the training of more than 600 surgeons from over 40 countries, many of whom have gone on to become leaders in their fields or heads of their own hand surgery programs in the United States and abroad. Over 200 articles, book chapters, and reports have been published to his credit.

Harold E Kleinert (7.10.1921 - 26.9.2013) was born near Sunburst, Montana and graduated from Temple University Medical School, Philadelphia, Pennsylvania, in 1946. His internship and residency programs at Grace Hospital in Detroit, Michigan, were the beginning of his interest in the challenging problems of hand and vascular surgery. Moving to Louisville in 1953, he helped establish the University of Louisville School of Medicine's first animal surgical research facility and a hand surgery clinic. In 1960 the Christine Kleinert Fellowship in Hand Surgery Program was begun which grew to become the largest training program for hand surgeons in the United States.

In 1973, Dr. Kleinert visited China as a member of the American Replantation Mission. In 1976 he served as President of the American Society for Surgery of the Hand. Among his awards and honors are the Scientific Achievement Award from the American Medical

Association (1980), the Honorary Award Medal from the American Association of Plastic Surgeons (1980), and the Distinguished Alumni Scientific Achievement Award in Surgery from Temple University School of Medicine (1987). He gave the Sterling Bunnell Memorial Lecture (1978), the Scudder Oration on Trauma at the American College of Surgeons 67th Annual Clinical Congress (1981), and the Founder Lecture of the American Society for Reconstructive Microsurgery (1986).

A Fellow of the American College of Surgeons, Dr. Kleinert is a member of many national and international societies, including the American, French, British, Italian, Canadian, Caribbean, Colombian, Brazilian, Israel and Australian Societies of Surgery of the Hand. He has traveled to many countries in the world as a Visiting Professor or Guest Lecturer.

Sine 1973 he has been a National Consultant in Hand Surgery to the Surgeon General, United States Air Force. He is a retired Colonel of the Kentucky Air National Guard. Dr. Kleinert was Clinical Professor of Surgery at the University of Louisville and at Indiana University-Purdue University.

At the fifth International Congress of the International Federation of Societies for Surgery of the Hand in Paris, France in 1992 Harold E Kleinert was bestowed the honour of "Pioneer of Hand Surgery".

Further, in recognition of the immense contribution to the promotion of Hand Surgery internationally, the IFSSH has named one of its educational sponsorships "The IFSSH Harold Kleinert Visiting Professorship"



# Letter to the Editor

## Daniel J. Nagle MD

A call to Louisville Fellows to support the Harold Kleinert Traveling Fellowship

Dr. Harold E. Kleinert passed away on September 26, 2013. The news of Dr. Kleinert's passing elicited an immediate and universal call for a way to memorialize Dr. Kleinert's contributions to the world of hand surgery.

The IFSSH, under the leadership of Prof. Michael Tonkin (President: IFSSH), has responded to that call by creating the Harold Kleinert Visiting Professorship. This Professorship is a fitting tribute to Dr. Kleinert, a man dedicated to international hand surgery education. The IFSSH Harold Kleinert Visiting Professorship will underwrite the visit of selected hand surgeons (one per year) to hand surgery centers throughout the developing world. This professorship will be funded by the IFSSH. This will allow well-known expert hand surgeons to visit hand surgery centers that would otherwise be unable to fund a visiting professor.

Dr. Joseph Kutz, Co-founder of the Kleinert & Kutz Hand Care Center and former Louisville fellows Daniel Nagle MD, David Netscher MD, David Hildreth MD and Luis Scheker MD envisioned another way of honoring the memory and philosophy of Dr. Kleinert by creating The Harold Kleinert Travelling Fellowship Fund. This fund, which has a funding goal of \$500,000 US, of which over \$250,000 US has already been pledged, will be used to support a traveling hand surgery fellowship for promising young non-American hand surgeons. The Fellowship will support travel to two hand surgery centers, to the Kleinert & Kutz Hand Care Center in Louisville, Kentucky and to the annual meeting of the American Society for Surgery of the Hand.

If you are a former Kleinert fellow please reflect on the impact Dr. Kleinert had on you personally and how this fund can have a lasting impact on future generations of hand surgeons and patients. Hopefully these thoughts will encourage you to support the fund with a generous gift. Please consider a gift of \$1,000 or more (several donations of \$25,000 have been received) though any amount would be appreciated. Please note your donation can be paid over five

years. (For example, a donation of \$1000 would require the payment of only \$200 per year or about \$18 per month.) You can donate to the Fund by following the links below. Please be sure to direct your gift to the Harold Kleinert Traveling Fellowship Fund. Again, rest assured your donation will be used to support ONLY The Harold Kleinert Travelling Fellowship Fund.

Donation options include the following:

- Multi-year pledge
- One-time donation
- Donate a gift of stock
- Pay by check – make check out to the AFSH and write-in the memo line "Kleinert Fund." Send to: AFSH, Department 2026, PO Box 87916, Carol Stream, IL 60188, USA
- Donate online at [http://bit.ly/HEK\\_fund](http://bit.ly/HEK_fund) or visit [www.AFSH.org](http://www.AFSH.org) and click "Donate Now" to direct your donation to the Kleinert Fund. For questions contact [afsh@assh.org](mailto:afsh@assh.org).

The American Foundation for Surgery of the Hand (AFSH) has been selected as the Fund administrator. Please note, ASSH membership is NOT required to contribute to The Harold Kleinert Travelling Fellowship Fund. Also please understand your donation will ONLY be used to support The Harold Kleinert Travelling Fellowship Fund. The AFSH is acting only as an administrator for the fund. Your donation entitles you to all of the privileges and recognition extended to donors of the AFSH even if you are not an ASSH member. Additionally, donors who pledge \$25,000 or more are invited to join the AFSH "Leadership Circle" and have a mold made of their hand which will be made into a bronze colored casting which will be displayed in the "Show of Hands" major donor wall in the Robert Chase Library at the ASSH central office in Chicago. A solid gold lapel pin is also given to those who donate \$25,000 or more.

One final note:

The Harold Kleinert Traveling Fellowship should not be confused with the Christine Kleinert fund that is based in Louisville and is used to help fund the operations of the Kleinert & Kutz Hand Care Center fellowship program. It is not the goal of the Harold Kleinert Traveling Fellowship Fund to detract from the Christine Kleinert fund. The two funds have different purposes and once the Harold Kleinert Travelling Fellowship is fully funded (\$500,000 US) no further donations will be solicited.

I thank Prof. Ulrich Mennen (Past-President, IFSSH and Editor, IFSSH Ezine) for giving the Harold Kleinert Traveling Fellowship Fund the opportunity to reach out to former Louisville fellows regarding this most important and worthwhile fund.

Daniel J. Nagle MD

On behalf of the Harold Kleinert Traveling Fellowship



# IFSSH Scientific Committee on Brachial Plexus Injury

**Chair:** Yuan-Kun Tu (Taiwan)

**COMMITTEE:** RYOSUKE KAKINOKI (JAPAN), SOMSAK LEECHAVENGVONGS (THAILAND), ALEXANDER Y SHIN (USA), JACQUELINE SIAU-WOON TAN (SINGAPORE)

**REPORT SUBMITTED AUGUST 2015**

## Current Trends in the Management of Adult Brachial Plexus Palsy Part I: Upper arm type

### Abstract

The brachial plexus consists of cervical nerve roots C5, C6, C7, C8, and thoracic nerve root T1. Upper arm type brachial plexus injury (BPI) means C5 and C6 root injury with or without C7 injury. Nerve injury caused by sharp cut or stab injury might be treated with direct repair with or without a nerve graft. However, for most of the BPIs which were caused by high velocity trauma, nerve root avulsion or rupture require nerve transfer (neurotization) to bypass the damaged zone thereby allowing patients to regain critical shoulder and elbow functions faster. In this review article, we present various reconstructive nerve / tendon transfer techniques for the management of adult upper arm type BPI. With the modern advances of microsurgery, the shoulder and elbow functions can be successfully recovered in around 80% to 90% of upper arm type BPI patients.

### Introduction

Injuries to major nerves of the upper extremities, especially the brachial plexus, have devastating consequences owing to the resultant motor, sensory, and autonomic function loss associated with such injuries.<sup>1-5</sup> Unfortunately, such injuries are occurring with increasing frequency, owing to high-velocity civilian injuries (motor vehicle and motorbike accidents) and, more recently, war related injuries seen in war veterans. Patients suffering from upper arm type BPI present with loss of motor function in shoulder elevation / abduction / external rotation, and elbow flexion. The other major clinical problems are pain and loss of adequate sensory function.<sup>5-7</sup> Microsurgical repair of injured nerves has achieved significant advancement, but the functional recovery is still suboptimal.<sup>2,4</sup> Direct microsurgical repair of injured nerves, especially in sharp cut and stab injury, represent the best repair strategy when feasible. However, even with such repairs, return of useful function cannot be guaranteed,

especially in avulsion root injuries or for denervated targets that are farthest from the injury sites.<sup>4,5,9</sup> Hence, regenerative distance and time to reinnervation represent some of the key determinants of functional outcomes after injuries to brachial plexus nerve trunks.<sup>4,5,9-13</sup> Nerve transfers (neurotization) represent a relatively novel approach to restore useful upper limb function after severe proximal nerve injuries in BPI. Nerve transfer technique reduces the distance to reinnervate target organs by delivering expendable motor and/or sensory axons close to the denervated end organs.<sup>1-4,9-12,14-21</sup>

### History of BPI and reconstruction

Brachial plexus injuries have been reported directly or indirectly for the last 2800 years. The first mention of a BPI in the literature occurs in Homer's "The Iliad" around 800BC.<sup>2,22</sup> The attempts to reconstruct the BPI by direct suturing the ruptured nerve stumps, or free interposition sural nerve grafting had gained its popularity after the development of microsurgical techniques and

equipment.<sup>23,24,25,26</sup> However, the results of direct nerve repair or free nerve grafting for BPI did not obtain satisfactory clinical results, which altered the trends of BPI reconstruction toward the technique of nerve transfers.<sup>1-5,9-21,24,27</sup> In 1824, French physiologist Marie Jean Pierre Flourens was the first to theorize that an injured nerve could be bypassed by suturing the superior end of one nerve with the inferior end of the other nerve.<sup>28,29</sup> But the first brachial plexus reconstruction by using the nerve transfer technique was reported on a 20 year old female injured by a Nazi bomb blast. The surgery was performed prior to the advent of microsurgical instruments / equipment, by a Russian surgeon, Alexander Lurje, in 1948.<sup>30</sup> Our improved understanding of nerve pathophysiology, anatomy, repair, and reconstruction has led to advances in the treatment options for upper arm type BPI in the past 30 years.

### Physical examinations and diagnostic tools for upper arm type BPI

The mechanism of most BPIs is a traction injury, in which the head is forcefully distracted from the ipsilateral shoulder. This manner of traction force typically results in pre-ganglionic root avulsion or post-ganglionic rupture of the upper trunk (C5-C6) and middle trunk (C7), while sparing the lower trunk (C8 and T1).<sup>9</sup> The typical findings in physical examination for upper arm type BPI are the loss of elbow flexion and shoulder elevation / abduction /

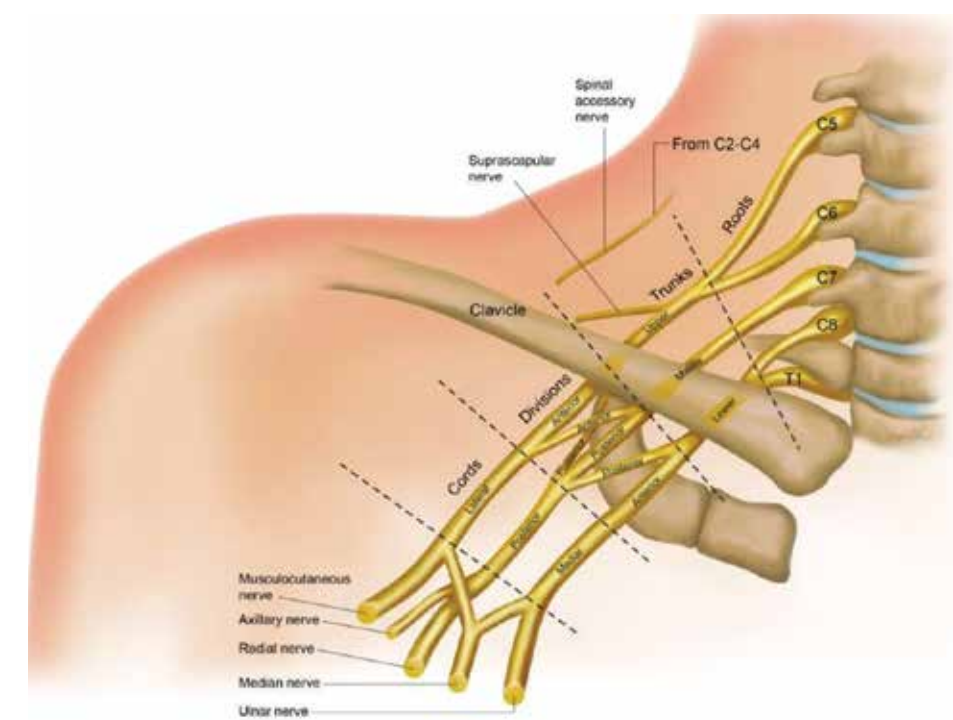
external rotation in C5 and C6 roots injury. The physical examination of individual muscle function reveals that paralysis of the biceps, brachialis, deltoid, and the rotator cuff are seen commonly,<sup>12,16,17</sup> while the additional loss of wrist dorsiflexion or finger extension implies that the C7 root is also damaged with possible concomitant incomplete lower trunk (C8, T1) injury.<sup>9,14,15,16</sup> These physical findings can be reasonably explained by understanding the anatomy of brachial plexus (Figure 1).

In addition to physical examination, the diagnosis of upper arm type BPI is confirmed by serial needle electromyography (EMG) and nerve conduction velocity (NCV) studies, CT myelograms, and magnetic resonance myelography (MRM).<sup>5,9,12</sup> These diagnostic tools are required to

be performed prior to brachial plexus exploration. Typically, the first EMG and NCV are performed 6 weeks following trauma, and the second EMG / NCV studies are performed 3 to 4 months after injury if indicated. If no progress is identified on the EMG / NCV or during physical examination, then a CT myelogram or MRM is obtained and plexus exploration is performed.

### Philosophy and concepts of upper arm type BPI reconstruction

Many studies document nerve regeneration following injury; however the clinical results regarding recovery remain elusive.<sup>1,2,4</sup> As we understand that once the nerve begins to regenerate, it moves at around 1-1.5 mm daily.<sup>2,12,31</sup>



**Figure 1: Anatomical diagram of the brachial plexus. The spinal accessory nerve originating from C2-C4 is also shown.**

The motor endplates with which the nerve communicates will eventually cease to function in 12-18 months.

If a proximal plexus injury occurs, then the regenerated nerve may not reach the motor endplate in time to be effective. Therefore, using the nerve transfer technique of harvesting nerve fascicles from uninjured nerve and transferring to the injured nerve (close-target neurotization) may facilitate the salvage of critical motor endplates and their corresponding muscles.<sup>1-4,8,10,12,14</sup>

This nerve re-routing essentially converts a proximal nerve injury into a distal nerve injury closer to the motor endplate and denervated muscle. By this neurotization method, the proximal nerve stump can reach the target muscle before motor endplate degradation.

Post-ganglionic root sharp-cut and rupture injuries are amenable to primary nerve repair and nerve grafting, whereas pre-ganglionic avulsion lesion injuries require nerve transfers.<sup>9,10,21,23,24,32,33</sup> Although intra-plexus nerve transfers (such as ulnar nerve or median nerve transfer to musculocutaneous nerve, and radial nerve transfer to axillary nerve) remain the best options for pre-ganglionic root avulsion injuries, some injuries which avulse or rupture more than 80% of the plexus roots are not good candidates for nerve transfer due to the partial loss of the motor nerves in the lower trunk.<sup>2-5,12,16,17,31</sup> In these situations (such as complete C5,6,7 injury with incomplete C8,T1 injury), extra-plexus nerve transfers (by using neurotization from the

spinal accessory nerve, phrenic nerve, intercostal nerve, or contralateral C7 root) are the methods of choice for BPI construction.<sup>2,4,9,10,12,13,15,24,27,34-36</sup>

Re-implanting avulsed spinal roots directly into the spinal cord for the reconstruction of pre-ganglionic avulsion BPI has been reported from the United Kingdom with acceptable clinical outcomes.<sup>37,38</sup> However, this nerve root re-implantation technique has not been popularly used in the field of brachial plexus reconstruction.

#### **Factors influencing the outcomes of nerve transfers**

The outcomes of nerve transfers for BPI patients depend on four factors which may influence the clinical results. The first factor is patient selection. Studies have shown that younger patients recover from nerve transfer faster and ultimately have better outcomes than older patients. Typically patients under 40 years of age have the best functional outcomes following nerve transfer.<sup>12,18,39</sup> In addition to age, some other factors such as tobacco use, body mass index (BMI), patient's compliance, and social-economical status also influence the surgical outcomes of BPI patients.<sup>2-5,9,10,18,21,40,41</sup> The use of tobacco and obesity tend to result in less satisfactory outcomes than in patients who do not smoke, or patients who have a normal BMI. It is critical that the patient adheres to an occupational therapy and physical therapy program both before and after surgery. An adequate scheduled rehabilitation program may prevent joint stiffness before nerve surgery, and may also allow early

joint passive range of motion during the interval between a nerve transfer procedure and target muscle power recovery.

The second factor is the timing of reconstruction. Many studies have shown that nerve transfers performed within 6 months post-injury yield results superior to transfers performed after 6 months post-injury.<sup>1-5,9,12,15,18,21,27,31,39,42</sup> When the interval between injury and nerve reconstruction surgery is more than 9 to 12 months after trauma, then the surgical options are either tendon transfer or free functioning muscle transfer, instead of nerve transfers.<sup>5,12,43,44</sup>

The third factor is the extent of initial nerve trauma. We are aware that many nerve transfer methods such as Oberlin I nerve transfer (fascicle of ulnar nerve transfer to musculocutaneous nerve), and Somsak's method (branch of radial nerve transfer to axillary nerve) have quite satisfactory outcomes in C5 and C6 roots injury. However, when injury involves not just the C5 and C6 roots, but also the C7 root or partial damage of lower trunk, the intra-plexus nerve transfers are not optimal surgical procedures for BPI reconstruction.<sup>2-5,12,16,17,31</sup> Surgeons may need to apply the techniques of extra-plexus nerve transfers (such as phrenic nerve, spinal accessory nerve, intercostal nerve, or contralateral C7 root) for BPI reconstruction.<sup>2,4,9,10,12,13,15,24,27,34-36</sup> The outcomes of extra-plexus nerve

transfers are not as satisfactory as intra-plexus nerve transfers, especially for elbow flexion.<sup>4,15,21,39,45</sup> Therefore, the extent of initial nerve trauma plays an important role in determining the surgical outcomes in BPI.

The fourth factor is the priority of functional reconstruction. The two most important functions which need to be restored in upper arm type BPI are elbow flexion and shoulder abduction / elevation / external rotation.<sup>1-4,12,14,16,31,46</sup>

Elbow flexion is critical to human interaction with the environment, and its restoration is the principal goal of BPI reconstruction. This is particularly true in C5-C6 injuries where the musculocutaneous nerve (MCN) has been compromised. The MCN innervates the biceps and brachialis which are the elbow flexors. Restoration of elbow flexion can significantly improve the activities of daily living for the BPI patient.<sup>1-5,9,10,12,14-21</sup> Restoration of shoulder stabilization and elevation / abduction / external rotation are the second most important priorities in primary reconstruction of BPI.<sup>4,9,10,12,14,15,31,39,42,46</sup> In addition to suprascapular nerve (innervation of the supra- and infra-spinatus muscles of rotator cuff), the axillary nerve (innervation of the deltoid muscle) is also compromised in C5-C6 injuries.<sup>14,15,47</sup> Nerve transfers to both the suprascapular nerve and axillary nerve may restore the function of rotator cuff muscles and deltoid muscle which may abduct / elevate / externally rotate, and stabilize the shoulder, providing a solid platform

for both elbow and hand functions.<sup>10,12,14,15,16,46,47</sup>

#### **Nerve repair, nerve grafting, and nerve transfer options for elbow flexion in upper arm type BPI**

Nerve repair is indicated for the treatment of open wounds with clean transection of a part of the brachial plexus, if the proximal and distal stumps can be clearly identified.

<sup>12,4,5,8,9,48</sup> Direct coaptation of the proximal and distal stumps of the disrupted musculocutaneous nerve, the lateral cord, or the C5-C6 upper trunk by microsurgical techniques may obtain the most predictable and reliable clinical outcomes.<sup>3,5,9,12,23,25,26,48</sup>

Nerve grafting is indicated in cases with loss of continuity, either caused by sharp or traction injury at the level of the post-ganglionic level, trunk level, or cord level. Since it remains doubtful whether useful regeneration can occur in a reasonable time, the neuroma should be resected. After the proximal and distal stumps have been properly prepared after neuroma resection, a direct nerve coaptation suture is usually impossible, due to fibrosis and shrinkage of nerve stumps after trauma. If the nerve defect is short, then the continuity can be restored by an interposition nerve graft. The most commonly used free nerve graft is sural nerves harvested from the legs. The length of sural nerve is up to 30 cm long.

Knowledge of the cross-sectional intraneural topography should be adequately applied to achieve proper

anatomical coaptation between proximal and distal nerve fibers. In upper arm type BPI, if the defect is between C5 and C6 roots proximally and in the upper trunk level distally, the sural nerve graft coaptation suture with C5 should be connected to the distal stump with the part of the cross-sectional surface that forms the posterior division; whereas the sural nerve graft coaptation with C6 proximally should be connected with anterior division of the cross-sectional surface distally.<sup>3,9,24,25,32,33,48</sup>

However, in cases with longer nerve defects, the anatomical cross-sectional coaptation suture with sural nerve graft seems to be impractical. Because there is not enough autologous donor nerve available to restore continuity to all parts of the plexus, and nerve fiber exchange within long segments loss of the brachial plexus is high, there is a high possibility of nerve fiber loss after nerve grafting surgeries due to the deviation of regenerating axons. Therefore, it is more practical and has been proven to be more successful to connect proximal stumps directly with distal nerves, instead of a connection with ill-defined distal stumps at trunk or division levels. For instance, if there is a long nerve defect between C5 and C6 and the posterior and lateral cords in upper arm type BPI, the ideal method is to use sural nerve graft connecting the proximal C6 stump directly to the musculocutaneous nerve of the lateral cord distally. Then the regenerating nerve fibers go directly to the musculocutaneous nerve and provide motor innervation



to the biceps and brachialis muscles.  
4, 9,12,15,25,32,33,48 Nerve grafting provides good results for elbow flexion in 70-75% of cases with upper arm type BPI.  
3, 15, 23,25,33,48

There are several nerve / tendon transfer options for the reconstruction of elbow flexion in upper arm type BPI. The donor nerves applied for BPI neurotization include: ulnar nerve (UN), median nerve (MN), intercostal nerve (ICN), spinal accessory nerve (SAN), phrenic nerve (PN), and medial pectoral nerve (MPN). The recipient nerve is the musculocutaneous nerve (MCN). The following six techniques are the most commonly used methods.

1. Oberlin I method:

The current most commonly used nerve transfer technique for elbow flexion in upper arm type BPI is the Oberlin I transfer which was first described by Christophe Oberlin of Paris in 1994. He described the transfer of one or two nerve fascicles from the UN directly coapted to the biceps motor branch of the MCN (Figure 2A-C).<sup>19</sup>

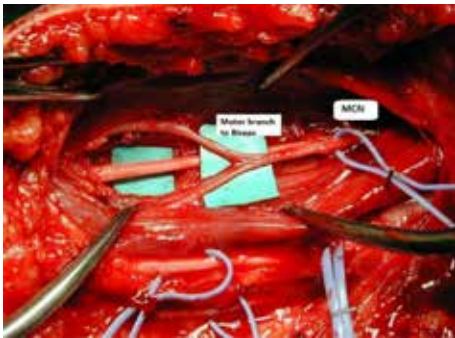


Figure 2A: Oberlin I neurotization. The motor branches to biceps (in this patients, two branches were found) were identified.

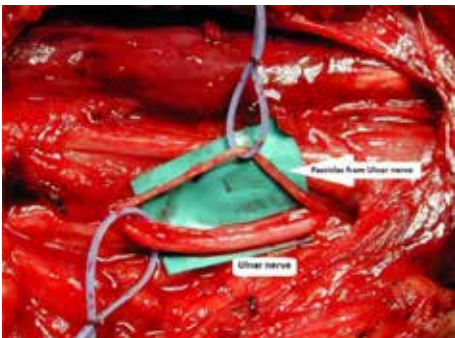


Figure 2B: Two motor fascicles from UN were identified.

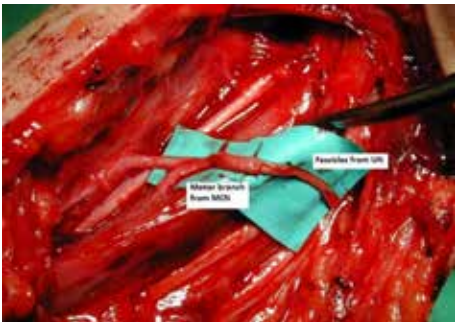


Figure 2C: The motor fascicles from UN were transferred to the motor branches from MCN to biceps by 9-0 Nylon coaptation suture.

This transfer restores elbow flexion following loss of the MCN, a branch of lateral cord. In 2004, he reported that 20 of 32 patients who underwent this procedure recovered active motion against gravity and resistance (M4).<sup>20</sup> This procedure was validated by Leechavengvongs in Thailand who reported his experience with 26 of 32 patients (81.3%) who had regained M4 elbow flexion following the Oberlin I transfer.<sup>49</sup> In both studies none of the patients displayed any sequelae from sacrificing an UN fascicle as a donor.<sup>20,49</sup> The technique to choose adequate donor nerve fascicles of UN is very important. By using a nerve stimulator intra-operatively, surgeons

should choose the fascicles that innervate extrinsic muscles (such as flexor carpi ulnaris) for transfer. This selective nerve fascicle dissection can prevent a mistake in harvesting the fascicles of UN that supply the intrinsic muscles and cause donor site deficiency (such as claw hand deformity).<sup>2-4,12,14,16,17,19,20,48-50</sup>

2. Mackinnon's method (Oberlin II method):

Although the Oberlin I method is a common and practical technique for reconstructing elbow flexion in upper arm type BPI, some patients in the French and Thai studies unfortunately required further muscle origin transfers (Steindler flexorplasty) to improve elbow flexion. Surgeons found that when the brachialis muscle was also re-innervated in addition to biceps, the patient achieved better elbow flexion than biceps re-innervation alone.<sup>12,17,20,49,50</sup> In search of a procedure which could eliminate the need for additional muscle transfer, Susan MacKinnon in St. Louis along with Christophe Oberlin in Paris described the Oberlin II (double) nerve transfers in 2003.<sup>12,17,50,51</sup> In this reconstruction, one fascicle from UN was transferred to MCN, while one fascicle from MN was transferred to the motor branch to the brachialis muscle. (Figure 3A-C)

The additional re-innervation of the brachialis, a strong elbow flexor, has improved outcomes following loss of MCN. In 2005, Oberlin reported 15 of 15 patients (100%) recovering M4 elbow flexion, and Mackinnon reported 6 of

6 (100%) recovering M4 strength. No patient from either study showed any sign of motor or sensory loss.<sup>2,50,51</sup> the addition of the MN coaptation has

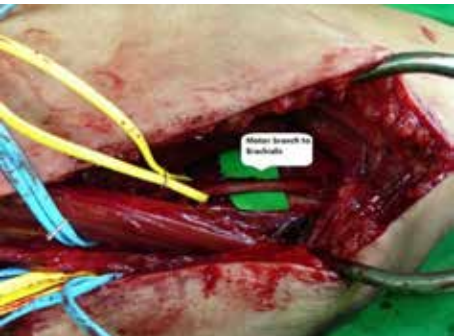


Figure 3A: Mackinnon's method (Oberlin II). The motor branch to brachialis muscle was identified.

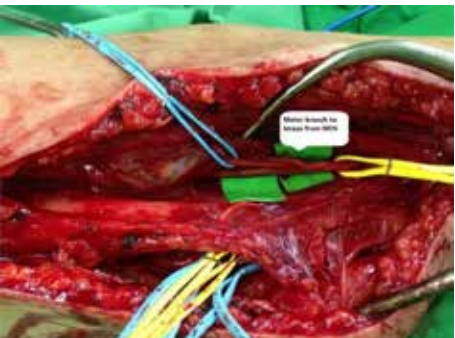


Figure 3B: The motor branch from MCN to biceps was also identified.

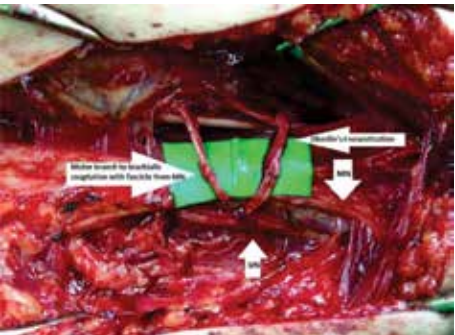


Figure 3C: The motor fascicle from MN was transferred to the motor branch to brachialis muscle, and the motor fascicle from UN was simultaneously transferred to the motor branch from MCN to biceps by 9-0 Nylon coaptation suture.

markedly increased the success rate of elbow flexion without sacrificing the donor nerve (MN and UN) function in hands.

3. Intercostal nerves (ICNs) transfer to MCN:

The ICN contains approximately 3,000 to 4,000 myelinated fibers, with each ICN carrying a different number of motor and sensory fibers.<sup>1,48</sup> The 3<sup>rd</sup> and 4<sup>th</sup> ICNs contain a significant number of motor fibers. ICN transfer was introduced by Yeoman and Seddon, but sparked by Japanese doctors Tsuyama, Hara, and Nagano.<sup>10,12,36,39,45</sup> It has been widely used for BPI neurotization, especially for reinnervation of the MCN.<sup>9,45,48</sup> The surgical approach for harvesting ICNs is extended from the usual supra- and infra-clavicular incisions at the anterior border of the axilla onto the infra-areolar (male) or inframammary fold (female) to gain access to the ICNs. Direct suture of 2 or 3 ICNs to MCN without nerve graft is the key to

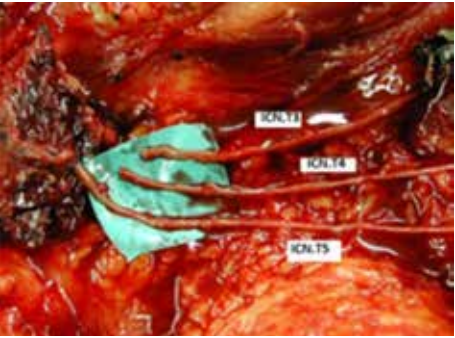


Figure 4A: Three intercostal nerves (ICNs) were identified from the 3<sup>rd</sup>, 4<sup>th</sup>, and 5<sup>th</sup> intercostal spaces with thoracic spinal roots (T3, T4, T5) harvested for transfer.

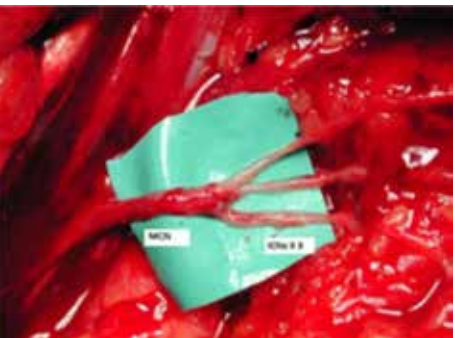

Figure 4B: Three ICNs were transferred to the MCN by using 10-0 Nylon coaptation suture.

achieving good results. (Figure 4A, 4B) The techniques of ICNs direct coaptation suture with the MCN should be emphasized in two aspects. The first aspect is the tension-free nerve coaptation suture to ensure proper nerve regeneration after trauma. The second aspect is the concomitant reconstruction of motor and sensory function of the MCN by accurate location of the motor and sensory components of MCN and ICNs. The MCN is the terminal branch of lateral cord. The motor component of the MCN is located in the central and upper zones of cross-section cut, while the sensory component of the MCN is located in the peripheral and lower zones of the MCN. Therefore, we recommend transfer of 2 or 3 ICNs to the MCN by using motor nerves of ICNs direct coaptation suture with central and upper portions of the MCN cut-surface. And then, the superficial lateral sensory branches of ICNs should be sutured onto the peripheral and lower portions of the MCN cut-surface.<sup>10</sup> The M3 elbow flexion is usually achieved 12 to 18 months after surgery. The continuous improvement of M3 to M4 elbow flexion depends on



the intensity of rehabilitation and the compliance of patients. An adequate physical therapy program may allow patients to achieve M4 elbow flexion in 3 years after surgery. During the first 2 years after the operation, biceps function synchronizes with the respiratory cycle. In the 3rd postoperative year, voluntary biceps control is usually obtained, but involuntary elbow contraction while coughing and sneezing still persists. Sensory recovery of the MCN territory is also attained. During the first 1 to 2 years, sensation is perceived only in the chest. Later, some sensations are recovered on the radial surface of the forearm 2 to 3 years after surgery. The reported successful rate (M3 elbow flexion) of ICNs neurotization on MCN ranges from 36% to 65%. Due to the complexity of harvesting ICNs which is a time consuming procedure, most surgeons prefer Oberlin's or Mackinnon's methods for reconstructing elbow function instead of ICNs, in upper arm type BPI.<sup>9,12,45</sup>

#### 4. SAN-sural nerve graft-MCN, or PN-sural nerve graft-MCN:

The use of the spinal accessory nerve (SAN) or phrenic nerve (PN) transfer, by a free sural nerve graft bridging interposition, and neurotization of the MCN had been reported to have acceptable muscle power recovery of elbow flexion (range from 50% to 80% M3 elbow flexion).<sup>1,3,10,12,15,18,27,34,48,52</sup> A prospective randomized comparison study was conducted to investigate the elbow power recovery by SAN-nerve graft-MCN and by ICNs-MCN respectively. Their results showed

that for the SAN-nerve graft-MCN technique, the successful rate (M3 elbow flexion) was 83%, while the ICNs neurotization on MCN had only 64% successful rate.<sup>52</sup> There are two advantages of using the SAN and PN as motor neurotizers for elbow flexion. First, the SAN and PN contain more motor myelinated fibers than 3 ICNs. Second, the functional relationship between shoulder abduction / respiration and elbow flexion leads to easier postoperative rehabilitation.<sup>34</sup> However, the SAN-sural nerve graft-MCN and PN-sural nerve graft-MCN methods are purely for motor recovery of elbow. No sensory recovery was achieved by these 2 techniques. The disadvantages of using the SAN transfer are the need for harvesting sural nerve graft by an additional incision, and the sacrifice of a potential neurotizer for a dysfunctional supra-scapular nerve (for shoulder function). The disadvantages of the PN transfer are similar to the SAN, with additional drawbacks of immediate postoperative respiration distress, and long term complications of decreased vital capacity of lung function. In recent years, most surgeons prefer to employ Oberlin's or Mackinnon's methods to reconstruct elbow flexion in upper arm type BPI, instead of using the SAN or PN as an elbow neurotizer.<sup>3,9,10,12,14,16,17,20,21,51</sup>

#### 5. Medial pectoral Nerve (MPN) to MCN transfer.

The direct coaptation suture of the MPN with the MCN is an intra-plexus neurotization method.<sup>3,12,18,53</sup> The reported data showed that 80% of

patients achieved M3 elbow flexion, while 60% of patients gained MRC grade 4 motor recovery of elbow flexion.<sup>4</sup> With the additional C5 or C6 nerve direct repair, the surgical results of elbow flexion might even reach 100%.<sup>4</sup> The disadvantages of using the MPN as neurotizer are the short length of the donor nerve (MPN), and the long distance between the MPN and MCN which makes its reach to the motor branch of the MCN difficult.<sup>53</sup>

#### 6. Latissimus dorsi (LD) flap / Gracilis free functioning muscle transfer (FFMT) to elbow (biceps insertion).

These two methods are reserved as salvage procedures for upper arm type BPI reconstruction. In upper arm type C5-C6 injury BPI, when the above mentioned neurotizations failed, the LD flap anterior transfer to biceps tendon insertion (so-called bipolar transfer) is an alternative salvage procedure for restoring elbow flexion. The successful rate of this LD pedicle functioning muscle transfer is acceptable (80% M3 elbow flexion).<sup>5</sup> However, in C5-6-7 complete injury, the thoracodorsal nerve supplying the motor function of LD muscle is mostly damaged. Therefore, the gracilis FFMT should be employed for reconstructing elbow flexion.<sup>5,12,40,41</sup> The proximal gracilis is sutured onto the distal clavicle or coracoid process, while the distal gracilis tendon is sutured onto the biceps insertion site. The motor nerve (obturator nerve) of this FFMT may be microscurgically sutured with ICNs or SAN as neurotizers. With adequate planning of microsurgery and proper

postoperative rehabilitation, the elbow flexion after gracilis FFMT may be recovered around 75% to 80% M3 elbow flexion.<sup>5,40,41</sup>

#### Nerve / tendon transfer options for shoulder abduction / elevation / external rotation in upper arm type BPI

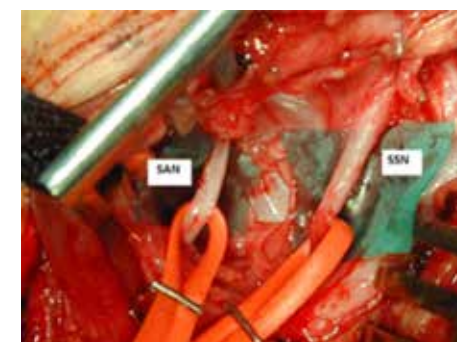
There are several nerve / tendon transfer options for the reconstruction of shoulder abduction / elevation / external rotation in upper arm type BPI. The donor nerves applied for BPI shoulder function neurotization include: spinal accessory nerve (SAN), triceps branch of radial nerve (TbRN), medial pectoral nerve (MPN), phrenic nerve (PN), and intercostal nerve (ICN). The recipient nerves are the suprascapular nerve (SSN) and axillary nerve (AXN). The following six techniques are the most commonly used methods.

##### 1. Spinal accessory nerve (SAN) to suprascapular nerve (SSN) transfer.

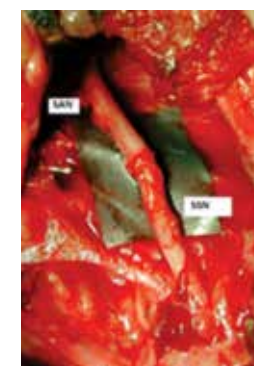The SAN to SSN transfer is an older yet reliable option for restoration of shoulder abduction and glenohumeral stability.<sup>3,9,31,42,46,48</sup> The SAN is the XI cranial nerve which serves to innervate the trapezius muscle distally in its course. Originally this transfer required a large supraclavicular Millesi incision for assessment, however recent advances in technique have permitted much smaller and more aesthetic incisions.<sup>2,23,24</sup> This transfer has been successful largely due to its consistent anatomy, and close proximity to the donor nerve which avoids the need for an interpositional

nerve graft.<sup>2</sup> (Figure 5A, 5B). Songcharoen and Spinner reported a good outcome in 74% of their 577 SAN-SSN transfers.<sup>3</sup> Terzis and Kostas also reported their good and excellent clinical shoulder recovery outcomes in 79% of their 118 patients receiving SAN-SSN transfers.<sup>42</sup>

##### 2. Triceps branch of radial nerve (TbRN) to axillary nerve (AXN)



**Figure 5A: Spinal accessory nerve (SAN) and suprascapular nerve (SSN) were identified through the anterior supra-clavicular approach.**



**Figure 5B: Neurotization was performed by SAN to SSN transfer, with 9-0 Nylon coaptation suture.**

##### transfer.

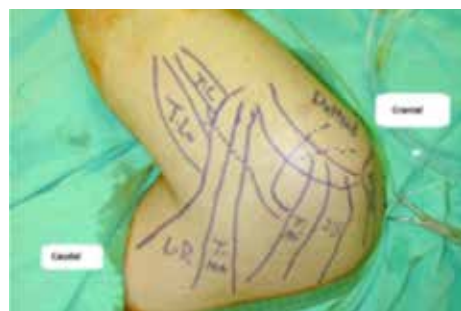Transferring the radial nerve to the AXN was originally described in 1948 by Alexander Lurje from Russia.<sup>2,30</sup> However, his initial description was through an anterior approach which was difficult for surgical dissection, and also had the drawback of requiring an interpositional nerve graft. This

transfer was essentially abandoned for other transfer options in 2003 when Leechavengvongs from Thailand described the posterior approach.<sup>2,12,47</sup> The Lerdsin group (Leechavengvongs et al. in Thailand) performed a single longitudinal incision to approach the anterior branch (mostly motor fibers) of the AXN in the quadrilateral space. Subsequently the radial nerve is dissected in the triangular interval just distal to the teres major. The motor nerve to the long head of the triceps is identified and dissected at this point. The TbRN was then coapted by suture to the anterior branch of the AXN directly for restoring the motor function of deltoid muscle. (Figure 6A, 6B, 6C) The posterior approach was revolutionary because of the ease of dissection, no interpositional graft is required, and it places the donor nerve close to the motor endplate of the recipient.<sup>47</sup> This type of nerve transfer may improve the shoulder stability and elevation / abduction because this method is performed in addition to the SAN to SSN transfer.<sup>2,9,12,15,16,46,47</sup> Leechavengvongs reported that 7 of 7 patients achieved deltoid function against gravity with a mean of 124 degrees of shoulder abduction. There was no shoulder subluxation or loss of triceps function in their series.<sup>47</sup> Bertelli et al. also reported their combined SAN-SSN and TbRN-AXN methods for upper arm type BPI reconstruction in which all patients achieved active shoulder abduction / elevation and external rotation. Abduction recovery averaged 92 degrees and external rotation averaged 93 degrees in their patients.<sup>14</sup> In

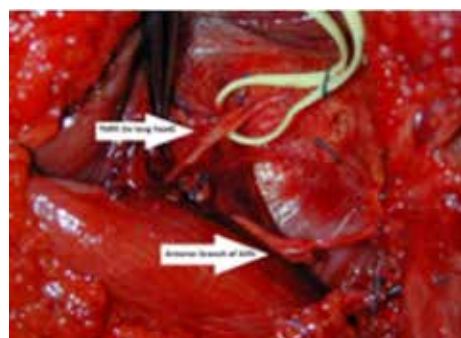


addition to the posterior approach, Bertelli et al. also described a new approach for TbRN transfer to AXN by an anterior approach (axillary access) with excellent shoulder recovery (3 in 3 patients achieved M4 deltoid function and shoulder abduction).<sup>54</sup>

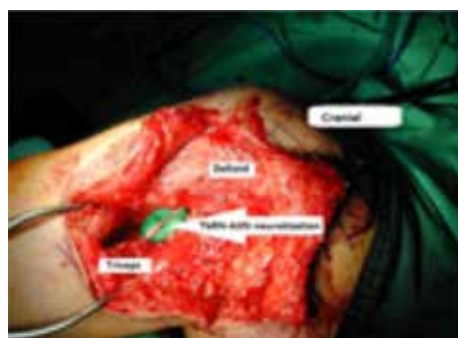The advantage of this method is the ease of dissection through the anterior approach in one surgical position. The combined SAN-SSN and TbRN-AXN method is currently the most popular technique for shoulder reconstruction in patients with C5-C6 injured upper



**Figure 6A: Skin marks for Triceps branch of radial nerve (TbRN) to axillary nerve (AXN) transfer surgery. IS (infra-spinatus muscle); Tmi (Teres minor), TMA (Teres major), LD (Latissimus dorsi), TL (Triceps long head), TLo (Triceps lower head)**



**Figure 6B: TbRN (to the long head of triceps) and anterior branch of AXN can be easily identified in the quadrilateral space.**



**Figure 6C: Neurotization with TbRN transfer to anterior motor branch of AXN was performed by using 9-0 Nylon coaptation suture.**

arm type BPI.

### 3. Intercostal nerves (ICNs) to axillary nerve (AXN) transfer.

Recently many surgeons have recommended simultaneous nerve transfer to both the SSN and AXN for achieving better shoulder function.

<sup>2,9,12,15,16,46,47</sup> Although the SAN to SSN combined with the TbRN to AXN double neurotization had been reported to have satisfactory results in shoulder recovery, this model of double neurotization could not be applied in C5 through C7 root avulsion injuries. In C5,C6 combined with C7 damaged BPI, the TbRN could not be used as a neurotizer because the main component of the radial nerve comes from the C7 root. There are some donor nerves that can be used for transferring to the AXN, such as PN, SAN, and MPN.<sup>10,18,53</sup> However, the clinical results of PN-AXN, SAN-AXN and MPN-AXN neurotization procedures were unsatisfactory.

<sup>10,18,53,55</sup> The Lerdsin group in Thailand developed a method which uses the posterior approach to dissect the 4<sup>th</sup> and 5<sup>th</sup> ICNs which are then

transferred to the anterior branch of the AXN. The patient is put in supine position with a sandbag underneath the affected upper limb. A curved incision was made along the 5<sup>th</sup> rib. To ensure an adequate length of the ICNs, the 4<sup>th</sup> and 5<sup>th</sup> ICNs were dissected as far posteriorly as possible. Just anterior to the mid-axillary line, the sensory branches of the ICNs were identified and cut to enhance the mobility of the ICNs. Then the shoulder was rolled anteriorly. A second incision was made along the posterior border of deltoid muscle, and the quadrilateral space was explored. The anterior branch of the AXN was identified, and a subcutaneous tunnel was made between the first and the second incisions. The 4<sup>th</sup> and 5<sup>th</sup> ICNs were passed through the subcutaneous tunnel and the direct coaptation sutured with the anterior branch of the AXN. Good shoulder function with M4 deltoid recovery was obtained in both of their 2 patients.<sup>55</sup> Because this is a combined procedure with the SAN-SSN and Oberlin procedures, care must be taken to ensure adequate length of ICNs transfer to the AXN which allows fully passive shoulder abduction motion without tension on the nerve coaptation site.

### 4. Phrenic nerve (PN) to suprascapular nerve (SSN) transfer.

PN transfer to the SSN could be performed as a direct neurotization method for shoulder reconstruction without interpositional nerve graft. It has been frequently used by many surgeons in Asia, but rarely been used

in the Occidental countries because of concern regarding decreased pulmonary capacity after the sacrifice of PN.<sup>10</sup> Based on Gu's study, the pulmonary capacity decreased because of limited excursion and elevation of the diaphragm for 1 year, but then recovered to normal value by 2 years postoperatively.<sup>34</sup> Chuang also frequently used the PN as neurotizer for adult patients without significant respiratory problems.<sup>10</sup> PN transfer to the SSN has similar satisfactory results (around 70% M3 shoulder abduction) as SAN-SSN transfer, because the PN has abundant motor fibers. However, patients with smoking, poor pulmonary function, associated chest trauma, and morbid obesity are not ideal candidates for PN harvesting.

### 5. Nerve transfer to serratus anterior muscle using the thoracodorsal nerve for winged scapula.

Serratus anterior muscle is one of the major scapula stabilizers that is critical in maintaining proper scapulohumeral rhythm during glenohumeral movement, particular in shoulder and arm elevation. Patients with serratus anterior palsy in BPI may present with pain, weakness, limitation of shoulder elevation, and scapular winging with medial translation of the scapula, rotation of the inferior angle toward the midline, and prominence of the vertebral border. This winging becomes more prominent as the patient attempts to push forward against resistance. The Lerdsin group in Thailand found that 7 of 15 patients in their series who received SAN-SSN,

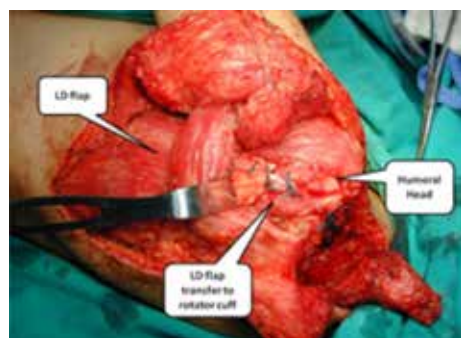
TbRN-AXN, and Oberlin's method for C5-C6 BPI, were observed to have winging of the scapula, paralysis of the serratus anterior muscle, and painful disability when elevating their shoulder.<sup>16</sup> Subsequently, the Lerdsin group developed their method of reconstruction for serratus anterior by transferring the thoracodorsal nerve to the long thoracic nerve.<sup>56</sup> They performed a 12 cm longitudinal incision along the posterior aspect of the axilla which was around the anterior border of the latissimus dorsi muscle. Retraction of the latissimus dorsi allowed exposure of the thoracodorsal and long thoracic nerves. Two thoracodorsal nerve branches (medial and lateral branch) were identified, and the branch with stronger muscle contraction during nerve stimulation was chosen as the neurotizer. The long thoracic nerve was exposed along the chest wall and divided as proximal as possible to ensure that the majority of the serratus anterior muscle could be innervated. This proximal dissection of long thoracic nerve also provided enough length of nerve for coaptation suture without tension. All patients in their series obtained good shoulder functional recovery without any donor site complication from harvesting one branch of the thoracodorsal nerve.<sup>56</sup> This additional neurotization procedure (thoracodorsal nerve transfer to long thoracic nerve) may offer better shoulder function than the combined SAN-SSN and TbRN-AXN techniques. This method is especially beneficial in patients who place high demands on their shoulders.

### 6. Trapezius muscle transfer to shoulder girdle muscles.

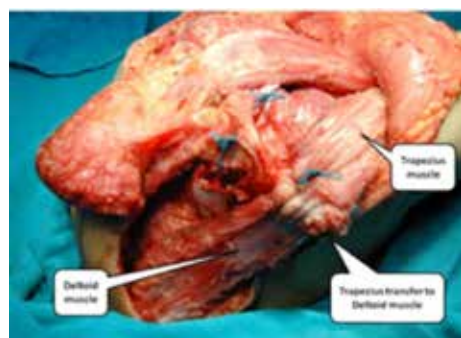
Persistent shoulder paralysis after BPI is a difficult and challenging problem to treat. Although various methods of neurotizations have been described in the literature, some BPI patients still suffer from shoulder dysfunction either after nerve transfer reconstruction failure or delayed / neglected treatment. The resulting shoulder muscle weakness leads to a "hand-on-belly" internally rotated position that limits positioning of the hand anterior to the coronal plane with elbow flexion, and painful glenohumeral subluxation. In these instances, upper trapezius transfer has been attempted to restore shoulder abduction with variable results reported.<sup>43,44</sup> A combined procedure with latissimus dorsi muscle transfer to the greater tuberosity to reconstruct the rotator cuff, and trapezius transfer to deltoid muscle had been performed for simultaneous reconstruction of shoulder abduction / elevation and external rotation, but the outcomes could achieve only around 75 degrees of shoulder abduction<sup>5,23,25,43,44</sup> (Figure 7A, 7B). A novel technique of transferring middle and lower segments of the trapezius muscle, extended with a tendon allograft, to restore the external rotation of shoulder function was reported with good to satisfactory results.<sup>44</sup>

**Reconstructions for wrist / hand extension function in upper arm type (C5, C6 with C7 injuries) BPI**  
In upper arm type BPI, many C7





**Figure 7A: Delay shoulder reconstruction with LD (latissimus dorsi) transfer to anchor at greater tuberosity of humeral head that served as the rotator cuff function.**



**Figure 7B: Trapezius to Deltoid muscle transfer was performed, in combination with the LD-rotator cuff transfer for reconstructing the shoulder abduction / elevation, and external rotation.**

injuries are found in combination with C5 and C6 ruptures. Patients are usually presenting with loss of shoulder abduction / elevation function and elbow flexion, together with loss of wrist and finger dorsiflexion. The reconstructions for this type of injury may include direct repair, nerve graft, and neurotization as well. However, although the reported results of good shoulder and elbow function could be obtained after various neurotization methods, the results of C7 functional recovery were

not satisfactory. This is because many of the C7 innervated muscles are located at the forearm level (except the triceps muscles which are located in the arm level), and hence the re-innervation occurs quite slowly before reaching the target neuromuscular junctions. The functional needs of the hand after C7 injury (radial nerve palsy) are (1) wrist extension, (2) finger and thumb extension, and (3) thumb proximal stability.<sup>5</sup> For wrist extension, the PT (pronator teres) muscle can be transferred to the ECRB (extensor carpi radialis brevis) musculo-tendonous junction, if the motor function of PT is recovered after BPI reconstruction. For finger extension, the traditional procedure uses the FCU (flexor carpi ulnaris) transfer to the EDC (extensor digitorum communis) tendons, and PL (palmaris longus) transfer to EPL (extensor pollicis longus) tendon. This

full FCU transfer often results in a slight radial deviation of the hand at the wrist. If the patient has significant radial deviation at the wrist, the insertion of the ECRL (extensor carpi radialis longus) should be transferred to the ECU (extensor carpi ulnaris), or the FCU tendon transfer should not be done. Fingers and thumb extension can also be reconstructed by transferring the FDS (flexor digitorum superficialis) tendons of the long and ring finger. The ring FDS is attached to the EDC, similar to the FCU transfer, and the long FDS is attached to the EPL. The other alternative method is transferring the PL to EPL, and transferring the FCR (flexor carpi radialis) to the EDC. For the proximal stability of the thumb, the EPB (extensor pollicis brevis) is mobilized from the 1st dorsal compartment and tenodesed to the PL. However, when

PL has been used for thumb extension reconstruction, an alternative method is using the split FCR, tenodesing it to both APL (abductor pollicis longus) and EPL tendons.

#### Surgical Treatment for Pain

Adequate pain management is mandatory for BPI patients' quality of life. The disability of upper limb and intractable pain usually results in limitation of social activities and employment. Pain occurs frequently after injury, starting usually within weeks of the trauma event and then becomes chronic. Sometimes, but not always, the pain may be relieved by medications, including NSAIDs (Non-steroid anti-inflammatory drugs), narcotics and anticonvulsants. However, many BPI patients suffering from intractable pain that cannot be effectively relieved by pain killers should be considered as candidates for surgery. The surgical treatment for pain relief may be performed by the method of DREZ (Dorsal root entry zone) rhizotomy. The authors performed thermocoagulation (rhizotomy) at the DREZ for intractable pain after BPI in 60 cases.<sup>57</sup> Forty cases were under regular follow-up for 5 to 18 years. In the early postoperative stage, the pain relief was excellent or good in 32 cases (80%). The pain relief rate dropped to 60% at 5 years follow-up, and only 50% of patients had excellent or good pain-relief outcomes in 10 years follow-up.<sup>57</sup> There is still more work to be done in treating pain in BPI patients.

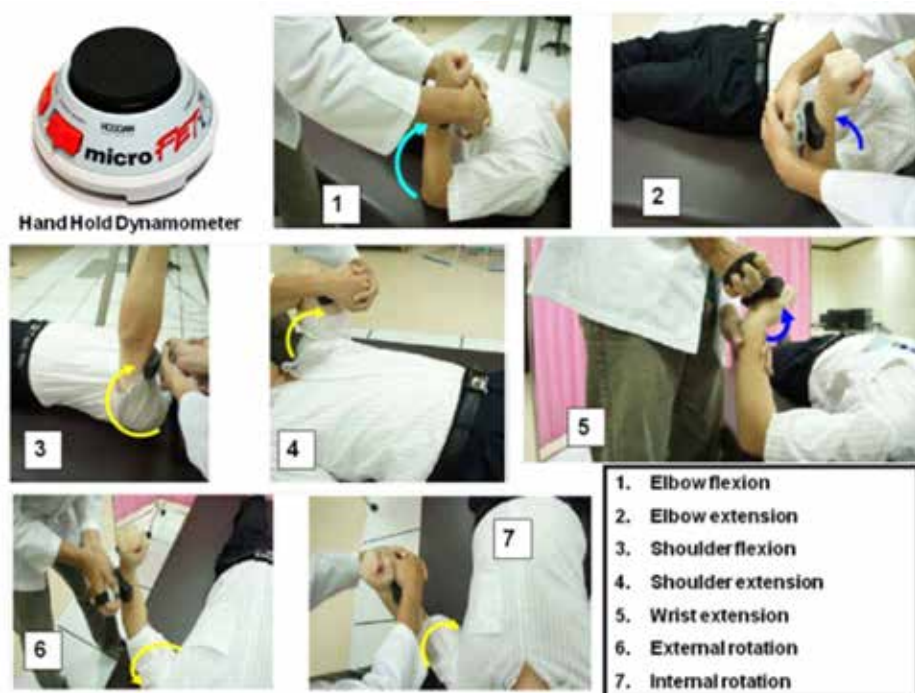#### Rehabilitation and objective assessment of the motor recovery after surgery for BPI

Adequate scheduled rehabilitation is the key to satisfactory clinical outcomes after BPI surgery. The postoperative custom made protecting brace should be tailored, and each patient's rehabilitation program has to be unique for each injury. The physical therapy with a passive range of motion and slow-pulse electrical stimulation should be started immediately after proper surgical wound healing. Home electrical stimulation was provided for all of the patients with a portable slow pulse stimulation device that the patient was instructed to use for 4 to 6 hours per day for a minimum of 2 years, or until antigravity motor function (M3) occurred.<sup>513</sup> Significant recovery after neurotizations can take more than 9 to 18 months for functional improvement. The rehabilitation programs also include hand grip-power training (for elbow neurotization), trapezius muscle training (for SAN-SSN), respiration training (for ICN-AXN, and PN-SSN), and repeated elbow extension training (for TbRN-AXN) as well. These physical therapy maneuvers may enhance timely motor recovery. The Medical Research Council (MRC) grading system, which ranges from grade M0 (no contraction) to M5 (normal), is a quick and easy tool to evaluate muscle strength recovery after BPI surgery. However, the simplified MRC grading system may result in the underestimation of muscle strength improvement. The authors have developed an

objective assessment method, which employs the use of HHD (Hand-held dynamometer) for more detailed and scientific evaluations for the functional outcomes of BPI patients during the rehabilitation program after surgery.<sup>57,58</sup> This HHD evaluation method has been reported to have excellent reliability for measuring the muscle strength recovery after neurotization procedures for BPI<sup>57</sup> (Figure 8). Based on the objective assessment data by HHD evaluations, neurotization in C5-C6 BPI patients had significant better elbow, shoulder, and hand grip functions than C5-6-7 BPI patients, which were not detected by simplified MRC grading.<sup>58</sup>

#### Summary

1. The current trends in surgical treatments for upper arm type BPI is close-target neurotization by either intra-plexus neurotization or extra-plexus neurotization methods. The goals are to achieve effective elbow flexion, shoulder abduction / elevation, and shoulder external rotation.
2. Primary exploration of the injury site is still needed for better understanding of the extent of trauma, and for the possibility of identifying available proximal nerve root stumps for repairing / grafting.
3. The double neurotization technique for elbow flexion (Mackinnon's method or the Oberlin II method) may obtain faster and more effective muscle power recovery for elbow flexion than the Oberlin I, ICNs-MCN,



**Figure 8: The clinical evaluation of shoulder and elbow muscle power recovery in BPI patients by using the Hand Hold Dynamometer (HHD).**



and SAN-sural nerve graft -MCN methods.

4. Shoulder function may be reconstructed by either single neurotization (such as SAN-SSN or PN-SSN), double neurotization (such as SAN-SSN and TbRN-AXN, or SAN-SSN and ICNs-AXN), or triple neurotization (such as SAN-SSN, TbRN-AXN, and thoracodorsal nerve to long thoracic nerve transfer). The complexity of shoulder functional recovery suggests that a greater number of neurotization procedures have better shoulder outcomes than with just a single neurotization method.
5. Combined neurotization procedures for simultaneous elbow and shoulder reconstruction, such as triple nerve transfers (SAN-SSN, TbRN-AXN, Oberlin I or II method) is the current trend of BPI surgery. This "bundled" transfer when performed prior to 6 months following injury in patients under 40 years of age has achieved excellent results.
6. Muscle / tendon transfers may be reserved for BPI salvage procedures, or for C7 deficit functional reconstruction.
7. Effective pain relief and well-scheduled rehabilitation programs improve the quality of life in BPI patients. Objective assessments of the muscle strength postoperatively by HHD may allow better awareness of the real situation in the BPI patient's recovery.

## References

1. Narakas AO. Neurotization in the treatment for brachial plexus injuries. In: Gelberman RH. Editor. Operative nerve repair and reconstruction. Philadelphia: JB Lippincott; 1991. p. 1329-58
2. Schessler MJ, McClellan WT. The role of nerve transfers for C5-C6 brachial plexus injury in adults. West Virginia State Medical Journal 2010; 106(1): 12-17.
3. Soncharoen P, Wongtrakul S, Spinner R. Brachial plexus injuries in the adult. Nerve transfers: The Siriraj hospital experience. Hand Clinic 2005; Feb;21(1): 83-9.
4. Sulaiman OAR, Kim DD, Burkett C, Kline DG. Nerve transfer surgery for adult brachial plexus injury: A 10-year experience at Louisiana State University. Neurosurgery 2009; Oct; 65(4): 55-62.
5. Tu YK, Chung KC. Surgical procedures for recovery of hand function. Practical management of pediatric and adult brachial plexus palsies. In: Chung KC, Yang LJS, McGillicuddy JE, editors. Saunders Elsevier; 2012. p 271-300.
6. Bertelli JA, Ghizoni MF. Pain after avulsion injuries and complete palsy of the brachial plexus: The possible role of nonavulsed roots in pain generation. Neurosurgery 2008; May; 62(5): 1104-14.
7. Chen HJ, Tu YK. Long term follow up results of dorsal root entry zone lesions for intractable pain after brachial plexus avulsion injuries. Acta Neurochir 2006; 99: 73-75.
8. Furey MJ, Midha R, Xu QG,

Belkas J, Gordon T. Prolonged target deprivation reduces the capacity of injured motoneurons to regenerate. Neurosurgery 2007; 60: 723-33.

9. Terzis JK, Kostopoulos VK. The surgical treatment of brachial plexus injuries in adults. Plast Reconstr Surg 2007; 119: 73-92.
10. Chuang DCC. Nerve transfers in adult brachial plexus injuries: my method. Hand Clin 2005; 21: 71-82.
11. Sammer DM, Kircher MF, Bishop AT, Spinner RJ, Shin AY. Hemi-contralateral C7 transfer in traumatic brachial plexus injuries: outcome and complications. J Bone Joint Surg Am 2012;94:131-137.
12. Shin AY, Spinner RJ, Steinmann SP, Bishop AT. Adult traumatic brachial plexus injuries. J Am Acad Orthop Surg 2005; 13(6): 382-396.
13. Tu YK, Tsai YJ, Chang CH, Su FC, Hsiao CK, Tan JSW. Surgical treatment for total root avulsion type brachial plexus injuries by neurotization: A prospective comparison study between total and hemicontralateral C7 nerve root transfer. Microsurgery 2014;34: 91-101.
14. Bertelli JA, Florianopolis SC. Ghizoni MF. Reconstruction of C5 and C6 brachial plexus avulsion injury by multiple nerve transfers: spinal accessory to suprascapular, ulnar fascicles to biceps branch, and triceps long or lateral head branch to axillary nerve. J Hand Surg 2004; 29(A):131-139.
15. Garg R, Merrell GA, Hillstrom HJ,

Wolfe SW. Comparison of nerve transfers and nerve grafting for traumatic upper plexus palsy: a systematic review and analysis. J Bone Joint Surg Am. 2011; 93(9):819-829.

16. Leechavengvongs S, Witoonchart K, Uerpaiojkit C, Thuvasethakul P, Malungpaishrope K. Combined Nerve Transfers for C5 and C6 Brachial Plexus Avulsion Injury. J Hand Surg. 2006; 31(A):183-189.
17. Mackinnon SE, Colbert SH. Nerve transfers in the hand and upper extremity surgery. Tech Hand Upp Extrem Surg. 2008; 12(1):20-33.
18. Merrell GA, Barrie KA, Katz DL, Wolfe SW. Results of nerve transfer techniques for restoration of shoulder and elbow function in the context of a meta-analysis of the English literature. J Hand Surg 2001; 26(A): 303-14.
19. Oberlin C, Beal D, Leechavengvongs S, Salon A, Dauge MC, Sarcy JJ. Nerve transfer to biceps muscle using a part of ulnar nerve for C5-C6 avulsion of the brachial plexus: anatomical study and report of 4 cases. J Hand Surg 1994; 19(A): 232-237
20. Teboul F, Kakkar R, Ameer N, Beaulieu JY, Oberlin C. Transfer of fascicles from the ulnar nerve to the nerve to biceps in the treatment of upper brachial plexus palsy. J Bone Joint Surg Am 2004; 86(7): 1485-90.
21. Tung TH, Mackinnon SE. Nerve Transfers: Indications, Techniques, and Outcomes. J Hand Surg. 2010; 35(A):332-341.

22. Aydn A, et al. Three-thousand-year-old written reference to a description of what might be the earliest brachial plexus injuries in the Iliad of Homer. Plast Reconstr Surg 2004; Oct; 114(5):1352-3.

23. Millesi H. Surgical management of brachial plexus injuries. J Hand Surg 1977; 2 (A): 367-79.
24. Millesi H. Brachial plexus injuries: nerve grafting. Clin Orthop 1988;237:36-42
25. Narakas AO. Brachial plexus surgery. Orthop Clin North Am 1981;12:303-323
26. Sedel L. Repair of severe traction lesions of the brachial plexus. Clin Orthop 1988;237: 62-6
27. Narakas AO, Hentz VR. Neurotization in Brachial plexus injuries: Indication and results. Clin Orthop 1988;237:43-56
28. Kennedy, Robert. On the restoration of coordinated movements after nerve-crossing, with interchange of function of the cerebral cortical centers. Philosophical transactions of the Royal Society of London. Series B. Containing papers of a Biological Character. 1901; 194: 127-182.
29. Langley JN, Anderson HK. The union of different kinds of nerve fibers. J Physiol 1904 Aug; 31(5):365-91.
30. Lurje A. Concerning surgical treatment of traumatic injury of the upper division of the brachial plexus. Annals of Surgery 1948 Feb; 127(2):317-26.
31. Weber R, MacKinnon S. Nerve transfers in the upper extremity. J Hand Surg 2004;4(A):200-13.

32. Bertelli JA, Ghizoni MF. Results of grafting the anterior and posterior divisions of the upper trunk in complete palsies of the brachial plexus. J Hand Surg 2008; 33(A):1529-1540.

33. Ochiai N, Nagano A, Sugioka H, Hara T. Nerve grafting in brachial plexus injury. Results of free grafts in 90 patients. J Bone Joint Surg 1996; 78(B): 754-8.
34. Gu YD, Ma MK. Use of the phrenic nerve for brachial plexus reconstruction. Clin Orthop 1996;323:119-121.
35. Gu YD, Zhang GM, Chen DS, Yan JG, Cheng XM, Chen L. Seventh cervical root transfer from the contralateral healthy side for treatment of brachial plexus root avulsion. J Hand Surg 1992; 17(B):518-521.
36. Nagano A, Ochiai N, Okinaga S. Restoration of elbow flexion in root lesions of brachial plexus injuries. J Hand Surg 1992; 17(A):815-21.
37. Htut M, Misra VP, Anand P, Birch R, Carlstedt T. Motor recovery and the breathing arm after brachial plexus surgical repairs, including re-implantation of avulsed spinal roots into the spinal cord. J Hand Surg 2007; 32(E): 170-8
38. Carlstedt T, Grane T, Hallin RG, et al. Return of function after spinal cord implantation of avulsed spinal nerve roots. Lancet 1995, 18346; 1323-5.
39. Dvali L, MacKinnon S. Nerve repair, grafting, and nerve transfer. Clin Plast Surg 2003; 30(2):203-21.
40. Doi K, Muramatsu K, Hattori Y, et al. Restoration of prehension with

- the double free muscle technique following complete avulsion of the brachial plexus. *J Bone Joint Surg* 2000; 82(A): 652-666.
41. Doi K. Palliative surgery: free muscle transfers. In: *Brachial plexus injuries*. ed. by Alain Gilbert, Martin Dunitz, London, 2001; pp 137-147.
  42. Terzis JK, Kostas I. Suprascapular nerve reconstruction in 118 cases of adult posttraumatic brachial plexus. *Plast Reconstr Surg* 2006; 117(2): 613-29.
  43. Aziz W, Singer RM, Wolff TW. Transfer of the trapezius for flail shoulder after brachial plexus injury. *J Bone Joint Surg* 1990; 72(B): 701-4.
  44. Elhassan B, Bishop AT, Shin AY. Trapezius transfer to restore external rotation in a patient with a brachial plexus injury. *J Bone Joint Surg* 2009; 91(A): 939-44.
  45. Coulet B, Boretto JG, Lazerges C, Chammas M. A comparison of intercostals and partial ulnar nerve transfers in restoring elbow flexion following upper brachial plexus injury (C5-C6±C7). *J Hand Surg* 2010; 35(A): 1297-1303.
  46. Terzis JK, Kostas I, Soucacos PN. Restoration of shoulder function with nerve transfers in traumatic brachial plexus palsy patients. *Microsurgery* 2006; 26: 316-24.
  47. Leechavengvongs S, Witoonchart K, Uerpaiojkit C, Thuvasethakul P. Nerve transfer to deltoid muscle using the nerve to the long head of the triceps, Part II: A report of 7 cases. *J Hand Surg.* 2003; 28(A): 633-38.
  48. Songcharoen P. Management of brachial plexus injury in adults. *Scand J Surg.* 2008; 97:371-323.
  49. Leechavengvongs S, Witoonchart K, Uerpaiojkit C. Nerve transfer to biceps muscle using a part of the ulnar nerve in brachial plexus injury (upper arm type): a report of 32 cases. *J Hand Surg.* 1998; 23(A):711-6.
  50. Liverneaux PA, Diaz LC, Beaulieu JY, Durand S, Oberlin C. Preliminary results of double nerve transfer to restore elbow flexion in upper type brachial plexus palsies. *Plast Reconstr Surg* 2006; 117:915-9.
  51. Mackinnon SE, Novak CB, et al. Results of reinnervation of the biceps and brachialis muscles with a double fascicular transfer for elbow flexion. *J Hand Surg* 2005; 30(A): 978-85.
  52. Waikukul S, Wongtragul S, Vanadurongwan V. restoration of elbow flexion in brachial plexus avulsion injury: Comparing spinal accessory nerve transfer with intercostal nerve transfer. *J Hand Surg* 1999; 24(A): 571-7.
  53. Samardzic M, Grujicic D, Rasulic L, Bacetic D. Transfer of the medial pectoral nerve: myth or reality? *Neurosurgery* 2002; 50:1277-82.
  54. Bertelli JA, Kechele PR, Santos MA, Duarte H, Ghizoni MF. Axillary nerve repair by triceps motor branch transfer through an axillary access: anatomical basis and clinical results. *J Neurosurg.* 2007; 107:370-377.
  55. Malungpaishorpe K, Leechavengvongs S, Uerpaiojkit C, Witoonchart K, et al. Nerve transfer to deltoid muscle using the intercostal nerves through the posterior approach: an anatomical study and two cases report. *J Hand Surg* 2007; 32(A): 218-24.
  56. Uerpaiojkit C, Leechavengvongs S, Witoonchart K, Malungpaishorpe K, Raksakulkiat R. Nerve transfer to serratus anterior muscle using the thoracodorsal nerve for winged scapula in C5 and C6 brachial plexus root avulsions. *J Hand Surg.* 2009; 34(A): 74-78.
  57. Tsai YJ, Tu YK, Hsiao CK, Su FC. Within-session reliability and smallest real difference of muscle strength following nerve transfers in patients with brachial plexus injuries. *J Hand Surg.* 2015; 40(A): 1196-1201.
  58. Tsai YJ, Su FC, Hsiao CK, Tu YK. Comparison of objective muscle strength in C5-C6 and C5-6-7 brachial plexus injury patients after double nerve transfer. *Microsurgery* 2014; 35: 107-114.

# 3D Printing for Customized Wrist Splints: past, present and future



*Dr Abby M. Paterson<sup>(1)</sup>*



*Ella Donnison<sup>(2)</sup>*



*Professor Richard J. Bibb<sup>(1)</sup>*

1. Loughborough Design School, Loughborough University, LE11 3TU.

2. Pulvertaft Hand Unit, Royal Derby Hospital, Derby, UK

## Introduction:

A splint is a device used for support or immobilization of a limb. Splints have been designed and made from many different materials throughout history, from leaves, reed, and bamboo in ancient Egyptian times, to screw-driven metal splints and low temperature thermoplastics introduced by European armour makers in the 1960's. Factors such as polio, war, technological and surgical advances, education, research, government initiatives and professional organizations have all played important roles in influencing the development

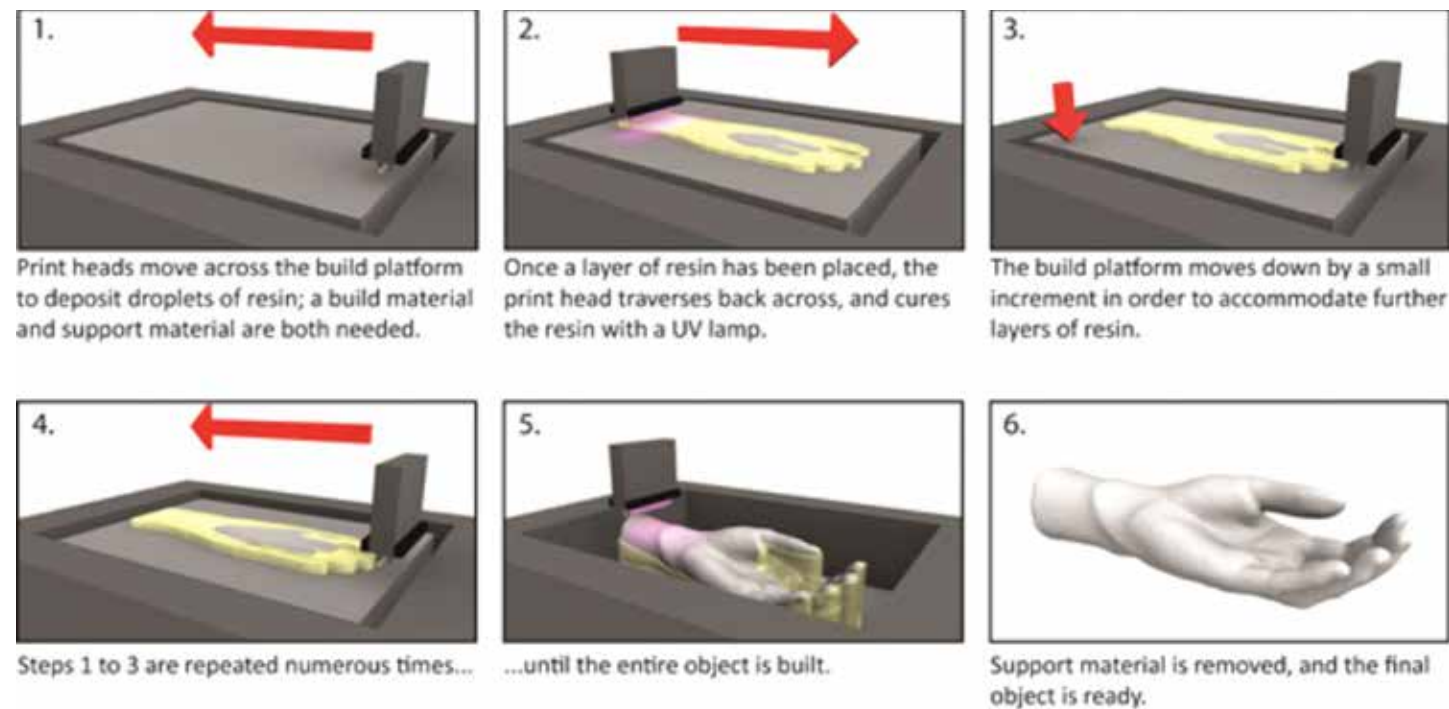
of splint design and fabrication (Fess, 2002). However, there may be another emerging approach for splint production; 3D Printing.

## What is 3D printing?

More formally known as Additive Manufacture (AM), 3D Printing is defined as 'the process of joining materials to make objects from 3D model data, usually layer upon layer' (American Society for Testing and Materials International, 2012). AM has gained significant public interest in recent years, as it can overcome many problems associated with other forms of

manufacturing. AM is widely used for the production of surgical guides such as precision drilling aids, which improve accuracy and help to reduce surgical time (Bibb et al., 2009). AM surgical models also enable surgical teams to plan and practice complex procedures before an operation to help reduce the likelihood of potentially fatal errors occurring (Christensen et al., 2004). From Medicine to Aerospace, the use of AM is changing the way many industries are working. With an estimated global advanced manufacturing market value of £750 billion by 2020 (UK Commission for





**Figure 1. PolyJet process (adapted from Paterson et al., 2014).**

Employment and Skills, 2015), it is a highly lucrative area with many potential cost benefits.

There are many different 3D Printing systems available on the market, and all pose unique strengths and weaknesses (Hopkinson and Dickens, 2006). Some are synonymous to existing products which readers may already be familiar with; for example, PolyJet printers (Figure 1) are similar to consumer inkjet printers. However, the print heads deposit droplets of Photopolymer resin from cartridges as opposed to ink, which are then set or 'cured' with a UV lamp to build a solid layer. Once cured, the build platform moves down, and the process is repeated until a 3D object is built. 'Fused Filament Fabrication' (FFF) operates in a similar manner to heated glue guns, where

thermoplastic material is extruded through a heated nozzle, except the molten material is drawn out along a predefined path to help form each layer of a build.

#### **How could 3D Printing help advance splinting?**

There are several weaknesses associated with current splinting which can affect patient compliance; splints can become sweaty, odorous, unpleasant, difficult to clean and uncomfortable. Patients can also feel stigmatized, and may be reluctant to wear splints in social environments (Veehof et al., 2008). Therefore 3D Printing may pose a new approach to help overcome some of these issues. Since almost any geometry can be made, a custom fit can be provided, and skin ventilation can be improved by integrating open lattice patterns, the

designs of which can be specified by the patient with an aim to improve patient compliance (Figure 2).

There have also been significant advances in AM technologies since the layering method first emerged commercially in 1987 (Wohlert and Gornet, 2014).



**Figure 2. 'Swirl' splint built using ABS-like material on an Objet Connex PolyJet machine**

Multicolor, multimaterial builds are now possible (Figure 3), so different areas of the splint can



**Figure 3: Multicolor, multimaterial splint prototype**

feature different materials to offer additional functionality. For example, elastomer cushions could be placed over bony prominences for additional comfort, whilst hinges and clasps can also be integrated into splints to make them easier to put on and take off for patients without appearing cumbersome. What is important to note here is that both the patient and therapist have an opportunity to define the output of the treatment method; the therapist can maintain the same, if not increased level of clinical input into the design of the splint, whilst the patient can define more aesthetic qualities to suit their personal preferences. Collectively, 3D Printing is facilitating co-design.

#### **Are there any steps required before an object can be 3D Printed?**

There are a few preliminary steps required before a custom-fitted device can be 3D-Printed. Firstly, it is necessary to capture a 3D virtual representation of the patient's anatomy using a suitable 3D scanning technology (such as 3D laser scanning). Once acquired, this

scan data must then be adapted in 3D Computer Aided Design (CAD) software to define the thickness, shape and features of the splint. Once a splint has been designed in a suitable CAD software program, the virtual design can be sent to a suitable 3D Printer for manufacture.

#### **What technological advances make 3D Printing potentially viable for splinting?**

There have been significant technological advancements in recent years relating to scanning, CAD software and 3D Printing; from improved accuracy, usability, speed, material properties and cost. Games console motion sensors and smart phones can now be used to capture 3D scans of objects. Industrial 3D Printers can cost upwards of £700,000 but in recent years, technological advances and the expiry of patents have meant that some 3D Printers can be bought for less than £1,000. Alternatively, Internet-based service bureaux such as 3DPrintUK, Shapeways and iMaterialise can be used to manufacture parts in a range of materials for a reasonable fee if individuals do not have direct access to 3D Printers. Collectively, these developments in technologies, products and services have made AM more widely accessible and affordable, thereby stimulating worldwide interest (Dougherty, 2013).

#### **What are the future research/development directions to support 3D Printed splints?**

There are many exciting possibilities for 3D printing in the field of orthotics; for example, integration of discrete sensors is possible to monitor patient activities such as wear duration and temperature, and is already being explored for Ankle Foot Orthoses (Telfer et al., 2014). However, whilst 3D Printing has received a lot of interest in recent years, the technologies and infrastructure are not without their drawbacks. There are many areas that need further research and development. Materials are a key limitation at present, and more are needed which comply with standards such as ISO10993 and United States Pharmacopeia (USP) Classes I-VI.

Whilst the availability of 3D scanning technologies is becoming more affordable and accessible, there is no clear protocol to assist in capturing accurate scan data of the patient's external topography of their extremities. There is also a need to develop dedicated software for splinting practitioners, to help them design splints for their patients (Paterson et al., 2014; Paterson, 2013).

Cost is also a critical factor; splints weighing 120g made with low-cost FFF would cost less than £10 (excluding overheads). For comparison, splints built on a PolyJet machine would cost more than £300. The cost difference is due to a range of differing factors including materials, technology and

build parameters such as resolution. Whilst low-cost FFF splints may seem more affordable compared to other processes, low cost FFF machines are not currently intended for clinical use and are therefore less reliable or long lasting. 3D Printing machines are not 100% reliable and require maintenance, so technical staff would also be required to ensure machines run effectively. There is also a limited skills-base to support technical aspects relating to 3D Printing, as noted by the UK Commission for Employment and Skills (2015), which subsequently has led to a Government initiative to expand skills training in the UK. Therefore, there is a need to perform thorough cost-benefit analysis research into different healthcare sectors and understand what infrastructure changes would be needed if 3D Printing were to be implemented.

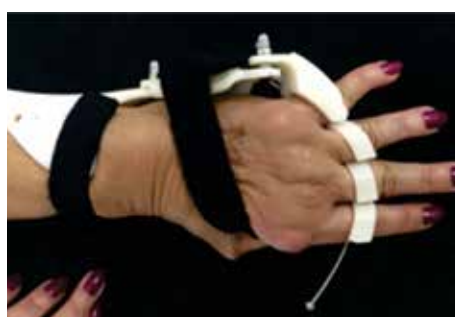There have been many examples of 3D Printed splints in the media recently, including Cortex (Evill, 2013), Osteoid (Karasahin, 2014), HealX (2013) and Amphibian Skin (3DMedScan, 2015). Whilst some examples of 3D printed splints may have received clinical input, some are prototypes and clinical validity is not always clearly documented. It is imperative that clinical trials be performed on any device proposed for 3D Printing; this includes the validity and effectiveness of designs and suitability of materials. Clinical studies have already begun, with Ribeirão Preto Medical School, Sao

Paulo exploring 3D Printing for ulnar deviation splints (Figure 4a, Figure 4b). However more studies are needed, which will require significant financial support.

Unregulated supply channels are also a concern; for example, there are open-source websites where almost anyone can share and download 3D CAD files. Splint files can be downloaded, 3D Printed, and then heated up in hot water before



**Figure 4a: Patient with ulnar deviation. Image courtesy of Valeria Elui, Ribeirão Preto Medical School, Sao Paulo**



**Figure 4b: 3D printed corrective ulnar deviation splint. Image courtesy of Valeria Elui, Ribeirão Preto Medical School, Sao Paulo.**

forming to fit an individual. This poses various health, safety and legal implications, should there be any injury as a result of the forming or use of the device. In addition,

each device is printed and applied by the user, who may not have any understanding on the reasons or rationale for splinting, and therefore may be causing more harm than good by wearing the device. Before this technology can be adopted into mainstream clinical practice, it is crucial that further testing of 3D Printed splints be performed under controlled, regulated channels to understand the impact they have on the patient and healthcare sector.

#### References

- 3DMEDSCAN, 2015, AmphibianSkin™ [online]. Available at: <http://www.threedmedscan.com/amphibianskin/> [Accessed 26 June, 2015].
- AMERICAN SOCIETY FOR TESTING AND MATERIALS INTERNATIONAL, 2012. Standard Terminology for Additive Manufacturing Technologies. ASTM F2792 - 12a. West Conshohocken, PA.: ASTM.
- BIBB, R., EGGBEER, D., EVANS, P., BOCCA, A. and SUGAR, A., 2009. Rapid manufacture of custom-fitting surgical guides. *Rapid Prototyping Journal*, 15(5), 346-354.
- CHRISTENSEN, A., HUMPHRIES, S., GOH, K.C. and SWIFT, D., 2004. Advanced medical imaging for separation surgeries of conjoined twins. *Child's Nervous System*, 20(8-9), 547-553.
- DOUGHERTY, D., 2013. The Maker Mindset. In: M. HONEY and D.E. KANTER, eds, *Design,*

*Make, Play: Growing the Next Generation of STEM Innovators.* New York, USA: Routledge, pp.

7-11.

- EVILL, J., 2013, Cortex [online]. Available at: <http://jakevilldesign.dunked.com/cortex> [Accessed 01 August, 2013].
- FESS, E.E., 2002. A History of splinting: To understand the present, view the past, *Journal of Hand Therapy*, 15(2), 97-132.
- HEALX, 2013, HealX 3D Printed Orthopaedic Braces: About Us [online]. Available at: <http://www.healxinnovation.com/#!about/c2414> [Accessed 09 April, 2014].
- HOPKINSON, N. and DICKENS, P.M., 2006. *Rapid Manufacturing: An Industrial Revolution for the Digital Age.* West Sussex: John Wiley & Sons, Ltd.
- KARASAHIN, D., 2014, Osteoid Medical cast, attachable bone stimulator by Deniz Karasahin [online]. Available at: <https://www.adesignaward.com/design.php?ID=34151> [Accessed 25 March, 2014].
- PATERSON, A.M., 2013. Digitisation of the Splinting Process: Exploration and Evaluation of a Computer Aided Design approach to support Additive Manufacture. PhD Thesis. Loughborough University.
- PATERSON, A.M., DONNISON, E., BIBB, R.J. and CAMPBELL, R.I., 2014. Computer Aided Design to support fabrication of wrist splints using 3D printing: A

feasibility study. *Hand Therapy*, 19(4), 102-113.

- TELFER, S., MUNGUIA, J., PALLARI, J., DALGARNO, K., STEULTJENS, M. and WOODBURN, J., 2014. Personalized foot orthoses with embedded temperature sensing: Proof of concept and relationship with activity. *Medical engineering & physics*, 36(1), 9-15.
- UK COMMISSION FOR EMPLOYMENT AND SKILLS, 2015, Sector Insights: skills and performance challenges in the advanced manufacturing sector [online PDF]. Available at: [https://www.gov.uk/government/uploads/system/uploads/attachment\\_data/file/439270/150626\\_AM\\_SLMI\\_report.pdf](https://www.gov.uk/government/uploads/system/uploads/attachment_data/file/439270/150626_AM_SLMI_report.pdf) [Accessed 12 June, 2015].
- VEEHOF, M.M., TAAL, E., WILLEMS, M.J. and VAN DE LAAR, M.A.F.J., 2008. Determinants of the use of wrist working splints in rheumatoid arthritis. *Arthritis Care & Research*, 59(4), 531-536.
- WOHLERS, T. and GORNET, T., 2014. History of additive manufacturing. Wohlers Report 2014 - 3D Printing and Additive Manufacturing State of the Industry: Annual Worldwide Progress Report [online]. Available at: <http://wohlersassociates.com/history2014.pdf> Wohlers Associates, Fort Collins, CO.

## URGENT HISTORIAN MESSAGE

We welcome contributions of any relevant information that you may have.

In particular, we seek copies of the minutes of the following meetings:

Executive Committee -

1967, 1968, 1969, 1970, 1972, 1973, 1974, 1975, 1976, 1977, 1978, 1979, 1980, 1982, 1984, 1985, 1986, 1997, 1998, 1999 and 2000.

Delegates Council -

June 2000 (Barcelona, Spain).

Please forward any

contributions to [administration@ifssh.info](mailto:administration@ifssh.info)



**FRANK BURKE**  
IFSSH Historian



# Member Society Updates

## THE AMERICAN SOCIETY FOR SURGERY OF THE HAND (ASSH)

### Join us in Austin

The American Society for Surgery of the Hand (ASSH) International Relations Committee welcomes the participation of hand surgeons from throughout the world in our 71st Annual Meeting to be held September 29 through October 1st, 2016 in Austin, Texas. This year's honored guest society will be the Japanese Society for Surgery of the Hand (JSSH). Posters submitted by the JSSH will be featured at this year's meeting and several speakers from the JSSH will enrich our program.

Austin, the capital of the state of Texas and home to the University of Texas will provide a vibrant venue for our meeting. It is a high-tech mecca claiming the nickname of "Silicon Hills." Austin is also known as "The Live Music Capital of the World" with many music venues providing live entertainment late into the night. Austin International Airport (AUS) is accessible through international flights from London, England, Toronto, Canada and by the time of our meeting from Frankfurt, Germany. Frequent connections are available from all US hubs.

### Become an ASSH International Member

ASSH International membership applications are welcome from members of international hand societies in practice at least 5 years with 2 letters of recommendation from active ASSH members. Member benefits include ASSH publications including the Journal of Hand Surgery American Volume as well as discounts on ASSH meeting registration fees and products. International members are encouraged to bring an international trainee to the ASSH Annual meeting without registration fee.

### Host an ASSH Visiting Professor

Senior "Visiting Professor" members of the ASSH are available to travel at the expense of the ASSH to host-society sponsored meetings in support of developing hand surgery programs throughout the world. Past host countries have included India, Bangladesh, Bolivia, Ecuador, Georgia, Indonesia, Colombia and the Philippines. Accommodations during the ASSH Visiting Professor stay will be the responsibility of the host society. We welcome applications from host societies. Applications from host societies should be directed to Danielle Roesmann at droesmann@assh.org.

Respectfully submitted,  
**Terry R. Light, M.D.**  
Chair, ASSH International Relations Committee

## AMERICAN ASSOCIATION FOR HAND SURGERY (AAHS)

**American Association for Hand Surgery and its Hand Surgery Endowment: Working together to advance global hand care and education and promote global hand health**

Coming off of a successful Annual Meeting in Scottsdale, Arizona, the American Association for Hand



Surgery is already at work planning its 2017 Annual Meeting to be held January 11-14, 2017 at the Hilton Waikoloa Village in Waikoloa, Hawaii. Under the direction of President Dr. Peter Murray and Program Chair Dr. Marco Rizzo, 2017 program is already well underway with insightful speakers, interesting panels, and social events for attendees to enjoy. <http://meeting.handsurgery.org/> While the planning of the 2017

Annual Meeting is certainly a focus of the Association this year, AAHS will also continue its energy on advancing global hand care and education through its partnerships with affiliate societies to offer international hand surgery courses and an e-lecture series in Ghana, in addition to putting out the highest quality content in its journal HAND. In 2016 AAHS's Hand Surgery Endowment will continue with its mission to promote global hand health through various programs, including granting volunteer scholarships to hand surgery fellows and hand therapists, and continuance of the Vargas Hand Therapy Teaching Award. The AAHS and its Endowment have been granting the Vargas Award for over 20 years and has funded hand therapy volunteerism in 13 countries through this program. In 2016, Aviva Wolff will travel to Guatemala as a Vargas Award recipient to provide care and education to the people of Chichoy Alto, Guatemala. Coupled with the HSE's additional outreach programs, the Endowment



leadership is hopeful to have an impactful year.

To learn more about the activities of the American Association for Hand Surgery and its Hand Surgery Endowment, visit <http://handsurgery.org/>.

## THE SOUTH AFRICAN SOCIETY FOR SURGERY OF THE HAND

The South African Society has had an active year with our Annual Congress being held in the Drakensberg in August of 2015 and the Annual Refresher Course (micro-vascular and micro-neural surgery) in Umhlanga KZN in February of this year.

We had two international guest speakers visiting us for these meetings. Mark Pickford visited us in "The Berg" and gave some fantastic talks on flap cover and toe to hand transfers. In February we were very fortunate to have Rod Hentz visit our shores. Rod was sponsored by the American Society for Surgery of

the Hand as one of their "Traveling Professors" and was able to spend a few weeks visiting several academic units and rural hospitals in KZN and the Western Cape. His visit coincided with the Refresher Course, and he gave several talks on nerve injury and repair as well as the management of brachial plexus injuries.

As a society we are most grateful to these international guests and their contribution to our society.

Regarding future plans; In August the Annual Congress will be held in Pretoria and Tommy Lindau from the Pulvertaft Hand Centre in Derby has offered to run a Wrist Arthroscopy Course the week before at the University of Stellenbosch.

We look forward to the triennial IFSSH meeting in Argentina in October and I'm sure a number of SASSH members will be there.

**Roger Nicholson**  
President SASSH



BRITISH SOCIETY FOR SURGERY OF THE HAND

The British Society for Surgery of the Hand (BSSH) continues to thrive. In 2015 under the presidency of Professor Vivien Lees, two very successful scientific meetings were held in Bath & London. The Autumn meeting, at One Great George Street, London was oversubscribed highlighting the popularity of these events. Dr Luis Scheker (Louisville), Professor Susan Mackinnon (Washington) & Dr Frederick Verstreken (Antwerp) were part of an invited faculty who informed and entertained with excellent lectures/symposia held on complex disorders of the forearm, strategies for nerve repair and the application of 3D technology for reconstruction & correction of bony deformity.

This April we return to the Royal College of Surgeons in London for the Spring meeting, organised by BSSH president for 2016 Rupert Eckersley. This promises to be an illuminating broad spectrum event with invited experts speaking in symposia on Cerebral Palsy, Evidence based Hand Surgery, Implant Science and Research in Hand surgery. The invited faculty includes Professor Michael Tonkin (Sydney), Professor Geoff Richards (Davos), Dr Eva Ponten (Karolinska Inst) & Dr Terry Axelrod (Toronto) and a host of UK national figures. All are welcome.

The BSSH hand website has been

totally revamped and we are grateful to the input of Charles Pailthorpe and his team. It went live on the 1st March, 2016. Constructive feedback gratefully received.

Following the highly successful inaugural BSSH cadaver masterclass on the PIP Joint, held in Manchester last June, a second is planned for the 2nd June, 2016 on Wrist Arthroscopy. These are proving very popular amongst hand surgeons from around Europe, and once again an international faculty has been brought together for a 'hands on' learning experience. The BSSH Instructional Course programme follows 3-4/6 covering wrist & occupational & medicolegal aspects of hand surgery. These courses continue to be very well attended providing advanced teaching at senior trainee or consultant level, with lecturers invited from around the globe and are open to everyone.

The BSSH is one of the founding members of the IFSSH. With BAHT, we are about to submit our joint bid to host the IFSSH/IFSHT meeting in 2022. We have a long established track record in organising a range of national and international scientific meetings, many in collaboration with the other IFSSH member societies. We are excited by this opportunity to host you in London for the first time.

London is one of the world's great cities. It has excellent

conference facilities, a range of accommodation and unrivalled international accessibility. Visitors can enjoy London's stunning historical architecture, world-renowned scientific and cultural museums (all of which are free to enter) and some of the world's most iconic landmarks. London is also an ideal base from which to explore the rest of the UK and Europe.



We are offering a superb conference venue in Westminster, in the heart of the city. It is a thoroughly modern facility, with spacious lecture theatres, numerous meeting rooms and state of the art audiovisual facilities. The conference centre overlooks the Houses of Parliament and has excellent travel links. The costs of accommodation, eating out and transport in London are comparable to other capital cities and we would deliver an affordable meeting for delegates to attend. The financial stability of the UK makes it a secure venue for hosting a large congress. If our bid is successful we will deliver a spectacular academic,

scientific and clinical hand surgery meeting, with a social programme to match! David Newington and David Shewring, British Society for Surgery of the Hand

NETHERLANDS SOCIETY OF SURGERY OF THE HAND

The Netherlands Society of Surgery of the Hand was founded in 1972. In 2012 we celebrated our 40th anniversary in a beautiful hall of the famous zoo Artis in Amsterdam. We had two wonderful international speakers, Brian Adams and Guillaume Herzberg. Furthermore we invited a very special guest, Guido Danielle, a famous Italian artist who performed live painting on the hand of a renowned Dutch television host. A picture of this artwork was sold in an auction for charity (the Liliane foundation).

Since then we have had two scientific conferences per year. At each event we have had presentations from our own members and great presentations from renowned international guest speakers. In the table you will find an overview of our themes and speakers.

In January 2016 we have filled a special issue of the Dutch Journal for Plastic Surgery with papers about hand surgery.

The society has been through an important growth and we have now

reached more than 200 members. At present we are working hard to get an accreditation for Hand surgery in the Netherlands. Hand surgery is performed in the Netherlands by Plastic Surgeons, Orthopaedic surgeons and Trauma surgeons. Our society has members with different backgrounds and our present challenge is to get consensus on criteria like the distribution of the workload, differentiation within hand surgery, and basically what makes a surgeon a good hand surgeon? In this quest we are glad to know that we can get

Spring 2011	Wrist arthroscopy	Dr F. Del Pinal Prof C. Mathoulin
Fall 2011	Anatomy	Dr R.A. Berger Prof D.A. MacGrouther
Spring 2012	State of the art treatment in hand surgery	Local speakers
Fall 2012	Implants	Dr B.D. Adams Prof G. Herzberg
Spring 2013	Joint meeting with rheumatologists	Lokal speakers
Fall 2013	PIP joint (joint meeting with hand therapists)	Dr A. Lluch
Spring 2014	Meeting with the Belgian Hand Group	
Spring 2014	New techniques in Hand Surgery	Local speakers
Fall 2014	Bones	Dr S. Moran Dr C. Heras-Palou
Spring 2015	Ulnar sided wrist pain	Dr J-R Haugstvedt Dr A. Atzei
Fall 2015	Tendons (joint meeting with hand therapists)	Dr J-B Tang
Spring 2016	Ligamentous lesions	Dr E. Camus Dr D. Lichtman

support from hand surgeons in neighbouring countries who have been through this process before us and, of course, from FESSH.

Similar to the IFSSH, our goal is to increase and spread knowledge of surgery of the hand and thus create awareness among the population that surgery of the hand requires specific knowledge and skills. Furthermore we support our hand surgeons to deliver optimal care for their patients by promoting research and share knowledge.



**Dr Miryam C. Obdeijn****President of the Netherlands****Society for Surgery of the Hand**

**Current board of the Netherlands Society for Surgery of the Hand with our former president.**



**From left to right: Brigitte van der Heijden (Vice-president), Miryam Obdeijn (President), Johan Vehof (Treasurer), Ruud Deijkers (Secretary General), Henk Coert (former President), Tom van Mulken (Secretary)**

## SPANISH SOCIETY FOR HAND SURGERY (SECMA)

**New Board of the SECMA.**

The new board of the Spanish Society was constituted during the last national meeting in Murcia in May 2014. The new President is Dr. Angel Ferreres and General Secretary is Dr. Luis Aguilera. The rest of the Council members elected by the general assembly were: Dr. Pilar Pradilla (Vice-president), Dr. Guillem Salvá (Treasurer), Dr. Adolfo Galán (Vice-secretary), Dr. Pedro J. Delgado (Editor of The Ibero-American Journal of Hand Surgery), Dr. Fernando Corella

(Director of The Ibero-American Journal of Hand Surgery), Dr. Marta Guillen (website manager), Dr. Joaquim Casañas (communication coordinator), and Dr. R. S. Rosales (International Delegate).

SECMA & RICMA (The Ibero-American Journal of Hand Surgery). The new online version of the "Revista Iberoamericana de Cirugía de la Mano (RICMA)", the Ibero- American Journal of Hand Surgery, has contracted "Elsevier" as new Editorial Company and at the end of 2015 it has been indexed in Sciencedirect (<http://www.elsevier.es/es-revista-revista-iberoamericana-cirugia-mano-134>;

<http://www.sciencedirect.com/science/journal/16988396>). A new editorial manager website will help authors to submit their manuscripts to RICMA. The editorial staff, Dr. Fernando Corella and Dr. Pedro J. Delgado, have carried out tremendous work for that purpose (<http://revistaiberoamericanamano.org/>).

## XXI FESSH MEETING IN SANTANDER

The 21st meeting of the FESSH will be held in Santander from June 22nd to 25th. The President of the Congress, Dr. Francisco del Piñal, welcomes you to Santander, the "bride" of the Atlantic Ocean and one of the safest cities in Europe.

**SECMA AND ASSH**

SECMA was the 2015 International Guest Hand Society at the 70th ASSH Annual Meeting, from September 10-12, 2015 in Seattle, Washington, USA. The Spanish society collaborated in the scientific program with two instructional courses and poster presenters at the international guest society poster section. Dr. Mireia Esplugas, received the Kaplan Award for the study: Muscle Control of the First Carpometacarpal Joint (co-authors: Alex Lluçanès, Marc Garcia-Elias, Nathalie Mobargha and Elisabet Hagert)

## VIII INSTITUTIONAL SECMA COURSE

SECMA offers a two-day institutional instructional course

every year, with lectures and lab cadaver sessions. This year, the course will take place in Madrid under the direction of Dr. Pedro J. Delgado on 26-27th May.

## IV INSTITUTIONAL SECMA COURSE IN METHODOLOGY OF CLINICAL RESEARCH IN HAND SURGERY

SECMA offers a day course in clinical research methodology and data analysis. This year the course will be organized by Dr Guillem Salva in Palma de Mallorca. The course is free for SECMA members and Dr R S Rosales will be the professor. The course will approach the clinical design, level of evidence, the use of patient reported outcome instruments and data analysis using the SPSS Statistics.



**The Board of the SECMA and members who received the Kaplan Award during the ASSH meeting in Seattle**

**R S Rosales MD, PhD**

## International Delegate of the Spanish Society

## SWITZERLAND SOCIETY FOR HAND SURGERY

**Bridges**

The Swiss Hand Surgery Society (SGH) with its 243 ordinary and extraordinary members enjoyed an interesting Congress together with the Hand Therapists (SGHR) in Fribourg an old medieval town hosted by the president (Michaël Papaloizos, Geneva) last November 2015. Within this city, there is a marvelous new bridge (Poya bridge) connecting the french and german speaking part of Switzerland. Therefore the congress was held under the title: bridges – past, present & future.

During 2 days, the 680 Participants



built bridges to merge different opinions as well as to link surgeons and therapists in sessions by lively discussions and interesting workshops.

The next congress will be the 50th anniversary of the SGH and

18th anniversary of SGHR. It will therefore be an international congress together with the Belgian hand group, the Belgian Hand Therapists and the Dutch Society for Hand Therapy held on the 24th/25th of November 2016 at the Palexpo Congress Center in Geneva, with the topic: "Hand surgery at the crossroad between science and craftsmanship" – an invitation to recognize the contributing values of our specialty of both the basic science and the transmitted experience from one generation to the next one

In a politically challenging time with pressure on medical costs, the implementation of a new tariff structure for outpatient services as well as the continuous demands for a highly focused training of young surgeons without a preexisting surgical specialty, the council of the SGH is faced with a large amount of work after we have been a fully acknowledged specialty with its own curriculum by the Swiss Medical Association (FMH).

All surgical disciplines that became recently independent (i.e. vascular and thoracic surgery) are confronted with such challenges. Therefore, the idea of forming a big "surgical family" by the Swiss Society of Surgery was born. All of the newly independent societies share common interests and duties such as a common trunk of 2 years general surgical training completed by the basic examination.



Furthermore, increasing political demands (i.e. quality registers, defining minimal data sets for health insurances, pricing problems and many more) may benefit from an efficient umbrella organization. Such a head organization may be advantageous for smaller specialties in order to be heard among politicians as well as the public.

The next step will be the foundation of this family as a Swiss College of Surgeons, defining its role, rights and duties, linking the interests of member specialties. A challenging time requiring new bridges - stay tuned, we will inform you in our next article.

Esther Vögelin and Mario Bonaccio

## VENEZUELAN SOCIETY FOR SURGERY OF THE HAND (VSSH)

The current legal system in Venezuela includes the entire upper extremity as domain of the Venezuelan Society for Surgery of the Hand (VSSH). This is based on the concept by Sterling Bunnell, who in 1945 stated that the hand is founded on the upper extremity, which in turn is rooted in the motor and sensory cortex of the brain.

The XXXII Conference of the VSSH was held in Caracas from 10 to 12 June 2015, in honour of Dr. Rodolfo Contreras Gamboa, who is a pioneer of Hand Surgery in Venezuela. The



**Back row from left to right; Doctors: International Guests: Jefferson Braga and Samuel Ribak of Brazil, Eduardo Zancolli of Argentina, Past President and Secretary of Continuing Medical Education: Ramiro Morales, Secretary of Institutional Relations: Gaetano De Santolo, General Secretary: Aloha Isea, Past President: Nelson Socorro, CEO IFSSH: Igor Indriago, Past President: Rafael Brunicardi, Secretary Recertification: Zobeira Rivero, Past President and Vice-President: Alvaro Aguilar, Past-Presidents: Leonardo Briceño, Ricardo Tobio, Maggali Torrealba, José Guerrero, Secretary of Finance: Ymaru Rodriguez, Guest International: Diego Fernandez of Switzerland and Current President of the Society 2014-2016: Jose Vicari. Front row from left to right: Past President: Magally Ortiz, Founder and Past Presidents: Antonio De Santolo and Rodolfo Contreras, Past Presidents: Jose Camarillo and Alberto Urquiola.**

following international speakers were present: Diego Fernandez from Switzerland, Eduardo Zancolli from Argentina, Jorge Clifton from Mexico, Jefferson Braga and Samuel Ribak from Brazil. They were made Honorary Members of the VSSH as well as Affiliate Correspondents, and were much appreciated by the 285 participants who attended the meeting.

During the same Congress, all the Past-Presidents of our Society were presented with the "Order of Merit for Excellence" for their contribution to develop Hand Surgery as a specialty in our country during the past 42 years. The same honour was also

awarded to Dr. Alberto Serrano, current President of the Venezuelan Society of Orthopaedic Surgery and Traumatology, for his assistance in the realization of this congress, as well as Ms. Liliana Bustos, who was Secretary of the Society for more than 20 years.

The next Venezuelan Congress is planned for 14-16 July 2016, and will be held in honour of Dr Jose Rafael Camarillo Morillo, also a pioneer of hand surgery in this country. The following international speakers will be invited to present papers at this meeting: Aldo Beltran and Giovanni Montealegre from Colombia, Jorge Clifton from Mexico, Gabriel Clembosky from



**International Guests: Aldo Beltran and Giovanni Montealegre of Colombia, Jorge Clifton of Mexico, Gabriel Clembosky of Argentina, Cristhian Castro of Costa Rica, Antonio Tufi and Nilton Mazer of Brazil.**

Argentina, Cristhian Castro from Costa Rica, Antonio Tufi and Nilton Mazer from Brazil.

The VSSH Congress is a part of the calendar of activities of the South American Federation of Societies for Surgery of the Hand, and

therefore also of the IFSSH.

Everybody is invited to attend the Congress, and grace this event with their presence!

## SINGAPORE SOCIETY FOR HAND SURGERY

**Event 1: 25th Annual Hand Review Course and Inaugural Joint Meeting of the Singapore and Italian Societies for Hand Surgery**

The Singapore (Singapore Society for Hand Surgery, SSHS) and Italian (Società Italiana di Chirurgia della Mano, SICM) Hand Societies held their first combined scientific meeting from 25th to 27th February 2016 at the National University Hospital, Singapore ([www.sgband2016.com](http://www.sgband2016.com)). The first day consisted of instructional lectures on core topics while next two days were focused on the theme of 'Controversies in Hand Surgery'. Speakers from both societies exchanged their views and experience on topics that spans the breadth of hand surgery. The meeting was a great success and attended by 138 delegates. In addition to talks by invited speakers, there were 15 free papers and over 25 posters.

Apart from lively scientific arguments, participants and faculty had the chance to mingle in the panoramic roof terrace of the hospital as well as the idyllic setting of a colonial villa to enjoy cuisine of the orient. Many visited the bio-domes and giant tress of the Gardens by the Bay and the iconic Marina Bay Sands casino, and the nearby island resorts of Indonesia. The relationship between the two





societies was a culmination of the long standing friendship between Robert Pho and Roberto Adani that began in 1989 at the National University of Singapore.

#### Event 2: Inaugural Singapore Wrist Arthroscopy Course

The inaugural Singapore Wrist Arthroscopy Course was held from 27th to 28th February 2016. It was designated to be a post congress event just after the Joint meeting of the Singapore Society for Hand Surgery and the Italian Society for Surgery of the Hand. This course was organized by the Department of Hand Surgery, Singapore General Hospital and the Sing-Health Surgical Skills Centre and jointly endorsed by The Singapore Society for Hand Surgery, The Italian

Society for Surgery of the Hand, The European Wrist Arthroscopy Society and The Asia Pacific Wrist Association.

A formidable team of 14 international faculties comprising mainly active members of the European Wrist Arthroscopy Society, the Asia Pacific Wrist Association and six experienced local faculty formed the faculty for the course. The three course co-directors were Dr Andrew Chin from Singapore, Dr Andrea Atzei from Italy and Dr Jan-Ragnar Haugstvedt from Norway. The 1st part of the course was held in the afternoon of 27th February where the programme comprised expert lectures and discussions. The 2nd part on 28th February was the whole day practical session held in

the cadaver laboratory. Two types of courses, basic and advance, were conducted simultaneously.

The course had 30 participants (22 basic and 8 advanced), making the faculty to participant ratio of 2:3. This ensured that the participant received very close supervision and guidance from the experts. This was the most positive feedback from the participants as it facilitates their learning at their own pace and also ensuring that the novice picked up the fundamentals in handling of the scope and develop good habits right from the start.

The overall success of the course has spurred us on to plan for subsequent course to be held again in Singapore in early January 2017.



#### PORTUGUESE HAND SURGERY SOCIETY - SPOCMA

The board of SPOCMA is:

- Dra Maria Manuel Mouzinho - President
- Dr Fernando Cruz - Vice-president and international delegate
- Dr David Rasteiro Vice-president
- Dr Pedro Negrão - Secretary
- Dr Horácio Costa - Treasurer

The Portuguese national hand surgery congress would be held in Peniche, Portugal on 23rd and 24th September 2016. Further information about the society can be found on the webpage - <http://spocma.pt/>  
Fernando Cruz, SPOCMA Vice-president and Portugal International delegate



23 e 24 de Setembro 2016  
Peniche - Hotel MH Peniche

XXIV CONGRESSO PORTUGUÊS DE  
CIRURGIA DA MÃO

**Temas:**  
Mão Catastrófica e Reconstrução Complexa;  
Transplante de Mão;  
Avanços na Artroscopia do Punho e Mão

**Palestrantes Convidados:**  
Dr. Francisco del Piñal (Santander, Espanha)  
Prof. Horácio Costa (Gaia, Portugal)  
Prof Marco Lanzetta (Monza, Itália)

[www.congressocirurgiadamao2016.pt](http://www.congressocirurgiadamao2016.pt)

Exposição e Concurso de Fotografia  
por Cirurgiões da Mão





## SPOTLIGHT ON IFSHT MEMBER SOCIETY: CZECH REPUBLIC

The Czech Society for Hand Therapy, established in 2012, currently has 30 members. In November 2015 the Society held its second Congress for Hand Therapy where therapists participated in a two-day splinting course, sponsored by IFSHT, and taught by Nicola Goldsmith and Sarah Mee. The course provided an outline of splinting principles and delved into the complexities and application of static, static progressive, and dynamic splints. Attendees were pleased to gain new skills which could be utilized in everyday practice.



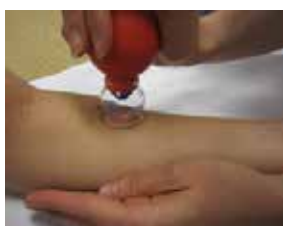Above: Czech Society Executive Committee. Left: Czech therapists participate in splinting course.



The Czech Society plans to begin circulating a member newsletter and to offer structured hand therapy courses. The society is keen to cooperate with other societies abroad who can help in developing hand therapy professional standards. If you are in a position to help, contact [secretarygeneral@ifsht.org](mailto:secretarygeneral@ifsht.org) who will put you in contact with Milada Kukačková, IFSHT Delegate.

## IFSSH EZINE

The February 2016 IFSSH Ezine (<http://www.ifssh.info/ezine.html>) presents an evidence based approach to the use of massage, mobilisation, thermal modalities, compression, iontophoresis, and taping in the management of scars. This article is written by Meghann Berchtold, Vera Beckmann-Fries and Christine Meier Zürcher from Zurich, Switzerland.



Use of suction for scar management

# UPDATE

## 2016 IFSSH/IFSHT CONGRESS

**Program:** Lorimer Moseley from Australia will present a keynote lecture entitled 'Pain and the Brain,' joining many other internationally recognized experts. The scientific program is available at <http://www.ifsht.org/page/triennial-congress>.



**Registration:** Open at <http://www.ifssh-ifsht2016.com/registro.php>.

**Silent Auction:** This important event raises much-needed funds to support both speakers and therapists with financial hardships attend the next IFSHT conference (Berlin, 2019). Please consider donating small and easily transportable items. Educational resources, assessment tools, or objects of art are suggested. To register your donation for 2016 go to <http://www.ifsht.org/page/silent-auction-buenos-aires-2016>.

**Travel Grant Applications:** Apply online <http://www.ifsht.org/page/ifshtifssh-triennial-congress-travel-grant-0>.

## SWEDISH NATIONAL CONFERENCE



Sarah Ewald (L) with Ann Sundbom

The Swedish Association of Hand Rehabilitation held their annual meeting on March 17, 2016 in Uppsala, Sweden. President Ann Sundbom welcomed Sarah Ewald, IFSHT President, who attended the meeting as an invited speaker. About 135 people attended this lively conference where topics included the flexor tendon, the wrist, and patient education.

## HAND THERAPY CONNECTIONS E-NEWS

Sign up to be included in the IFSHT Hand Therapy Connections E-mail sent 2-3 times per year with information about events in the hand therapy community. Please log in at <http://ifsht.org/page/e-mail-newsletter> to sign up.

For hand therapy educational events, go to "National/International Education Events" under "Education" at [www.IFSHT.org](http://www.IFSHT.org).

# Applications to host the 2022 IFSSH & IFSHT Congress



Dear Delegates,

We wish to remind all Societies that the 2022 congress host society will be chosen by the IFSSH Delegates' Council during the 2016 triennial congress in Buenos Aires (October 24-28, 2016).

Submissions to host the 2022 IFSSH congress are invited from the member societies of the European region\*. Information regarding the application process is on the IFSSH website: <http://ifssh.info/guidelines.html>

This main scientific event of the IFSSH will be celebrated every three years in a member society country that is in good standing with the IFSSH, including payment of their annual dues. The society hosting the event will be selected from applications six years before at the annual Delegates' Council meeting. Those societies from countries which also have a hand therapy association/society should discuss the possibility of hosting a combined meeting. The societies which are applicants must submit a formal petition to the Secretary General at least three months ahead of the Council meeting. The same documentation should be sent to each member country delegate and IFSHT representative for evaluation at least three months before the Council Meeting.

Therefore, any European member society that is interested in hosting the 2022 IFSSH Congress should inform the IFSSH Executive of their intentions and ensure that the full bid is forwarded, as detailed in the instructions above, by July 24th 2016, for consideration at the Buenos Aires meeting.

*\*The IFSSH member societies have been geographically grouped according to United Nations data. The IFSSH "European" region consists of: Austria, Belgium, Bulgaria, Czech Republic, Denmark, Finland, France, Germany, Greece, Hungary, Italy, Lithuania, Netherlands, Norway, Poland, Portugal, Romania, Russian Federation, Slovakia, Spain, Sweden, Switzerland, Turkey, United Kingdom. For the purposes of the IFSSH congress rotation system, the two IFSSH member nations that lie within the African region - Egypt and South Africa - have been aligned with the European region and are therefore also able to bid for the 2022 Congress.*

Yours sincerely,

Marc Garcia-Elias  
Secretary-General, IFSSH





# Pearls of wisdom

## David Warwick

Sometimes we face a dilemma when advising a patient with a displaced extra-articular distal radius fracture. Should we offer surgery or should we not? In those countries where litigation is prevalent, and that certainly includes the United Kingdom, we have to be very aware of criticism, unfair or otherwise, from a patient and their legal advisors who might even hope for financial redress.

Of course we monitor the fracture for the first 10 to 14 days. Some fractures are so displaced initially,

or displace so rapidly after an initial closed reduction in the Emergency Room, that surgical stabilisation seems obvious. Not to do so would predictably lead to a poor result. But what amount of angulation/shortening can be accepted? We know that in fact most patients with extra-articular radius fractures (and indeed intra-articular as well) do very well regardless of the final anatomical position (Finsen et al 2013), especially in older and lower demand patients. Thus surgery for anatomical perfection

is by no means always needed. We also know that volar plate fixation is not without risk- 16% get a complication (Bentohami et al 2014) and is an expensive intervention. Finally we also know that distal radius osteotomy for an extra-articular fracture is a reliable operation with good results when performed carefully, before secondary changes in the mid-carpus and the DRUJ.

So if a patient has a fracture with 2 or 3mm of shortening, and/or 10 or 20 degrees of dorsal tilt at

the two week xray, do we accept or do we operate? If the patient is left alone and then goes on to a symptomatic malunion they will be dissatisfied and may even litigate. But supposing a volar plate is inflicted on them and the patient then had a tendon rupture or infection, they might be equally dissatisfied and may even litigate.

“Displaced extra-articular distal radius fracture.... most (patients) do wait and see and most never need an operation.”

It is always wise to avoid unnecessary surgery- surgery is expensive and hazardous. So I try and frame the discussion with the patient as follows:

If we operate now for this mildly displaced fracture, there is a 100% chance of a precipitous operation now for your fracture for which

there is only a 20% chance of really needing an operation (osteotomy) in the future were you to have waited instead. But if we avoid surgery now, and wait & see instead, there is only a 20% chance of you needing an operation in the future; that operation (osteotomy) is almost the same as surgery now- a cut at the front of the wrist and a metal plate but perhaps with a small incision from the edge of the hip for some bone graft or perhaps some artificial material in the gap.

Since I took up this consent process (and it applies to many other situations we face in hand trauma) I have found my unease in difficult grey areas has been mollified and I find my patients really appreciate becoming engaged. As it happens, most do wait and see and most never need an operation- the 20% is, I suspect, an overestimate.

- Finsen et al (2013) The relationship between displacement and clinical outcome after distal radius (Colles') fracture J Hand Surg(Eur) 2013; 38: 116-126
- Bentohami et al (2014) Complications following volar locking plate fixation for distal radial fractures: a systematic review. J Hand Surg (Eur) 2014 ;39: 745-54

**Professor David Warwick.**  
MD BM FRCS FRCS(Orth)  
European Diploma of Hand Surgery

**Consultant Hand Surgeon**  
**R and D Lead Div D**  
**Secretary British Society for**  
**Surgery of the Hand**

**NHS/Academic Address:**  
**Orthopaedics, University Hospital**  
**Southampton,**  
**Faculty of Medicine, University**  
**of Southampton**  
**Southampton SO16 6UY, United**  
**Kingdom**

## JOURNAL OF HAND SURGERY EUROPEAN VOLUME

(MARCH 2016)

- Assessment of surgery for the underdeveloped thumb  
Michael A. Tonkin  
41: 251-252,
- Outcome of two types of surgical correction of the extra phalanx in triphalangeal thumb: is there a difference?  
J. M. Zuidam,  
R. W. Selles,  
M. de Kraker,  
and S. E. R. Hovius  
41: 253-257,
- Outcome of flexor digitorum superficialis opponensplasty for Type II and IIIA thumb hypoplasia  
M. de Kraker,  
R. W. Selles,  
J. M. Zuidam,  
H. M. Molenaar,  
H. J. Stam,  
and S. E. Hovius  
41: 258-264,
- A clinically weighted approach to outcome assessment in radial polydactyly  
R. Dijkman,  
R. Selles,  
J. van Rosmalen,  
W. Hülsemann,  
M. Mann,  
R. Habenicht,  
S. Hovius,  
and C. van Nieuwenhoven  
41: 265-274,

- Defining postoperative stability in children with radial polydactyly  
T. O. Engelhardt,  
G. Djedovic,  
F. Pedross,  
and H. Piza-Katzer  
41: 275-280,
- Paediatric toe-to-hand transfer: an assessment of outcomes from a single unit  
D. Nikkhah,  
N. Martin,  
and M. Pickford  
41: 281-294,
- Pollicization of the index finger requiring secondary fusion of the new metacarpophalangeal joint  
M. M. Al-Qattan  
41: 295-300,
- Synpolydactyly of the hand: a radiographic classification  
L. B. Wall,  
D. S. Bae,  
S. N. Oishi,  
R. P. Calfee,  
and C. A. Goldfarb  
41: 301-307,
- Transverse soft tissue distraction preceding separation of complex syndactylies  
J. A. Lohmeyer,  
W. Hülsemann,  
M. Mann,  
and R. Habenicht  
41: 308-314,
- Long-term results of syndactyly correction by the trilobed flap

- technique focusing on hand function and quality of life  
A. Widerberg,  
K. Sommerstein,  
L. B. Dahlin,  
and H.-E. Rosberg  
41: 315-321,
- High revision rates with the metal-on-metal Motec carpometacarpal joint prosthesis  
J. K. Thillemann,  
T. M. Thillemann,  
B. Munk,  
and K. Krøner  
41: 322-327, f
- Unfavourable short-term outcomes of a poly-L/D-lactide scaffold for thumb trapeziometacarpal arthroplasty  
S. Mattila and  
E. Waris  
41: 328-334,
- Comparison of clinical outcome with radiological findings after trapeziectomy with ligament reconstruction and tendon interposition  
L. Reissner,  
M. Marks,  
S. Schindele,  
and D. B. Herren  
41: 335-339,
- Measurements of surgeons' exposure to ionizing radiation dose: comparison of conventional and mini C-arm fluoroscopy  
K. H. Sung,  
E. Min,  
C. Y. Chung,

B. C. Jo,  
M. S. Park,  
and K. Lee  
41: 340-345,

- Twin born with a skeletonized hand in twin-to-twin transfusion syndrome treated with laser ablation in pregnancy  
L. Garagnani,  
M. A. Weber,  
and G. D. Smith  
41: 346-347,
- The mermaid procedure for a complex hand anomaly  
Woan-Yi Chan,  
Vadivel Moonesamy,  
and Vikram Devaraj  
41: 347-348
- Congenital anonychia  
A. Qureshi,  
K. Y. Wong,  
and I. Grant  
41: 348-349,
- Matriderm' dermal substitute with split-thickness skin graft compared with full-thickness skin graft for the coverage of skin defects after surgical treatment of congenital syndactyly: results in 40 commissures  
F. Duteille,  
M. V. Truffandier,  
and P. Perrot  
41: 350-351,
- A functional test in assessment of hand dexterity in young children  
K. Iba,

R. Shirato,  
and T. Yamashita  
41: 352-353,

- Zhao L, Chen X, Zhang L. Digital necrosis after triamcinolone acetone injection for trigger thumb: case report. J Hand Surg Eur. 2015, 40:741-2  
Jose Couceiro Otero  
41: 354,

## JOURNAL OF HAND SURGERY AMERICAN (FEBRUARY 2016)

- Shoulder and Elbow Recovery at 2 and 11 Years Following Brachial Plexus Reconstruction  
Jung-Pan Wang,  
Schneider K. Rancy,  
Steve K. Lee,  
Joseph H. Feinberg,  
Scott W. Wolfe  
173-179
- Risk Factors for Ulnar Nerve Instability Resulting in Transposition in Patients With Cubital Tunnel Syndrome  
Jonas L. Matzon,  
Kevin F. Lutsky,  
C. Edward Hoffler,  
Nayoung Kim,  
Mitchell Maltenfort,  
Pedro K. Beredjiklian  
180-183
- Outcomes of Elbow Arthroscopic Osteocapsular Arthroplasty  
Samuel E. Galle,  
John D. Beck,

Raoul J. Burchette,  
Neil G. Harness  
184-191

- Hook Plate Versus Suture Anchor Fixation for Thumb Ulnar Collateral Ligament Fracture-Avulsions: A Cadaver Study  
Emily H. Shin,  
Matthew L. Drake,  
Brent G. Parks,  
Kenneth R. Means Jr.  
192-195
- Extension Block Pinning for Unstable Proximal Interphalangeal Joint Dorsal Fracture Dislocations  
Eero Waris,  
Simo Mattila,  
Tarvo Sillat,  
Teemu Karjalainen  
196-202
- Radiographic Parameters to Predict Union After Volar Percutaneous Fixation of Herbert Type B1 and B2 Scaphoid Fractures  
Mostafa Mahmoud,  
Mohamed Hegazy,  
Sherif Ahmed Khaled,  
Nasef Mohamed Nasef Abdelatif,  
Walid Osman,  
John C. Elfar  
203-207
- Biomechanical Evaluation of Scaphoid and Lunate Kinematics Following Selective Sectioning of Portions of the Scapholunate Interosseous Ligament  
Michael S. Waters,  
Frederick W. Werner,



Stefanos F. Haddad,  
Michael L. McGrattan,  
Walter H. Short  
208–213

- Negative Ulnar Variance and Kienböck Disease  
Wouter F. van Leeuwen,  
Kamilcan Oflazoglu,  
Mariano E. Menendez,  
David Ring  
214–218

- Assessment Following Distal Radius Fractures: A Comparison of 4 Scoring Systems, Visual Numerical Scales, and Objective Measurements  
Scott L. Barker,  
Haroon Rehman,  
Anna L. McCullough,  
Shona Fielding,  
Alan J. Johnstone  
219–224.e1

- Relative Contribution of the Subsheath to Extensor Carpi Ulnaris Tendon Stability: Implications for Surgical Reconstruction and Rehabilitation  
Andrew C. Ghatan,  
Sameer G. Puri,  
Kyle W. Morse,  
Krystle A. Hearn,  
Caroline von Althann,  
Michelle G. Carlson  
225–232

- Bidirectional Dislocation of the Distal Radioulnar Joint After Distal Radius Fracture: Case Report

Sayuri Arimitsu,  
Hisao Moritomo  
233–236

- Variables Prognostic for Delayed Union and Nonunion Following Ulnar Shortening Fixed With a Dedicated Osteotomy Plate  
Michael P. Gaspar,  
Patrick M. Kane,  
Ralph C. Zohn,  
Taylor Buckley,  
Sidney M. Jacoby,  
Eon K. Shin  
237–243.e2

- Flexor Digitorum Superficialis Opposition Transfer for Augmenting Function in Types II and IIIA Thumb Hypoplasia  
Carley Vuillermin,  
Lesley Butler,  
Amy Lake,  
Marybeth Ezaki,  
Scott Oishi  
244–249

- Journal CME Questions  
250

- Six Cases of Myofibroma – The Adult Counterpart of Infantile Myofibromatosis: Case Report  
Mohammad M. Al-Qattan,  
Maha M. Arafah  
251–256

- Patient Satisfaction and its Relation to Perceived Visit Duration With a Hand Surgeon  
Raymond C. Parrish II,  
Mariano E. Menendez,  
Chaitanya S. Mudgal,

Jesse B. Jupiter,  
Neal C. Chen,  
David Ring  
257–262.e4

- Prevalence of and Factors Associated With Major Depression in Patients With Upper Extremity Conditions  
Kamilcan Oflazoglu,  
Jos J. Mellema,  
Mariano E. Menendez,  
Chaitanya S. Mudgal,  
David Ring,  
Neal C. Chen  
263–269.e7

- Yesterday, Today and Tomorrow: Using the Past and Present to Enhance and Prepare for the Future  
William H. Seitz Jr.  
270–284

- Hands on Stamps: United States 1983–Lend a Hand  
Jia-Guo Zhao  
285

- Hands on Stamps: Hong Kong, China, 2014–International Day of Families  
Tiegang Zheng,  
Rui Yang  
285–286

- Hands on Stamps: Greece 1977–Bloodletting From the Upper Limb  
Ahmadreza Afshar,  
Neda Afshar  
286

- Use of the Volar Plate of the Distal Interphalangeal Joint as a Distally Based Flap in Flexor Tendon Surgery  
Mohammed M. Al-Qattan  
p287–290

- History and Nomenclature of Multistrand Repairs in Digital Flexor Tendons  
Robert Savage,  
Jin Bo Tang  
291–293

- Surgical Approaches to the Proximal Interphalangeal Joint  
Andre Eu-Jin Cheah,  
Jeffrey Yao  
294–305

- Scapular and Shoulder Girdle Muscular Anatomy: Its Role in Periscapular Tendon Transfers  
Matthew M. Crowe,  
Bassem T. Elhassan  
306–314

- Journal CME Questions  
315

- Online Patient Ratings: Why They Matter and What They Mean  
Samir K. Trehan, Aaron Daluiski  
316–319

- Brachial Plexopathy Following Wrist Arthroscopy  
Taylor Buckley, Randall W. Culp  
320–322

## THE JOURNAL OF HAND SURGERY (ASIAN-PACIFIC VOLUME) (2016 VOL. 23 ISSUE 1)

- New Title and New Face of Our Journal  
Goo Hyun Baek  
pp. 1-1

- The New Smartphone Application for Wrist Rehabilitation  
Giuseppe Matera,  
Chinnakart Boonyasirikool,  
Raul Saggini,  
Alessandro Pozzi,  
Loris Pegoli  
pp. 2-7 7

- Endoscopic  
L. Pegoli,  
A. Pozzi,  
G. Pivato  
pp. 8-12

- Hand Injury in Rock Climbing: Literature Review  
Pozzi,  
G. Pivato,  
L. Pegoli  
pp. 13-17

- Cast Immobilisation versus Wire Fixation in the Management of Middle-aged and Elderly Patients with Distal Radius Fractures  
Robert Warner Jordan,  
Rahil Naeem,  
Saqiba Jadoon,  
Helen Parsons,  
Gunaratnam Shyamalan  
pp. 18-23

- Interobserver Agreement and Intraobserver Reproducibility of Barzullah Working Classification of Distal End Radius Fractures among Orthopaedic Residents  
Younis Kamal,  
Hayat Ahmad Khan,  
Naseem UI Gani,  
Munir Farooq,  
Adil Bashir Shah,  
Mohammad Ashraf Khan  
pp. 24-29

- Radiologic Changes by Early Motion in Neck Fractures of the Fifth Metacarpal Treated with Antegrade Intramedullary Fixation  
Youn Moo Heo,  
Sang Bum Kim,  
Jin Woong Yi,  
Tae Gyun Kim,  
Byoung Gu Lim  
pp. 30-36

- Transcutaneous Peripheral Nerve Stimulation for the Treatment of Neuropathic Pain in the Upper Limb  
Sierakowski,  
S.S. Jing,  
J. Poel,  
D. Elliot  
pp. 37-43

- Isolated Muscle Transfer to Restore Elbow Flexion in Children with Arthrogryposis  
Takehiko Takagi,  
Atsuhito Seki,  
Yuka Kobayashi,  
Joji Mochida,  
Shinichiro Takayama

- pp. 44-48
- Congenital Anomalies of the Extremities Occurring in Siblings  
Takehiko Takagi,  
Atsuhito Seki,  
Joji Mochida,  
Shinichiro Takayama  
pp. 49-53
  - Evaluation of Factors Associated with Night Pain in Women Undergoing Carpal Tunnel Release  
Jeong Hwan Kim,  
Hyun Sik Gong,  
Hoyune Esther Cho,  
Jin Woo Park,  
Jihyeung Kim,  
Goo Hyun Baek  
pp. 54-58
  - Intramedullary Nail Fixation for Displaced and Unstable Distal Radial Fractures in Patients Aged 65 Years or Older  
Takuma Wakasugi,  
Ritsuro Shirasaka  
pp. 59-63
  - The Anatomical Relationship Between the Dorsal Cutaneous Branch of the Ulnar Nerve and the Ulnar Styloid Process with Variations in Forearm Position  
Hyung Suk Jung,  
Yong Beom Lee,  
Jae Sung Lee  
pp. 64-67
  - Relation of Lateral Antebrachial Cutaneous Nerve to the Volar Approach to Distal Radius
- Valerie H. Tan, Jr. ,  
Pei Yein Tong,  
Janice Liao,  
Han Jing Lee,  
Tun-Lin Foo  
pp. 68-71
- Reliability and Validity of the Japanese Version of the Michigan Hand Outcomes Questionnaire: A Comparison with the DASH and SF-36 Questionnaires  
Takashi Oda,  
Yukio Abe,  
Yasukazu Katsumi,  
Hiroyuki Ohi,  
Toshiyasu Nakamura,  
Katsunori Inagaki  
pp. 72-77
  - Motion Analysis of the Trapeziometacarpal Joint Using Three-dimensional Computed Tomography  
Tetsuya Kimura,  
Hiroaki Takai,  
Tatsuo Azuma,  
Koichi Sairyo  
pp. 78-84
  - Interposition Arthroplasty Versus Hematoma and Distraction for the Treatment of Osteoarthritis of the Trapeziometacarpal Joint  
Massimo Corain,  
Nicola Zampieri,  
Raffaele Mugnai,  
Roberto Adani  
pp. 85-91
  - Attritional Rupture of the Little Finger Flexor Digitorum Profundus Tendon in the
- Carpal Tunnel in a Patient with Acromegaly  
Munn Yi Tina Lee,  
Yeo Chong Jin  
pp. 92-94
- Osteoid Osteoma of the Radial Styloid Resembling de Quervain's Disease  
Zbigniew Chmiel  
pp. 95-98
  - Acute Compartment Syndrome in the Forearm with Trans-Ulnar Single Incision  
Taku Suzuki,  
Naoto Inaba,  
Kazuki Sato  
pp. 99-102
  - Osteochondroma of the Radial Tuberosity in Child  
Sang Rim Kim,  
Tae Jung Kim,  
Kyu Bum Seo  
pp. 103-108
  - Intraosseous Ganglion Cyst of Scaphoid: An Uncommon Cause of Radial Wrist Pain  
Abhijeet Ashok Salunke,  
Saranjeet Singh,  
Himanshu Kanani,  
Jimmy Chokshi,  
G.I. Nambi,  
Pradyumna Raval,  
Pathik Vala,  
Shantanu Jain,  
Sanjay Chaudhari,  
Amit Patel,  
Ramesh Panchal  
pp. 109-112
- Anatomic Variations of the Flexor Carpi Radialis Brevis: A Report of Five Cases  
Junichi Nagata,  
Yasuhiro Kojima,  
Kenshi Satomura,  
Toshiyuki Ishiko,  
Takashi Ajiki  
pp. 113-115
- ### JOURNAL OF HAND THERAPY VOL. 29, ISSUE 1 (2016)
- Hand therapy versus corticosteroid injections in the treatment of de Quervain's disease: A systematic review and meta-analysis  
Rocco Cavaleri,  
Siobhan M. Schabrun,  
Maxine Te, Lucy S. Chipchase
  - Evaluation of a home treatment program for cold hypersensitivity using a classical conditioning procedure in patients with hand and arm injuries  
T. Vaksvik,  
A. Ruijs, M. Røkkum,  
I. Holm
  - Kinesio taping and manual pressure release: Short-term effects in subjects with myofascial trigger point  
Yu Wen Chao,  
Jiu Jenq Lin,  
Jing Lan Yang,  
Wendy Tzyy-Jiuan Wang
- Early controlled mobilization using dart throwing motion with a twist for the conservative management of an intra-articular distal radius fracture and scapho-lunate ligament injury: A case report  
Lynne Feehan,  
Trevor Fraser
- Thirty Years of Hand Therapy: The 2014 Practice Analysis  
JoAnn L. Keller,  
Carla M. Caro,  
Mary P. Dimick,  
Keri Landrieu,  
Lynnlee Fullenwider,  
J. Martin Walsh
  - The Inter-rater Reliability of the Modified Finger Goniometer for Measuring Forearm Rotation  
Mike Szekeres,  
Joy C. MacDermid,  
Trevor Birmingham,  
Ruby Grewal
  - Clinical Manual Assessment of the Wrist  
Ann Porretto-Loehrke,  
Cassandra Schuh,  
Mike Szekeres
  - Orthotic intervention incorporating the dart-throwers motion as part of conservative management guidelines for treatment of scapho-lunate injury  
Hamish Anderson,  
Greg Hoy
  - Dart throwing motion with a twist orthoses: Design,
- fabrication and clinical tips  
Lynne Feehan,  
Trevor Fraser
- Adherence behaviour in an acute pediatric hand trauma population: A pilot study of parental report of adherence levels and influencing factors  
T. Cole,  
A. Underhill,  
S. Kennedy
  - Scaphoid Tuberosity Excursion is Minimized during a Dart-Throwing Motion: A Biomechanical Study  
Frederick W. Werner,  
Levi G. Sutton,  
Niladri Basu, Walter H. Short,  
Hisao Moritomo,  
Hugo St-Amand
  - The Effectiveness of Orthoses in the Conservative Management of Thumb CMC Joint Osteoarthritis: An Analysis of Functional Pinch Strength  
Marie-Lyne Grenier,  
Rochelle Mendonca,  
Peter Dalley
  - Coaching of patients with an isolated minimally displaced fracture of the radial head immediately increases range of motion  
Teun Teunis,  
Emily R. Thornton,  
Thierry G. Guitton,  
Ana-Maria Vranceanu,  
David Ring



● Differences in Active Range of Motion Measurements in the Upper Extremity of Patients with Writer's cramp (WC) Compared with Healthy Controls  
Prachaya Srivanitchapoom, Ejaz A. Shamim, Pierre Diomi, Takaaki Hattori, Sanjay Pandey, Sherry Vorbach, Jung E. Park, Tianxia Wu, Sungyoung Auh, Mark Hallett

● Letter to the editor: Robot training for hand motor recovery in subacute stroke patients: A randomized controlled trial  
Jorge Hugo Villafañe, Alberto Borboni, Pedro Berjano

● An Alternative Fabrication Method of the Dart Thrower's Motion Orthosis (also known as the Dart Splint)  
Deborah A. Schwartz

● The Challenge of the Mallet Orthosis: A Simple Solution  
Daniel Harte

● Comparative study of millennials' (age 20-34 years) grip and lateral pinch with the norms  
Elizabeth Fain, Cara Weatherford

● Therapeutic taping for soft tissue-based digit malrotation  
Kimberly A. Masker

● Reproducibility: Reliability and Agreement of short version of Western Ontario Rotator Cuff Index (Short-WORC) in patients with rotator cuff disorders  
Neha Dewan, Joy C. MacDermid, Norma MacIntyre, Ruby Grewal

● Rehabilitation strategies for wrist sensorimotor control impairment: From theory to practice  
Christos Karagiannopoulos, Susan Michlovitz

● Development and reliability of a Turkish version of the Short Form-Joint Protection Behavior Assessment (JPBA-S)  
Eda Tonga, Songul Atasavun Uysal, Sedef Karayazgan, Mutlu Hayran, Tülin Düger

● Validation of Duruöz Hand Index in patients with tetraplegia  
Tugce Ozekli Misirlioglu, Halil Unalan, Safak Sahir Karamemetoglu

### JOURNAL OF WRIST SURGERY ISSUE 01 • VOLUME 05 (FEBRUARY 2016)

● Volar and Dorsal Rim Fractures of the Distal Radius  
David J. Slutsky  
p001

● Distal Radius Volar Rim Fracture Fixation Using DePuy-Synthes Volar Rim Plate  
Amir Reza Kachooei, Matthew Tarabochia, Jesse B. Jupiter,  
p002

● Fixation Options for the Volar Lunate Facet Fracture: Thinking Outside the Box  
Neil G. Harness,  
p009

● Prevent Collapse and Salvage Failures of the Volar Rim of the Distal Radius  
Jorge L. Orbay, Francisco Rubio, Lauren L. Vernon,  
p017

● Fragment-Specific Fixation for Fractures of the Distal Radius  
William B. Geissler, Sonja M. Clark,  
p022

● The Effect of Displaced Dorsal Rim Fragment in a Distal Radius Fracture  
Jae Kwang Kim, Yeo-Hon Yun, Dong Jun Kim,  
p031

● Ultrasound Imaging Improves Identification of Prominent Hardware in the Surgical Treatment of Distal Radius Fractures: A Cadaveric and Prospective Clinical Study  
Jacqueline D. Watchmaker,

Roger A. Daley, Greg P. Watchmaker, Steven I. Grindel,  
p036

● Dorsal Tear of Triangular Fibrocartilage Complex: Clinical Features and Treatment  
Yukio Abe, Atsushi Moriya, Yasuhiro Tominaga, Koji Yoshida,  
p042

● The Effect of Scaphoid Fracture Site on Scaphoid Instability Patterns  
Frederick W. Werner, Hugo St-Amand, Hisao Moritomo, Levi G. Sutton, Walter H. Short,  
p047

● Intra-articular Fractures of the Sigmoid Notch of the Distal Radius: Analysis of Progression to Distal Radial Ulnar Joint Arthritis and Impact on Upper Extremity Function in Surgically Treated Fractures  
Mark A. Vitale, David M. Brogan, Alexander Y. Shin, Richard A. Berger,  
p052

● ScaphoLunate Axis Method  
Jeffrey Yao, Dan A. Zlotolow, Steve K. Lee,  
p059

● Epidermal Inclusion Cyst after Carpal Tunnel Release: A Case Report  
Ho Youn Park, Yoo Joon Sur, Yoon Vin Kim,  
p067

● Scaphoid Proximal Pole Fracture Following Headless Screw Fixation  
Schneider K. Rancy, Jonathan A. Zelken, Joseph D. Lipman, Scott W. Wolfe,  
p071

● Acute Monoarthritis of the Wrist Joint: Tuberculosis or Not?  
Prabha Desikan, Rahul Verma, Karuna Tiwari, Nikita Panwalkar,  
p077

● Volar Central Portal in Wrist Arthroscopy  
F. Corella, M. Ocampos, M. Del Cerro, R. Larrainzar-Garijo, T. Vázquez,  
p080

## IMPORTANT ANNOUNCEMENT ZIKA VIRUS INFORMATION

IFSSH AND IFSHT CONGRESS: ARGENTINA - OCTOBER 2016

Worried about Zika on October 2016?

Aedes Aegypti mosquito causing Zika is extremely rare in Buenos Aires. Up to March 2016 we had only 16 cases confirmed of Zika in Buenos Aires, all contracted in other countries (no autoctonous). During winter in Argentina (June-September) the mosquitoes die due to low temperatures. Mosquitoes can reappear with high temperatures (usually beginning in December). Therefore the probability of getting the disease in October is extremely low.

D.G. Carla M. Cometto  
AACM Secretaría Curso de Junio y Congresos  
IFSSH & IFSHT Congress - Buenos Aires 2016  
www.ifssh-ifsht2016.com · www.aacmyrms.org

Asociación Argentina de Cirugía de la Mano  
Riobamba 919 1ºB C1116ABC  
Buenos Aires | Argentina  
Tel. 54 11 48113596

# 4th EUROPEAN HAND INJURY PREVENTION CONGRESS



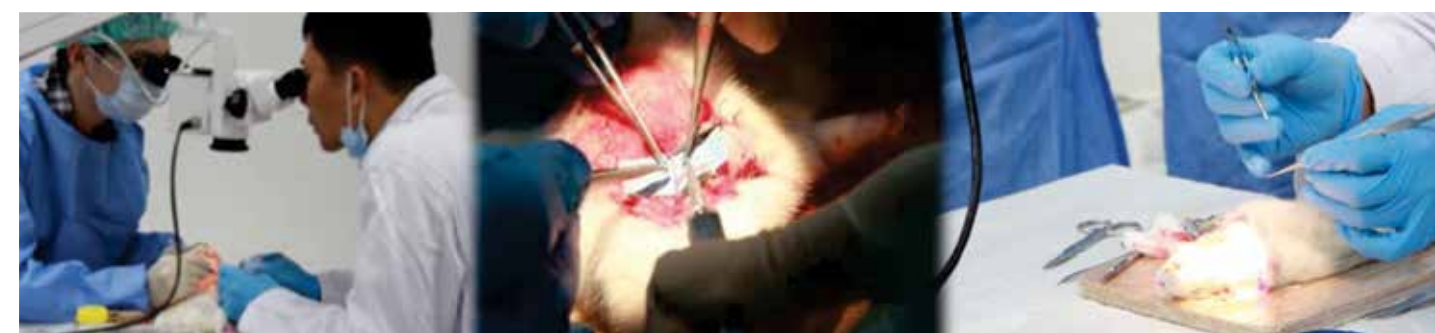## SECOND ANNOUNCEMENT

**19-20 September 2016**  
**Oxford, UK**

[www.handprevention2016.org](http://www.handprevention2016.org)



Under the patronage of FESSH



## CUHK - OLC Surgeon Education Program: The 5<sup>th</sup> Advanced Microsurgery Course June 10-14, 2016

### Course Outline

- End-to-end anastomosis: femoral artery (posterior-wall-first anastomotic technique)
- End-to-side anastomosis: femoral artery to the side of the carotid artery
- End-to-side anastomosis: jugular vein to side of carotid artery
- End-to-end anastomosis: femoral vein (continuous anastomotic technique)
- Kidney transplantation

### Guest Speaker

Dr Ping-tak Chan

### Program Director

Dr Wing-lim Tse

### Program Instructor

Dr Edmund Cheung

### Accreditations (TBC)

HKCOS: 10 CME, 10 TP

CSHK: 18 CME

HKCORL: 12 CME

### Course Fees

HKD 9,000

### Venue

Orthopaedic Learning Centre  
Prince of Wales Hospital  
Hong Kong

### Registration Deadline

May 10, 2016

### Program Rundown & Registration Form



Organized by:



Supported by:



### Course Secretariat

Ms Charis Lau  
Tel: (852)2632 1654  
Fax: (852)2647 7432  
Email: [olc@ort.cuhk.edu.hk](mailto:olc@ort.cuhk.edu.hk)  
[www.olc-cuhk.org](http://www.olc-cuhk.org)





Website to be out soon



May 2016

UPCOMING EVENTS

# 11th Congress of the Asian Pacific Federation of Societies for the Surgery of the Hand

**CEBU, City  
PHILIPPINES  
NOV 7-10, 2017  
Radisson Blu  
Hotel**

**7th APFSHT  
Congress**



## COMPREHENSIVE REVIEW



Featuring a special one-day course:  
**AAOS/ASSH General Orthopaedic Review**

The [Comprehensive Review](#) course is your home for advanced review and updates on the latest research. Covering anatomy, biomechanics and pathology as well as diagnostic and treatment methods, this course examines the **full spectrum of upper extremity surgery** so you walk away with all the tools you need to stay on top of your game.

[Join us](#), along with our faculty of recognized international experts in hand surgery, in the exciting city of Chicago. Between the jam-packed program and the sites and sounds around town, not a minute of your time will be wasted.

**Chair:** Michael R. Hausman, MD

**Co-chair:** Scott D. Lfchez, MD

**Faculty:** Julie E. Adams, MD; Kodi Azari, MD; Leon Benson, MD; Martin I. Boyer, MD, FRCS(C); David J. Bozentka, MD; Ryan P. Calfee, MD, MSc; John C. Elfar, MD; Warren C. Hammert, MD; Peter E. Hoepfner, MD; Thomas B. Hughes, MD; Sanjeev Kakar, MD; Jason Ko, MD; Terry R. Light, MD; Jaimie T. Shores, MD; Scott P. Steinmann, MD; Jonathan Tueting, MD and Dan A. Zlotolow, MD.

### OBJECTIVES:

Upon completion of this course, the participant will be able to:

- Discuss the relevant concepts of anatomy, biomechanics and pathology relating to surgery of the hand, wrist and elbow.
- Prescribe and use generally accepted diagnostic techniques required to evaluate various disease preventions.
- Describe treatment alternatives for acquired, traumatic, inflammatory, congenital, metabolic and neoplastic disorders of the hand, wrist and elbow.

But wait, there's more...



## GENERAL ORTHOPAEDIC REVIEW

Be sure to include the [AAOS/ASSH General Orthopaedic Review](#) in your registration! This additional fee program is held the day before the Comprehensive Review course (July 14) and is a lively and convenient program with all of the generally accepted principles of orthopaedics. Our skilled faculty knows what you need to know and will give a focused, straightforward review of the other orthopaedic specialty areas.





# Mão 2016

36th Brazilian Congress of Hand Surgery

*The olympic hand*

May 26th to 28th, 2016  
Maksoud Plaza São Paulo - Brazil

## INVITED SPEAKERS



Alexander J. Davit  
III



A. Lee  
Osterman



Amanda Tritsch



Francisco A.  
Schwartz-Fernandes



Jairo Fernando  
Gomez Ramirez



Jennifer Teeters



Karl-Josef  
Prommersberger



Mark Rekant



Ronaldo Carneiro



Steven M. Zinder



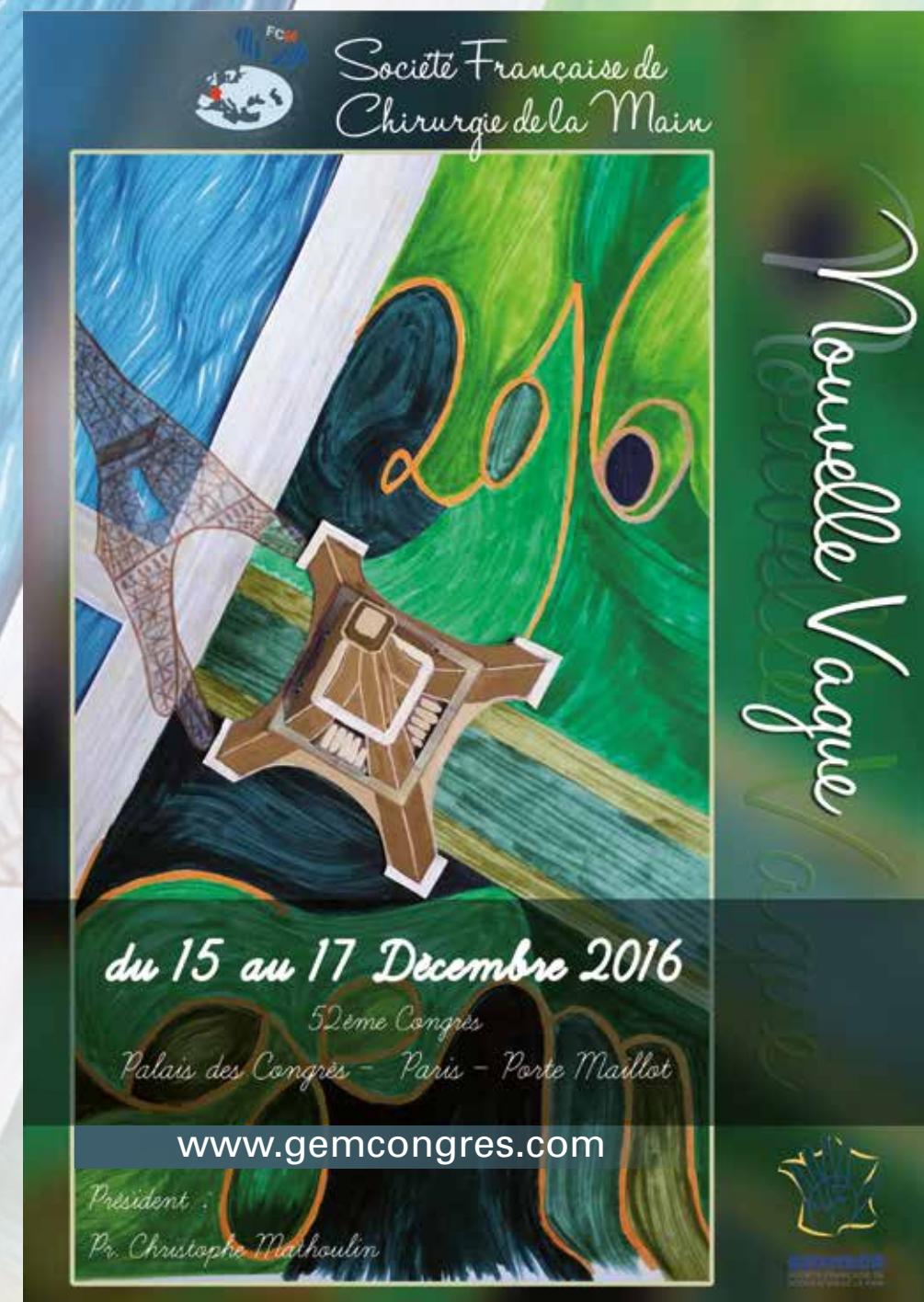William Alvarez Mejia

Site [www.mao2016.com.br](http://www.mao2016.com.br)



Executive Secretariat: 55 11 5081  
7028  
[mao@fernandapresteseventos.com.br](mailto:mao@fernandapresteseventos.com.br)

Organization



Dear friends,  
I will have the honour of chairing the French Society for Surgery of the Hand in 2016. During my medical training I was fortunate enough to have some very exceptional surgeons as masters who guided me and gave me the opportunity to develop my skills in scientific expression, research and teaching. This is why, to pay tribute to my masters I have decided to hand over our 2016 congress as a « gift » to our youngest members. Our congress is called « The New Wave ». I have invited some foreign lecturers who seem to remain eternally young! Marc Garcia-Elias, Diego Fernandez, Francisco Del Pinal and Gustavo Mantovani. Traditionally we also invite a « non-surgeon ». I have asked my good friend Gaël Chauvet, a great sommelier, who has selected the wines at the prestigious Lavinia winery since it was created and who is friendly with all the best wine-growers to give us a lecture on « The hand of the wine-grower »... I'd be prepared to bet that there will be more wines and wine-makers than hands... Everything is ready to make our 2016 congress a successful one! I hope you will all be there!

Christophe Mathoulin  
President SFCM 2016





The programs for the Pre-Congress Course and the FESSH2016 Congress are available on the congress website !

You can register for the **Pre-congress Course: "What is cool in Wrist Surgery"**

You can register for the **Congress**

Have a look at the schedule of the buses for the shuttle service **Bilbao-Santander-Bilbao airport!**

***Looking forward to welcoming you in Santander!***

**Technical Secretariat:**

Afid Congresos, S.L.

C/ Menéndez Pelayo, 6 Entlo. A-39006 Santander, Spain

Tel.: [+34 942 318 180](tel:+34942318180) - Fax: [+34 942 318 653](tel:+34942318653)

Email: [info@fessh2016.com](mailto:info@fessh2016.com)

**For further information:** [www.fessh2016.com](http://www.fessh2016.com)



Spring in Buenos Aires!

**Make your plans to attend  
the first World Congress in South America**

**IFSSH 50<sup>th</sup> Anniversary**



Buenos Aires

**Argentina**

13<sup>th</sup> **2016** 10<sup>th</sup>

**IFSSH & IFSHT  
Triennial Congress**

**24<sup>th</sup> - 28<sup>th</sup> October**

**[www.ifssh-ifsht2016.com](http://www.ifssh-ifsht2016.com)**

