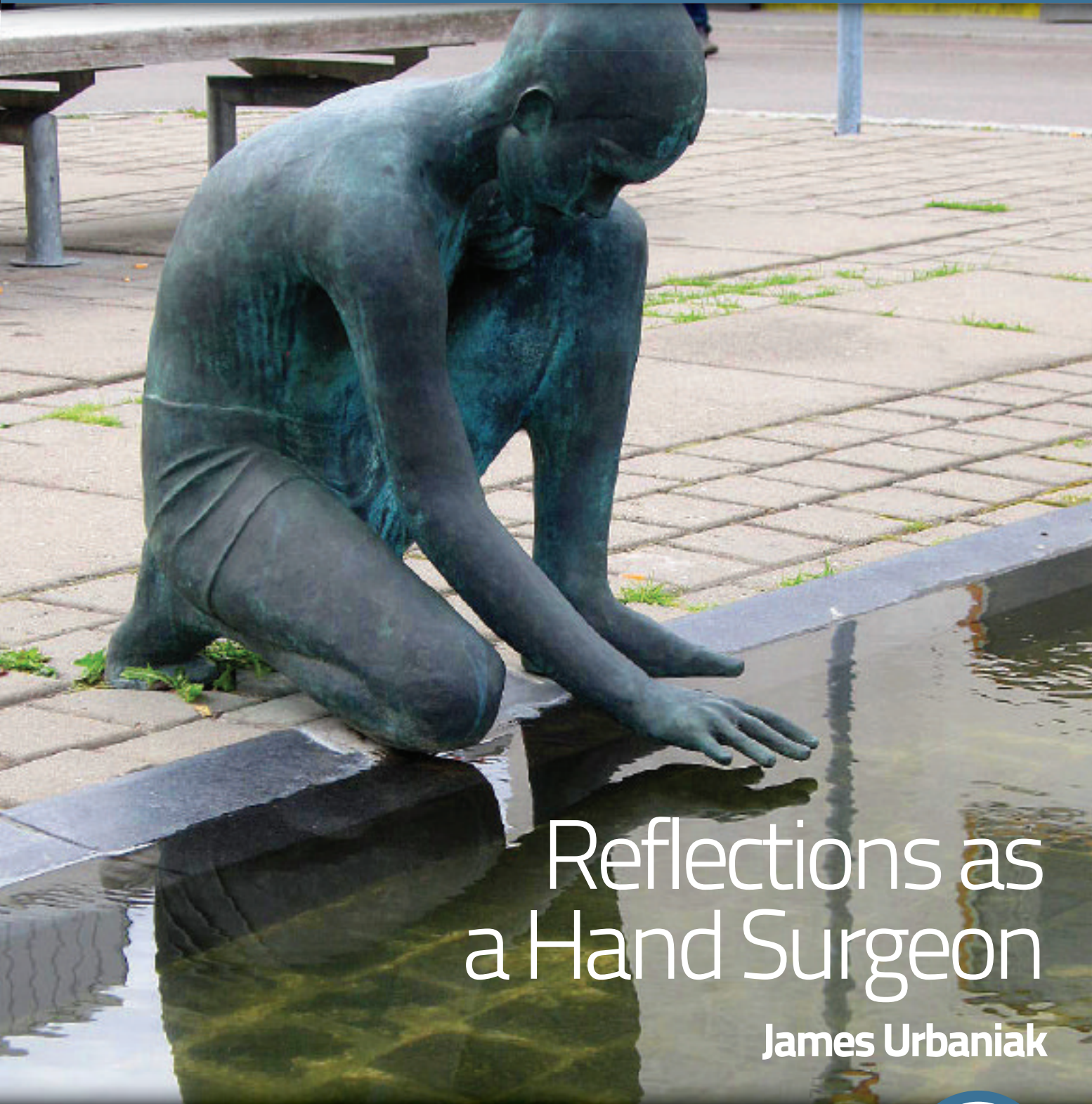

ezine ifssh

CONNECTING OUR GLOBAL HAND SURGERY FAMILY

Journal Highlights
Executive News
Member Society Updates




Reflections as a Hand Surgeon

James Urbaniak

IFSSH SPORT
COMMITTEE REPORT

EVELYN MACKIN -
A HAND THERAPY PIONEER





Angular stable fixation of ulna shortening osteotomies.

LCP Ulna Osteotomy System 2.7.

Optimized Plate Design

The low profile plate with tapered ends reduces the risk of soft tissue irritation and hardware related patient discomfort. The plate is available in two lengths: 6 and 8 holes.

Precise Instrumentation

System specific instrumentation like Parallel Saw Blades and Drill Templates allow to perform a secure and accurate osteotomy cut, for transverse cuts as well as for oblique cuts between 2 and 5 mm width.

Freehand Technique

Additionally available Compression/Distract Instrument to facilitate freehand technique application especially in shortenings more than 5 mm.



4 Editorial

By Professor Ulrich Mennen, editor of the IFSSH ezine
Letter to the editor
Obituary: Harold Kleinert
Living Textbook of Hand Surgery

8 Executive news

- Newsletter from the Secretary-General:
Marc Garcia-Elias

10 Member society updates

- Egyptian Society for Surgery of the Hand and Microsurgery
- French Society for Surgery of the Hand
- Indian Society for Surgery of the Hand
- Bangladesh Society for Surgery of the Hand
- Colombian Society for Surgery of the Hand

12 Special feature

- Reflections as a Hand Surgeon
James R. Urbaniak, M.D.

16 Pulse

- Treatment of fracture dislocations of the PIPJ
- IFSSH Sport Committee Report

30 Hand therapy

- Evelyn Mackin - A Hand Therapy Pioneer

32 Research Roundup

- Management of keloids and hypertrophic scars: current and emerging options
- The relationship between displacement and clinical outcome after distal radius (Colles') fracture

35 Pioneer profiles

- Raymond Curtis
- Adrian Flatt

38 Journal highlights

- Tables of Content from leading journals such as The Journal of Wrist Surgery, The American Journal of Hand Surgery, Journal of Hand Surgery Asian Volume, Journal of Hand Surgery European Volume and the Journal of Hand Therapy.

41 Upcoming events

- List of global learning events and conferences for hand surgeons and therapists

Reflections

It is always prudent to stand still on occasion and reflect on what one is engaged with, lest we become one-track minded and irrelevant.

Many such examples come to mind, such as 'doing research, for research sake', forgetting the original aim to solve a problem or question.

Another example is the urge to publish, perhaps driven by the so-called 'sword of Damocles', also known as 'publish or perish'. Why else is it, that the majority of submitted articles to medical scientific journals are rejected because of poor quality and lack of substance?

As we are going into our fourth year of 'ezining', it is also time to stand still and reflect on the importance and relevance of this publication. Have we succeeded in our endeavour to spread, share and inform our colleagues internationally, on issues pertaining to the hand?

In every issue we had a section encouraging readers to give feedback. We find this feedback essential because it not only tells us what is wanted by the readers, but it keeps us in touch with the subscribers.

Hence, the desire from the editors to reflect on the relevance of the ezine.

Please reply and send us your comments, criticisms and contributions to: **ezine@ifssh.info**. Your input will be most appreciated.

The editorial team would like to use this opportunity to wish you all a meaningful festive season, and for those who take a vacation, hope you gain renewed passion for our chosen profession in the New Year.



With sincere regards,
Professor Ulrich Mennen, Editor
Immediate Past-President IFSSH
November 2013

PS: This issue's cover photo is of a statue at a reflecting pool in front of the General Hospital in Stockholm, Sweden

IFSSH disclaimer: The IFSSH ezine is the official mouthpiece of the International Federation of Societies for Surgery of the Hand. The IFSSH does not endorse the commercial advertising in this publication, nor the content or views of the contributors to the publication. Subscription to the IFSSH ezine is free of charge and the ezine is distributed on a quarterly basis. To subscribe, please **click here**. Should you wish to support this publication through advertising, please **click here**.

IFSSH ezine editorial team:

Editor: Professor Ulrich Mennen (Immediate Past President of the IFSSH)

Deputy Editor: Professor Michael Tonkin
(President of the IFSSH)

Publication coordinator:
Marita Kritzing (Apex ezines)

Graphic Designer: Andy Garside



Dear Editor,

In response to the analogy survey posted in the February 2013 IFSSH ezine, I use the following to explain scar tissue to my patients: "scar tissue" is like an iceberg you only see 10% on top, the remaining 90% is adhering to tendons, ligaments and soft tissue underneath limiting motion

Regards, **Annabel Heeney** OTR/L, CHT, USA

Living Textbook of Hand Surgery: an update

The concept of the Living Textbook of Hand Surgery was introduced at the German OER-Conference in Berlin, hosted by Wikimedia Germany at September 14th – 15th. Philipp Schmidt from the MIT Media Lab and Neil Butcher/ South Africa were keynote speakers and they illustrated the impact of free accessible and shared knowledge. While most of the projects discussed focused on education for children or students, the Living Textbook was acknowledged as one of the first projects for higher education in a specialised subject. The presentation sparked a debate about the technical tools, financing and realisation with a worldwide team of contributors. Richarda Böttcher (Editor), Wolfgang Müller (gms) and Rolf Winands-Böttcher (Handchirurgie weltweit e.V.) received helpful suggestions for the project.

The entire presentation (in German) is available [here](#)

News and progress about the Living Textbook of Hand Surgery will be announced in every upcoming issue of the IFSSH ezine.

Richarda Boettcher

Handchirurgie Weltweit e.V.

richarda.boettcher@hand-ww.de



Rolf Winands-Böttcher, Richarda Böttcher and Wolfgang Müller
at the OER-Conference, Berlin, September 15th

Harold Kleinert

(1921-2013)

There will be much written and spoken by many of the extraordinary career and achievements of Harold Kleinert, and correctly so. For me, the essence of the man lies within my memories. These are some of those.

My first exposure to Dr Kleinert was as a fellow in hand surgery at the Derby Hand Unit in 1982, later to become the Pulvertaft Hand Centre. Frank Burke, a previous 'Kleinert fellow', was in charge. Dr Kleinert was the Visiting Professor at the Derby Hand Course, a week of morning lectures and afternoon surgery performed by the master to an audience of perhaps 50 or so registrants. I was responsible, along with my fellow colleagues, for preparing and presenting the surgical cases, two of which were to be operated upon by Dr Kleinert each afternoon. It became clear by the third afternoon that our esteemed Professor had no intention of completing more than one operation each afternoon, no matter what time we began or what time was available for us to continue surgery. Not a word was spoken on the matter; come 4pm each day the second case was quietly cancelled. The steely determination was apparent behind the soft exterior.

One of the most enjoyable components of the course was the nightly game of darts over a pint of best Bass bitter at the New Inn, Frank's

local, where we would find ourselves after surgery and before the formal evening functions. Each player would be given three darts with which to throw a 'double' to allow that player to begin the game. Before each and every game, Harold drawled "well I'll just take one dart" as one throw was all he needed to throw the double and begin the game. The course ran for four days, Monday to Thursday. On Thursday evening he had yet to begin a game. The sense of humour never lessened in spite of the repetition of these same words before each game.

Prior to the course I had written to Graham Lister applying to train in Louisville. I was instructed to seek an interview with Dr Kleinert at the time of his visit to Derby. I was shy and reluctant to approach the "great man" in spite of Frank Burke's encouragement and, unbeknown to me, a word in Dr Kleinert's ear earlier in the week. During the last moments of the course I plucked up the courage to request an interview. The response was: "Well, I've been interviewing you all week and we look forward to seeing you in Louisville". The gentle smile and the twinkle in the eye announced the deliberateness of his teasing of me.

The recollections of my time as a fellow in Louisville in 1984/85 are too numerous to recount adequately. Some are best spoken of over dinner

and wine and some best left for even later in the night. Harold Kleinert could be a bit of a rogue. He would regularly leave a crowded clinic at lunch time for a 'meeting', which may have involved turning over the engines of his many cars parked in the Jewish Hospital car park. The fellows would wait as did those in the waiting room for Dr Kleinert to return to clear the clinic rooms, just as we would wait late at night, well after the clinic had finished, so that the English grammar of our letters to referring doctors could be corrected. However, the last patient was always seen and treated with the same gentle care and courtesy as the first, even if that patient did not require specific care for a hand condition but simply had need of some of Harold Kleinert's time and had little other enjoyment in life other than to wait for those moments.

One morning, when working on Dr Kleinert's team, I and another had completed a 10 hour all-night mid-palmar replantation, finishing at 7:45am. Dr Kleinert suggested that I 'help him' by operating on the first elective case of the day, a carpal tunnel release. The 15 minute operation lasted 90 minutes as I added, at Harold's request, a flexor synovectomy, a sub-epineural saline injection to determine the presence of epineural fibrosis, an epineurotomy

with loupe magnification and finally a revision of this procedure with use of the operating microscope, all with well-rested team members looking on. I was being tested. Within this story lies one of Harold Kleinert's greatest strengths, that being the ability to obtain the best from those about him. He gathered in Louisville some remarkable and independently-minded individuals of disparate character, in my time, Joe Kutz, Graham Lister, Don Atasoy, Tom Wolfe, Tsu-Min Tsai and, of course, the extraordinary Bob Acland. These were complemented by wonderful therapy, nursing and administration personnel. Harold managed to get them all to do things for him.

In Derby in 2004, I returned for Frank Burke's retirement celebration. Two of Frank's teachers, Harold Kleinert and Adrian Flatt, delivered key note addresses, the former speaking on "My first 50 years of flexor tendon surgery" and the latter on "My life as a resident medical officer in London during the Blitz (of World War II)". One evening I followed Harold and Adrian as the faculty walked to a pub for



refreshments. They were arm in arm, walking with almost incongruous gaits, one with a languid mid-Western saunter, the other with an upright, rigid, military posture, but somehow in complete harmony. "How old are you Adrian?" asked Harold. "I am 83" replied Adrian. "Well, so am I. What month were you born?" "August" was the response. "Well you are the senior, as I was born in October – therefore you have to enter the pub in front of me, which means you have to buy the first round of beers." We were only having one beer, of course, before attending

an organised dinner.

I last saw Harold Kleinert when I was invited as the Kleinert and Kutz Visiting Professor to Louisville in 2009. This warm-hearted, kind man and his wife Sharon hosted a dinner at their Jeffersonville farm, at which a proud Harold drew me aside and escorted me to an outhouse to show off the largest pumpkin he had grown. Having stopped work at age 87, he confided that retirement was the worst job he had ever known. That was Harold Kleinert, a man of grace, gentleness, humour and determination, sometimes a rogue, always loveable,

whose legacy extended beyond the 1200 plus fellows fortunate enough to have trained in Louisville, to the many thousands subsequently taught by Kleinert fellows in all corners of the world.

I join with Sharon, Harold's family and all of us who knew him in a celebration of the life of Harold Kleinert.

Michael Tonkin

*Australian Hand Surgery Society
President, International Federation of
Societies for Surgery of the Hand*

Newsletter from the Secretary-General

Dear Friends,

If you live in the Northern hemisphere, the hot summer time is over, your kids are back to school, and everything you put aside last July is still there on the desk waiting for your return. If you live in the South, recovering from a freezing dark season, October probably is still a catch up month for you. In both cases, welcome back.

We do not need to catch up this year. We didn't go away! If this secretary had a motto, it could have been: "The IFSSH is always there, for the Northern and the Southern hemisphere", but no, we don't have a slogan. We don't take vacation from the IFSSH either - we have delegates to attend to. Regardless of whether the National Delegate calls from a sun drenched country, or from a winter abused one, if there is a call we are there at the other end of the line to take that call. Why? Because that call comes from the most important person in our organisation: the National Delegate. Indeed, the National Delegate is the key element in our Federation, the messenger bringing news from our true members, the Hand Societies. Without that call, our Membership would not know what is going on around the world of Hand Surgery. Without that call, we would not know if there is a hand surgeon out there in need of our

support. Without that call, our world would be less global. Believe me, do not hesitate to contact us. We are always there!

What do we do with that call? Imagine a crossroad with as many converging highways as National Societies. The IFSSH Council is in the centre, overlooking that huge and complex "Place de l'Étoile", making sure that all converging roads get adequate traffic support. When your call brings information worth being distributed, we make sure that all roads simultaneously get that information without any delay. If a call for help arrives through one of those roads, resources are sought to satisfy that request. If a road gets silent, messengers are sent in that territory

Please send your reports and, above all, make sure that all your colleagues get a copy. The ezine is the most efficient, inexpensive way of sharing information regarding hand related activities.

to investigate why. Yes, the IFSSH is centrally located to ensure that nobody gets isolated.

And to move along all those roads we have the Ezine. Do not underestimate the efficacy of spreading the news from your society using this tool. It needs not to be validated again. It works! If you had the best car in your garage, wouldn't it be unwise not to drive it? Please, send your reports and, above all, make sure that all your colleagues get a copy. The Ezine is the most efficient, inexpensive way of sharing information regarding hand related activities.

Remember that there are thousands of photos of the last congress in India available through our website here [<http://ifssh-ifsht2013.com/gallery1.php>]. You may get printable high resolution copies of those you like by sending a message to the webmaster at info@krithitechnologies.com, indicating the code or codes of the pictures you like

The Committee for Educational Sponsorship (CES) has already presented requests for educational bursaries and grants using the simplified guidelines recently implemented. Make sure the members of your societies do not miss this opportunity. You will find information on the website (www.ifssh.info).

Concerning the upcoming meeting

of our Federation, in Buenos Aires, the local organising committee is working hard to ensure that everybody leaves the country with more than fond memories of a magnificent city. The venue, the programme, the scientific content, the social events... nothing will be taken for granted. As Secretary-General, I will have the first on-site meeting with the organising committee next month. I am sure everything will be all right. Remember that the meeting will be held on October 10-13, 2016 in Buenos Aires, Argentina - www.ifssh-ifsht2016.com.

Aside from this, please remember that our next Delegates' Council Meeting will be held in Paris during the FESSH meeting of June 18-21, 2014. For those wanting to attend the congress of our sister organization, see here [<http://www.fessh2014.com/en/welcome>]

Yes, the Northern summer is over, but we may still dive in the warm swimming waters of George Gershwin's "Summertime": "One of these mornings, you're going to rise up singing. Then you'll spread your wings and you'll take to the sky". Yes, I can see the IFSSH wings spreading.

Marc Garcia-Elias

Secretary-General, IFSSH

Email: secretary@ifssh.info

November 2013



Member society updates

Egyptian Society for Surgery of the Hand and Microsurgery

- The ESSHM is a relatively young society that has been growing. Now it has approximately 125 active members.
- The society concentrates its effort on educational activities.
- The society started a programme for reaching out to different communities throughout Egypt. So, on a monthly basis the society arranges for a special hand surgery educational programme in different cities in Egypt, which has been very popular and successful. It has been instrumental in educating orthopedic and plastic surgeons as well as primary care physicians.
- This year's annual meeting for ESSHM was held in Cairo on May 9-10, 2013. The meeting was well attended.
- An upcoming international hand surgery meeting is scheduled for November 20-22, 2013 in Hurghada which is a beautiful resort on the red sea. The meeting is co sponsored by the ESSHM and Sohag University. Several international guest speakers have accepted our invitation to attend. For information please visit <http://www.handsurgery-sohag.org/> or email congress@conf-x.com
- The Annual Mediterranean Wrist conference has been held in Alexandria since 2007. It is one of the most popular educational programmes that the society sponsors. The last one was held on September 20th, this year and its main topic was Distal Radius Fractures.
- Many of the members of the ESSHM participated in the IFSSH annual congress in Delhi, India with several podium presentations and posters.
- Several of the ESSHM members participated in other European and International meetings including the annual meeting of the American Society for Surgery of the Hand.
- The current political environment in Egypt has been a challenge to the society in pursuing its educational objectives. But the educational activities continued in spite of the difficult circumstances that the society had to endure.

We are hoping that the situation in Egypt will continue to improve to make it an attractive site again for combined meetings with other international societies.

Nash H Naam, MD, FACS, FICS

IFSSH representative of the Egyptian Society for Surgery of the Hand and Microsurgery

The French Society for Surgery of the Hand

The French Society for Surgery of the Hand (SFCM) will celebrate its 50th anniversary next December. The annual meeting will take place in Paris (Palais des Congrès Porte Maillot) from the 19th to the 21st December. Professor Dominique Le Nen from Brest, will be the president of this particular meeting while professor Gilles Dautel from Nancy will become the new President of our society.

For this special event the society organizes, on Friday the 20th, a diner to honor the pioneers of our society Jacques Duparc, Jacques Michon, Pierre Rabischong, Raoul Tubiana and Raymond Vilain, who created the "Groupe d'Etude la Main" (GEM), in June 1963, which became the French Society for Surgery of the Hand. The dinner will take place in a wonderful historical place: l'Hôpital du Val de grâce in Paris.

The tiny group of five brilliant surgeons became in 50 years a dynamic scientific society of 550 members. In 2013 the spring meeting held in Grenoble gathered young hand surgeons around the finger tendinous lesions repair. In 2014 a 'young member' status will take place in our society to encourage the youngest to be more and more involved in our society activities.

Our general secretary, Jean-Luc Roux, and I invite you to join our different meetings and conferences. Notice that SFCM will host the next European Federation of Societies for Surgery of the Hand (EFSSH) meeting in Paris from the 18th to 21st of June 2014. We all wish to meet you there.

François Moutet, SFCM President

The Indian Society for Surgery of the Hand

The Indian Society for Surgery of the Hand held its annual meeting at the Industrial City, Pune in Maharashtra from the 20th to 22nd September, 2013. The International Guests for this year's meeting were Prof. C. Oberlin from France and Prof. R. Adani from Italy. Prof. Oberlin delivered the BB Joshi Oration on his approach to Spastic Hand and Prof. R. Adani delivered the Prof. R. Venkataswami Oration on the Surgical Reconstruction of the traumatised thumb. This was a combined congress of surgeons and therapists. The next year's meeting will be at Mangalore from the 14th November to 16th November, 2014.

Bangladesh Society for Surgery of the Hand

The Bangladesh Society for Surgery of the Hand organised a peripheral nerve course (workshop and demonstrations) for surgeons at the NITOR(National institute of orthopaedics) and BSMMU(University) from 1- 4 July in which 77 surgeons participated.

This was followed by a micro-nerve repair course from 5-6 July in the Plastic Surgery Department at the Dhaka Medical College, in which 10 hand surgeons participated in the course. The course was conducted by hand surgeon Dr V. Rajaratnam from England.

Dr Alam


Colombian Society for Surgery of the Hand



Dr Hernando Laverde-Gutiérrez, IFSSH Colombian Delegate, President of the Colombian Association for Surgery of the Hand and Chief of the Hand Surgery Service at the Central Police Hospital in Bogotá, Colombia, Was awarded by the Ministry of National Defense - General Direction of the National Police with the Distinguished Service Medal.



Dr Ricardo Mario Galan Suarez, General Secretary of the Colombian Association for Surgery of the Hand received the title of Professor Emeritus of aesthetic, plastic and reconstructive surgery in the Central Military Hospital in Bogota



Dr Raúl Sastre Cifuentes past President of the Colombian Association for Surgery of the Hand is the new dean of the faculty of medicine at the National University of Colombia

Reflections as a Hand Surgeon

James R. Urbaniak, M.D.

At the Triennial Congress of the IFSSH-IFSHT in New Delhi, India in March of 2013, Raja Sabapathy, the Programme Chairman, requested that I present a vignette on the reflections of my career as a hand surgeon. I was truly honoured to be invited to deliver this presentation to this audience of international friends. However it was a difficult assignment, for I was instructed to reflect on my life accomplishments and regrets, so to speak. We all know that one of the major principles of speaking is to make minimal use of the words "I" and "me" so this was an arduous task when asked to address reflections on my life, but I gave it a try, and will record some of these efforts in this writing.

First I have been blessed with grandparents and parents who taught me the meaningful values of life – mainly one of service. The title 'doctor' is derived from the Latin verb 'docere' which means to teach. Personally I believe that I could only serve as a teacher, coach, or a doctor. My greatest professional satisfaction has been the opportunity to teach residents and fellows, which I will later address.

"The joy of our first successful thumb replant which was retrieved from the bottom of a lake more than four decades ago remains very fresh in my mind as if it occurred yesterday – so exhilarating"

However my greatest accomplishment in life has been to marry my wife, Muff, a Duke Nurse – no question about it.

That being established, the three most gratifying rewards in my profession have come from microsurgery, teaching, and leadership positions.

1. My passion for microsurgery has been most rewarding. I want to make it clear that few, if any, of my ideas, techniques, procedures, publications, or lectures have been totally original. Although I was a self-taught microsurgeon, I was greatly influenced by giants in microsurgery – Buncke, O'Brien, Morrison, Zjong Wei Chen, Kleinert, and Kutz to name a few. The joy of our first successful thumb replant which was retrieved from the bottom of a lake more than four decades ago remains very fresh in my mind as if it occurred yesterday – so exhilarating. The successful reattachment of the hand of a 25 year old electrician more than three decades ago that enabled him to return to fine and skillful manipulation in his vocation with a normal appearing hand and essentially normal

intrinsic and extrinsic function was also so rewarding. It doesn't get any better.

The exhilaration that is experienced from a free tissue transfer such as a toe-to-thumb, "wrap-around", and a free vascularised fibular graft for avascular necrosis of the femoral head (of which we performed over 3500) is always really gratifying. The thrill of seeing the flow of blood through an anastomosed vessel transcends to life by engaging the flow of many other activities of work and play – this engaging flow causes forgetting oneself and thinking of other's needs and not worry; and therefore be more productive as well as being happy - to paraphrase the Hungarian psychologist Mihaly Csikszentmihaly.¹

2. Without a doubt the greatest reward for being in academic surgery is the opportunity to train residents and fellows. I have been fortunate to have been involved in the training of 328 residents, 124 hand fellows, and 81 international research fellows from more than 20 countries. Honestly, I have learned way more from them than they have from me. Many of these relationships have been long lasting as

I've proudly followed their contributions worldwide over five decades.

3. I have been fortunate to serve as President or Chairman of several national and international organisations – including the IFSSH. The titles, positions, or recognition are important, but what is more rewarding is the development and maintenance of lasting relationships from these positions of service. These offices have involved a lot of work and commitment – but as an old Turkish proverb states "No road is long with good company" and I

certainly have been surrounded by great international company. We have cultivated many lasting friends around the globe through a bond of trust – the major bond of a lasting friendship. This bond of trust plays a dominant role in our international alliances in medicine – too bad it is not more genuine in the international political world. We in medicine have an international creed – service.

What Have I Missed?

Certainly some family time – but we accepted the demands of medical





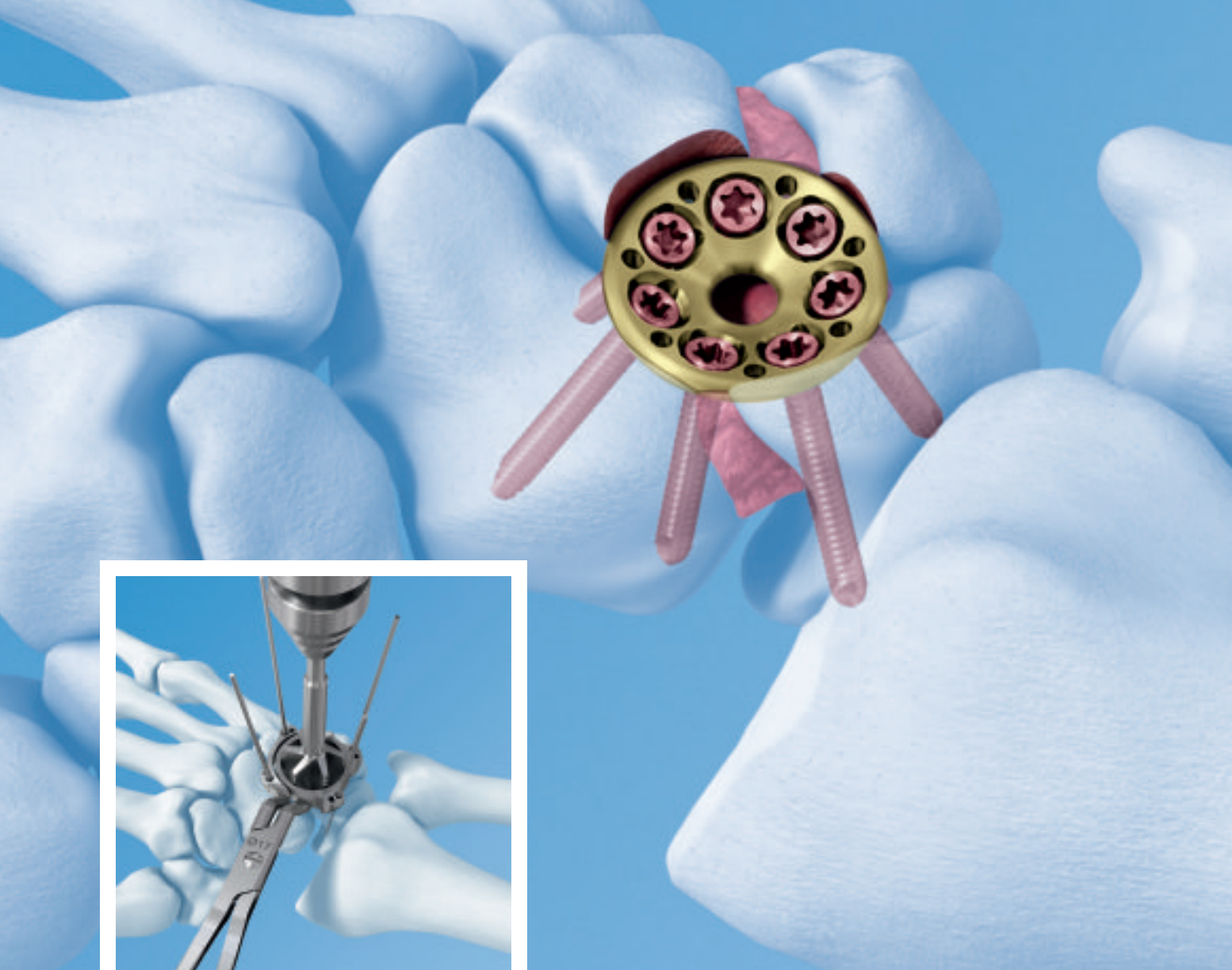service as part of our family life. As far as play time, I have never distinguished between work and play. "Having fun is doing hard work well" as an old coach once said.² I've really enjoyed being a doctor, surgeon, especially one who performs microsurgery, and by the way I get paid for it. Studies show "Happy People Live Longer." Through my practice, I have learned people first want to know how much you care before they care how much you know. I've tried not to offend others – you only lose – it's a waste of time, especially if they can help you in the future. The best way to get rid of your enemies is to make them your friends.

Finally, in response to the question if I had it to do over what would I change? Well, I believe you have to play with the cards you were dealt. You can't in all fairness change them.

Yes, I've had some failures along the way but I hope that I have learned from them. You are not really a failure until you begin to blame others or situations. When things went wrong in our clinical work, or research we pointed the finger to ourselves and became better from the experience. Medicine, surgery has been good to me – a real joy. As Jonas Salk stated, "one of the best rewards for achieving some success is it puts you in a position to do more".³ Therefore, I hope my greatest accomplishment is yet to come. I realise this presentation has been personal, and for this I apologise, but it is my way of saying thanks to so many international friends, especially those involved in hand and microsurgery.

References

1. Csikszentmihaly, M: Finding Flow: The Psychology of Engagement with Everyday Life. Basic Books, New York, NY, April 6, 1998.
2. Bilas, J: Toughness. New American Library, New York, NY, March 13, 2013.
3. Salk, J, Anshen, RN: Anatomy of Reality. Columbia University Press, New York, NY, March 1, 1983.



Variable angle locking technology for mediocarpal partial arthrodesis. VA-Locking Intercarpal Fusion System 2.4.

Low profile plates

The plates are especially designed for fixation of four corner arthrodesis and feature a low profile design with rounded edges to minimize the risk of soft tissue irritation. They are available in two sizes (\varnothing 15 mm/6 holes and \varnothing 17 mm/7 holes) and have K-Wire holes incorporated to allow temporary fixation of the plate.

Variable angle locking technology

The 2.4 mm variable angle locking screws can be angled up to 15° off axis and provide a strong angular stable construct. Also, 2.4 mm Cortex screws can be used to apply compression.

Innovative Instrumentation

System specific instruments like Reduction Reaming Guides additionally support the surgeon during procedure. The fusion site is fixed during the whole procedure and if desired, compression can be applied with the instrument.

Treatment of fracture dislocations of the PIPJ

By Prof SL Biddulph, University of the Witwatersrand, Dr LG Biddulph, Head of the Hand Unit, Chris Hani Baragwanath Hospital, Dr M Carides, Hand Unit Charlotte Maxeke Hospital, Prof JF Fleming, Hand unit, Chris Hani Baragwanath Hospital.

Introduction

This injury often occurs in sportsmen. It is purported to occur in 10 per 100,000 patients. Kang and Stern called it a common injury although in our experience it is not that common. In the Hand Unit at the Chris Hani Baragwanath Hospital in Johannesburg, which has an annual patient load of 10,000, there were only two cases seen for surgery over a period of two years. There is often a delayed presentation of between two and four weeks and is often misdiagnosed as a 'jammed finger'.

Classification

Fracture-dislocations of the proximal interphalangeal joint (PIPJ) can be classified into three groups depending on the morphology (Kang and Stern 2002). PIPJ report: (Figure 1)

In our experience fractures are usually due to a combination of forces rather than a pure unidirectional impact. Fractures of the volar lip are usually associated with a combination of axial and extensor forces resulting in dorsal dislocations of the PIPJ. Those involving the dorsal lip are associated with axial and flexor forces

and result in a tendency towards volar instability. Pilon fractures involve compression with depression of the middle phalangeal articular fragments, are comminuted, with multi-planar instability. Of these the volar lip fractures are most common.

Fractures with minimal displacement or less than 30% of the articular surface involvement result in good functional results whereas those with gross architectural disturbance create havoc and present the treating surgeon with an immense challenge, hence the plethora of techniques

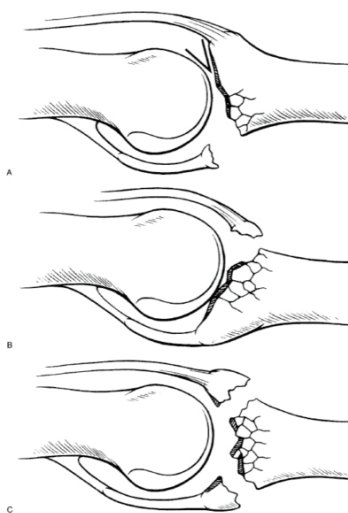


Figure 1: A. Volar lip fractures.
B. Dorsal lip fractures
C. Pilon fractures

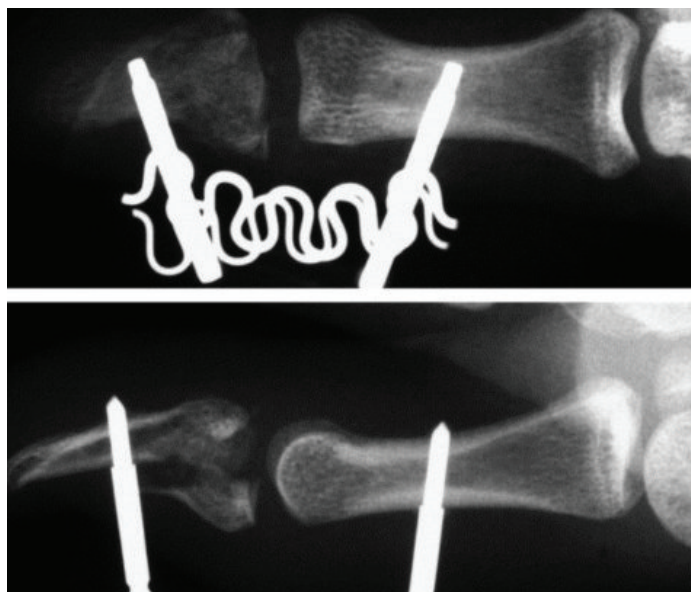
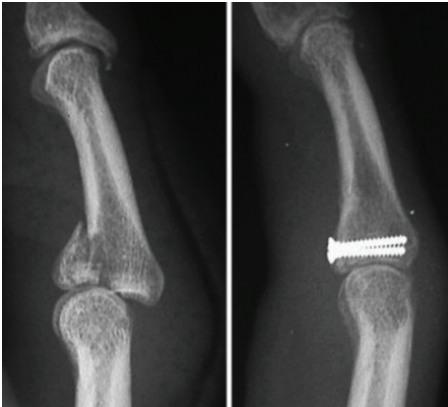


Figure 2 Khan and Fahmy

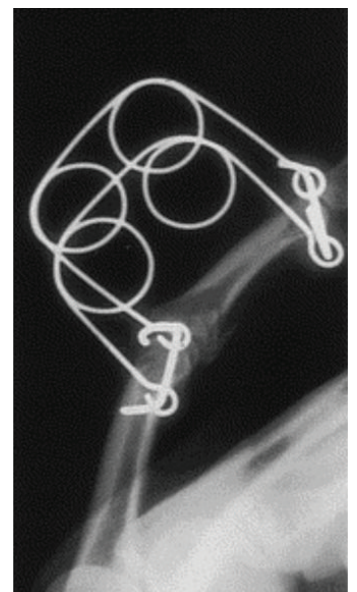

Figure 3 Johnson et al

Figure 4 Lee and Teoh

described in the past. The long term results may be mediocre with loss of motion and pain frequently compromising function.

However the common themes that are found in all articles is that a stable concentric reduction and early mobilisation leads to the best results.

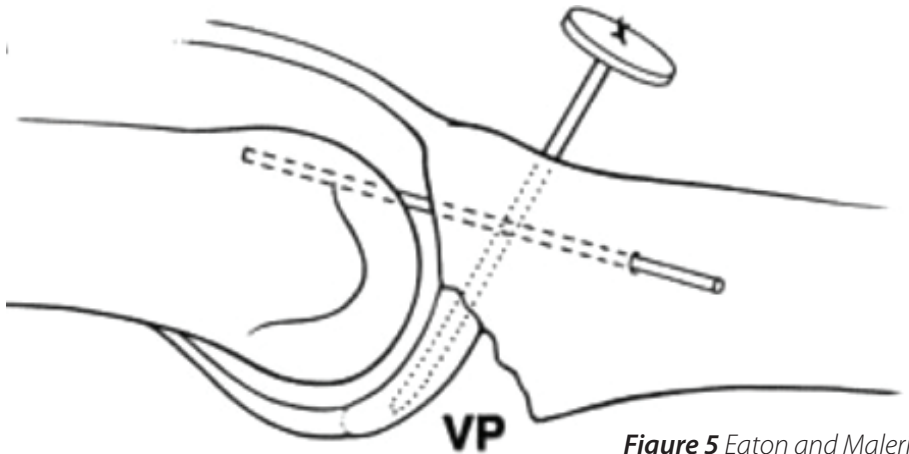
Historical background

Injuries with minimal displacement and bony damage or instability respond well to a short period of splinting and early mobilisation with buddy splinting.

More severe injuries require more intense measures. Many complicated and intriguing devices were designed to provide continuous traction such as the Suzuki frame (1994) or blocked extension. Figure 2 and Figure 3 (Khan Fahmy 2006 and Johnson et al 2004)

In cases with no loss of bony support these contraptions may have been effective. Cases with loss of bony support, for instance where the cancellous bone constituting the base of the middle phalanx has been impacted and distorted, no amount of traction will restore normal bony architecture.

These cases require open reduction and internal fixation. When the dorsal

**Figure 5** Eaton and Malerich

or volar lip fracture is of sufficient size an interfragmentary screw fixation technique would be indicated (Figure 4 Lee and Teoh).

However many fracture-dislocations do not fall into this category. Comminution and impaction are common and there may be no sizable fragment to accept a screw. In more chronic cases where the volar bony defect is severe the lost volar lip and

buttress needs to be substituted in some way. Eaton in 1980 described his operation where the detached volar plate is advanced distally and reattached to the base of the middle phalanx to fill the defect. (Figure 5)

Unfortunately dorsal subluxation often recurred. A more solid and substantial tissue was required. In 1999 Hastings et al described a technique where the condyle of the hamate that articulates with the base of the 5th metacarpal is used to replace the volar lip. This avascular cartilage-covered segment of bone is fixed into position using screws (Figure 6).

More recently, these cases (Figure 7) have been found to be adequately fixed using a buttress plate and screws (Biddulph, Chew).

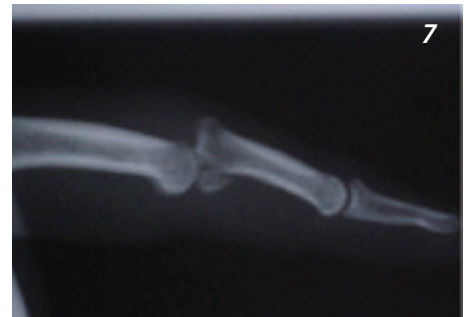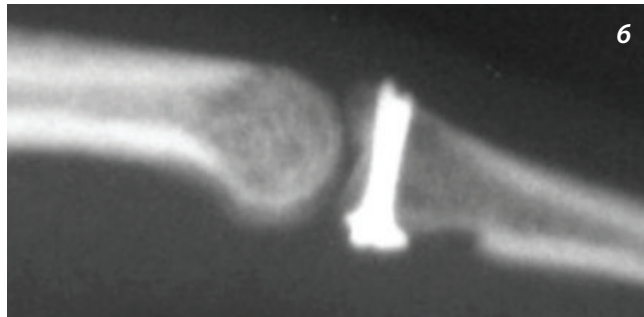
Technique

A closed reduction of the joint is performed and if it is unstable it can be fixed using one or two K-wires. The k-wire should be inserted with the joint reduced but under some distraction to allow room for replacement of the fragments.

For a volar lip fracture the joint is exposed via a volar Brunner approach. The flexor sheath over the base of

“Fractures with minimal displacement or less than 30% of the articular surface involvement result in good functional results whereas those with gross architectural disturbance create havoc and present the treating surgeon with an immense challenge”

Figure 6 Hastings et al
Figure 7 Biddulph 2007



the middle phalanx is sacrificed (A3 and C2 pulleys). The Flexor Digitorum Profundus is retracted and the volar plate and the fracture site are exposed between the two slips of Flexor Digitorum Superficialis.

The various fragments are reduced, often facilitated by windowing the volar plate to see the articular surface especially if elevation of the central fragment is required. Adequate reduction restores stable bony architecture allowing concentric movement of the joint.

Fixation is accomplished by use of a low profile plate and locking screws which serve as a buttress plate, akin to volar plating of Barton fractures of the distal end of the radius.

The screws find purchase in the dorsal cortex of the phalanx. If K-wires are used to maintain reduction of the joint they are removed approximately two weeks later and mobilisation commenced with.

This technique has been used successfully in cases up to four months post injury although the ideal timing is immediately after the injury. Late cases may require more extensive dissection in order to achieve a successful reduction.

Accurate placement of the volar fragment may then also be difficult or even impossible. An inadequate

reduction may still be preferable to a bone graft. These delayed cases usually have a poor prognosis.

In cases with dorsal impaction and volar dislocation, a dorsal exposure and plating is performed. The plate is placed over the central slip insertion to buttress the dorsal fragment. It is prudent to reinforce the central slip attachment with a suture around the plate.

In severe cases with substantial bone fragmentation and instability, it may not be possible to achieve perfect reduction. However, it is imperative to restore bony architecture. These patients may develop secondary arthritis in later years. In those patients who become candidates for an arthroplasty, it is advantageous to have good bone stock and near normal anatomy on which to perform the procedure.

*This report is dedicated to my teacher –
Alfred B. Swanson.*

Syd Biddulph

References

1. Biddulph SL. 2007 Presentation at the IFFSH congress. Sydney, Australia.
2. Chew YC, Cheah AE. Volar plate and screw fixation for dorsal fracture-dislocation of the proximal interphalangeal joint. Case Report Journal of Hand Surgery 2010; 35A:928-930
3. Eaton RG, Malerich MM. Volar plate arthroplasty for the proximal interphalangeal joint: a ten year review. J Hand Surg 1980; 5:260-268.
4. Hastings H, Capo J, Steinberg B, Stern P. Hemicondylar hamate replacement arthroplasty for proximal interphalangeal joint fractures/dislocations (abstr). Presented at the 54th Annual Meeting of the American Society for Surgery of the Hand, Boston, MA, 1999.
5. Johnson D, Tiernan AM, Richards AM, Cole RP. Dynamic external fixation for complex intra-articular phalangeal fractures. Journal of Hand Surgery 2004; 29B; 1:76-81
6. Kang R, Stern PJ. Fracture-dislocations of the proximal interphalangeal joint. Journal of the American Society for Surgery of the Hand 2002; 2; 2:47-59
7. Khan W, Fahmy N. The S-Quattro in the management of acute intra-articular phalangeal fractures of the hand. The Journal of Hand Surgery 2006; 31B:79-92
8. Lee JYL, Teoh LC. Dorsal fracture dislocation of the proximal interphalangeal joint treated by open reduction and interfragmentary screw fixation; Indications, approaches and results. Journal of Hand Surgery 2006; 31B; 2:138-146
9. Suzuki Y, Matsunaga, T, Sato S, Yokoi T. The pins and rubbers traction system for treatment of comminuted intra-articular fractures and fracture-dislocations in the hand. Journal of Hand Surgery 1994; 19B; 1:98-107

IFSSH Sport Committee Report

By Loris Pegoli, Alejandro Badia, Gregory Bain,
Moroe Beppu, Riccardo Luchetti

The IFSSH Sports Injuries Committee is a new committee with a focus on sports related injuries, aetiology, prevention and treatment. This report will cover a literature review and a review of the principles of injuries of the PIP joint.

Sport related injuries to the wrist and hand

Sport related injuries to the wrist and hand are often discussed, but from a scientific point of view, what it is really known about this subject and what has been published?

This was the question on which the Sport Committee based its work. Before starting to describe various conditions, we wanted to provide a review of the literature to see what was published. This helped to identify the sports and their injuries about which more was written and those that are not.

The following were the criteria used:

Search engine: PUBMED, OVID

Keywords: Sport Trauma, Hand Trauma, Wrist Trauma, Sport

The keywords were restricted so that the papers identified were

specifically localised to sport related injuries of the hand. From our search we identified 116 papers in 63 journals, describing 46 different sports published from 1979 till 2012. Figure 1 shows the distribution of papers over this period of time.

The anatomical region described were as shown in Table 1, the structures involved as shown in Table 2 and the sports as shown in Table 3.

Table 1

Anatomical region	# of papers
WRIST	80
CARPUS	79
PHALANX	78
METACARPAL	73
ELBOW	37

Table 2

Structures involved	# of papers
BONES	80
TENDONS	76
LIGAMENTS	69
SOFT TISSUES	47
NERVES	39
VESSELS	33

As can be seen, there are many papers published on sports injuries of the hand and wrist. They cover many different sports and many types of injuries of the various anatomic components of the hand and wrist. Publications were common for the wrist, carpus, phalanges, and metacarpals. Publications of injuries to the bones, tendons and ligaments were all common.

Although the publications were quite wide and varied, it is unlikely that this represents an indication of the sports with a higher incidence of injuries, severity of the injuries in any given sport, or the distribution of injuries with any given sport.

Many of the papers highlight specific conditions that can occur in various sports (eg ulnar nerve palsy in the hand in cycling; chronic exertional compartment syndrome of the forearm in motorcyclists)

This review revealed that digit ligament lesions are among the injuries with a higher incidence. For this reason we describe the sport conditions

related to the proximal interphalangeal joint in this report.

Athletic injuries of the proximal interphalangeal joint

Proximal interphalangeal (PIP) joint injuries are common in athletes, frequently overlooked and can greatly impair athletic performance in many disciplines. The clinical and radiological assessment of these injuries will be presented. The principles and options of treatment are outlined. The complications and their possible prevention are discussed.

The PIP joint is the most important joint in the hand because of its ideal location and range of motion. For this exact reason, even mild injuries can greatly impair athletic activity. Injuries to this joint will produce stiffness, pain and occasional instability. Many of these injuries commonly occur in athletes and are initially thought to be trivial and managed by a coach or trainer. The colloquial term ‘jammed

finger’ is often heard in playgrounds and the athletic field, unfortunately then similarly used to describe the injury in the emergency room setting. Others use the term ‘stoved finger’.

The conforming shape of the PIP joint provides stability, which prevents translation and rotation while allowing a generous arc of motion. The stability of the PIP joint is greatly enhanced by the ligamentous support which surrounds the joint. The collateral and accessory collateral ligaments are densely adherent to the lateral margins of the volar plate to produce a three-dimensional ligament-box complex. It is felt that the PIP joint is predisposed to injury because the middle phalanx is an intercalated segment within the finger. When a force is applied to the finger, the distal and middle phalanges act as a lever arm on the PIPJ. Any axial compression or lateral deviation force applied to the finger is likely to produce a PIP joint injury.

The PIP joint is a hinge joint with

a range of motion of approximately 110°. The average functional range of motion is 19-71°, 23- 87° and 10-64° for the MCP, PIP and DIP joints. The average functional arc of motion is 48%, 59% and 60% of active range of motion for the three joints. Any patient with a PIP joint injury which encroaches on the functional range of motion (23-87°) will have a potential disability (Bain et al 1997,1999). This fact has more obvious bearing on athletes requiring manual dexterity and/or strength, as well as manual occupations. Furthermore, a severely impaired single PIP joint injury can then impair overall hand function compromising the athlete, particularly in sports requiring grip of a small diameter object such as a tennis racquet, cricket bat or golf club. The implication is even more obvious in athletes who must make a tight fist, such as boxing or sailing.

Assessment of the patient with a PIP joint injury

Table 3

Sport			
GENERIC	27	SNOWBOARD	3
SOCCER	11	SKATING	2
FOOTBALL	7	RODEO	2
GYMNASTIC	7	SWIMMING	2
ROCK CLIMBING	7	CHEERLEADING	2
TENNIS	7	CYCLING	2
BOXING	6	HURLING	2
SOFTBALL	4	HOCKEY	2
MOTOCROSS	3	ALPINE SKATING	1
GOLF	3	ARCHERY	1
PADDLE SPORTS	3	BADMINTON	1
RACQUET SPORTS	3	BASEBALL	1
WEIGHTLIFTING	3	BASKETBALL	1
THROWING SPORTS	3	CRICKET	1
		CROQUET	1
		DANCING	1
		ENDURO	1
		SHOOTING	1
		HORSERIDING	1
		KENDO	1
		KICKBOARD	1
		MARTIAL ARTS	1
		RALLY DRIVERS	1
		ROWING	1
		RUGBY	1
		SHOOTING	1
		SPORT FISHING	1
		SQUASH	1
		SURFING	1
		ORIENTERING	1
		VOLLEYBALL	1
		WRESTLING	1

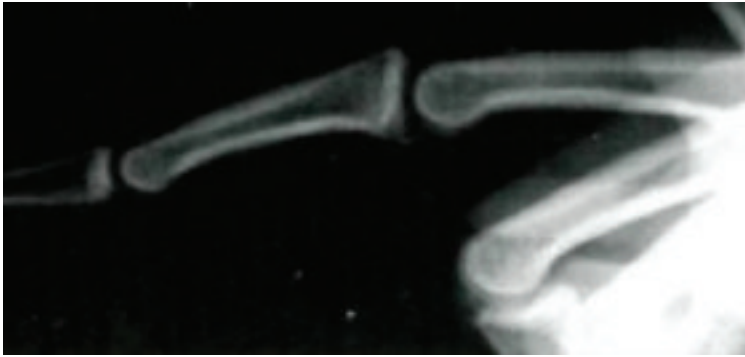


Figure 1. Dorsal PIP joint fracture-subluxation.

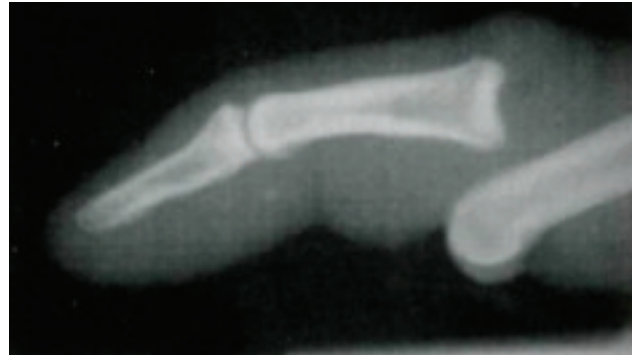


Figure 2. Radiograph of dorsal PIP joint dislocation.

A thorough history, including an understanding of the requirements of the PIP joint should be obtained, (e.g sport, employment and hand dominance). The mechanism of injury, initial treatment and the delay to presentation should be elicited. Most PIP joint injuries are caused by hyperextension and axial loading resulting in impaction of the volar articular surface of the middle phalanx against the condyles of the proximal phalanx (Eaton & Malerich 1980). The athlete should also be questioned whether pulling on the digit was performed by teammate or trainer, or an actual reduction was attempted/performed on site. This can provide evidence that even further trauma may have been induced.

On examination the posture and swelling of the finger should be noted along with any deformity, including malrotation. The PIP joint can be thought of as having four quadrants: volar, dorsal, radial and ulnar. The exact site of swelling and tenderness should be determined. Swelling and tenderness volarly would indicate a volar plate injury, dorsally a central slip injury, and laterally a collateral ligament injury. Gross appearance will reveal if there is any angulation or

"Proximal interphalangeal joint (PIP) injuries are common in athletes, frequently overlooked and can greatly impair athletic performance in many disciplines"

joint subluxation/dislocation, whether dorsal or rarely, volar.

Stability of the PIP joint should be assessed. A metacarpal local anaesthetic block will aid in assessment by providing comfort for the patient and preventing flexor spasm which may mask joint instability (Eaton 1971). Stability of the joint is first assessed by having the patient actively flex and extend the finger. If the patient can complete a full range of motion without subluxation or dislocation, it implies that the joint is functionally stable. The assessment of the last 20° of extension is the most

critical, because in this portion the joint is most likely to be unstable (Eaton 1971). Passive stability is assessed by applying stress to each collateral ligament in both extension and 30° of flexion (Minamikawa et al 1993). The volar plate is tested by passively hyperextending the PIP joint. The stability is compared to adjacent and contralateral fingers. This portion of the examination is particularly helpful if performed under fluoroscopic control, usually after plain radiographs.

Radiographs of the finger should always be performed in the assessment of PIP joint injuries. It is important that the radiographs be taken of the finger and not just the hand, so that subtle abnormalities can be identified. A true lateral radiograph of the finger is mandatory as it enables assessment of subluxation and the common volar lip fracture (Figure 1). As mentioned, in complicated cases, fluoroscopy to dynamically assess the stability of the joint and can give much better assessment of articular fractures. This exam usually precludes the need for CT evaluation and helps understand the 'personality' of the fracture.

Volar plate injuries

The thick, strong fibrocartilaginous

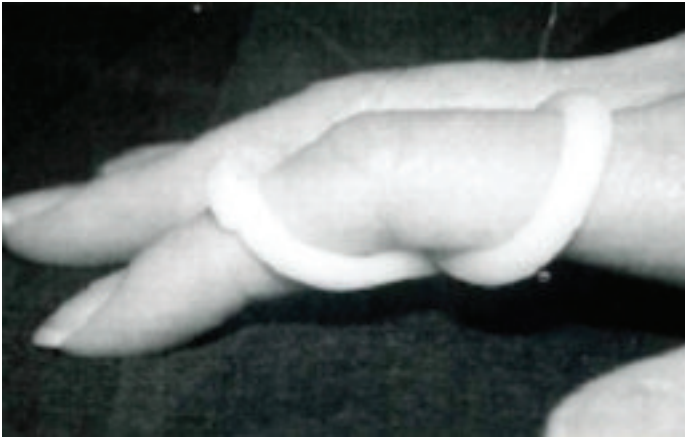

Figure 3. Figure of 8 Extension block splint

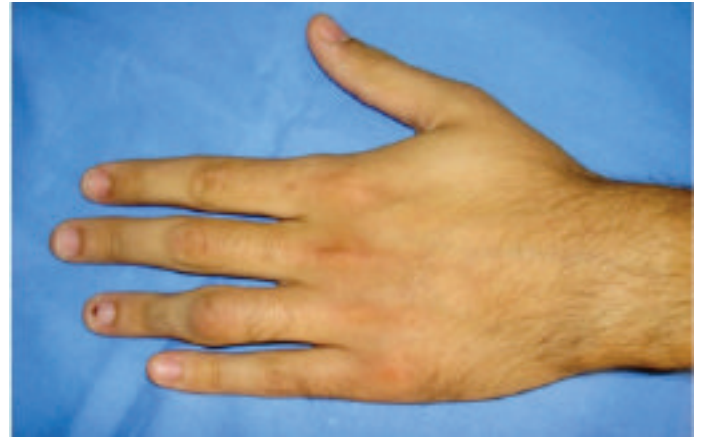

Figure 4. Swollen ring finger PIP joint.

volar plate forms the floor of the PIP joint. With the accessory collateral ligaments it provides stability from 15° of flexion to full extension, even if the collateral ligaments have been excised (Bowers 1987). The volar plate becomes tight in extension and prevents hyperextension. Injuries to the volar plate occur following forced hyperextension (e.g. ball sports) in which it is avulsed from the base of the middle phalanx (Eaton 1971; McElfresh et al 1972). With greater hyperextension a split develops between the collateral and accessory collateral ligaments, and the finger will posture in marked hyperextension (Dray & Eaton 1993). With further hyperextension the PIP joint will dislocate, with the middle phalanx dorsal to the proximal phalanx in the 'bayonet' position (Figure 2). For dislocation of the proximal phalanx to occur, at least two sides of the ligament-box complex must be disturbed (Eaton 1971).

The finger will be swollen and tender over the volar quadrant of the PIP joint. Following a metacarpal block, the passive range of hyperextension will be more than the adjacent fingers.

Radiographs are often normal, except for the soft tissue swelling.

Treatment of dislocations and volar plate injuries (with or without small bony fragments) consists of mobilisation while protecting the finger from hyperextension during the healing phase. If the contralateral PIP joint hyperextends more than 10° the patient will usually regain motion quickly, and is therefore provided with an extension block figure splint for two to four weeks to prevent hyperextension and subsequent swan neck deformity (Fig 3). Patients who do not have laxity of the contralateral PIP joints are mobilised with buddy taping

as they are more prone to develop stiffness. It is important that the patients be reviewed at one and two weeks with true lateral radiographs to ensure that they are making satisfactory progress.

The athlete should not return to ball sports while the finger is still tender. Elite athletes often will return despite the finger remaining swollen and tender. They should wear buddy tape for a further three months, if the finger remains a problem. The patient should be warned that there may be a prolonged recovery and that the finger may be permanently swollen (Figure 4).

With the addition of an axial load, the volar plate will be avulsed with a fragment of bone, which is often impacted and comminuted (Liss & Green 1992). The stability of the joint following a fracture-dislocation is dependent upon the size of the volar fragment. If the fracture has disrupted greater than 40% of the volar articular surface, the shaft can sublux dorsally because the collateral ligament is attached to only the volar segment (Figure 5). As these injuries are most stable in flexion, some authors have advocated the use of extension block

“early involvement of the hand specialist is crucial to maximise clinical outcome in managing these daunting injuries in the sportsman”

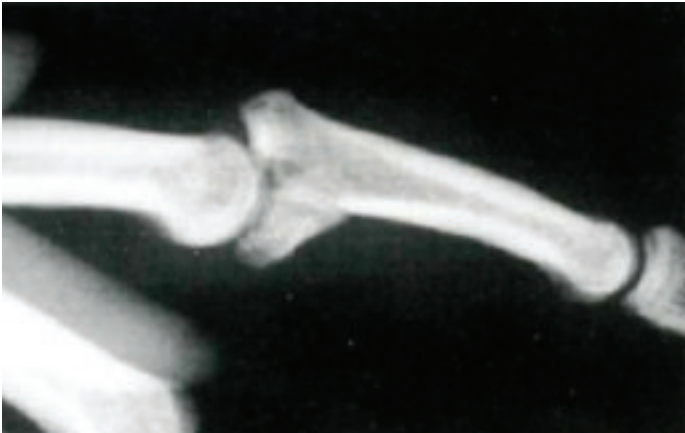

Figure 5. Dorsal PIP joint fracture-subluxation

splints (Dray & Eaton 1993; McElfresh et al 1972). In complicated cases, repair, reconstruction or salvage options will need to be considered.

Abnormal rotation of the finger indicates a condylar fracture or interposition of soft tissue or bone. The abnormal rotation is best observed clinically (Figure 6) but can be diagnosed with radiographs if a lateral view of the proximal phalanx and an oblique view of the middle phalanx are seen on the same radiograph. The head of the proximal phalanx can button-hole through the rupture in the volar plate and become locked between the two flexor tendons (Bowers 1987). The volar plate, collateral ligament or osteochondral fracture can also block reduction. A widened joint space, seen on the lateral radiograph, may indicate interposition of soft tissue. An open reduction is required if closed reduction is unsuccessful.

Reduction of the dislocated PIP joint is performed with the aid of a metacarpal block. Longitudinal traction is applied to the finger, which is then manipulated. Once the deformity is corrected, the finger

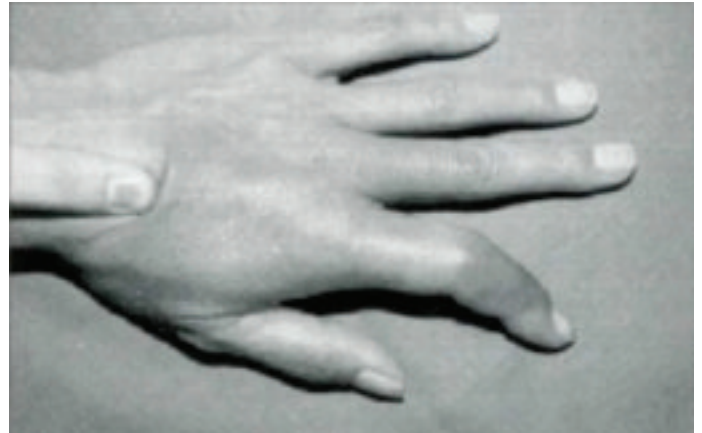

Figure 6 (above). Abnormal rotation of finger is best assessed clinically and will often require an open reduction to remove interposed tissue.

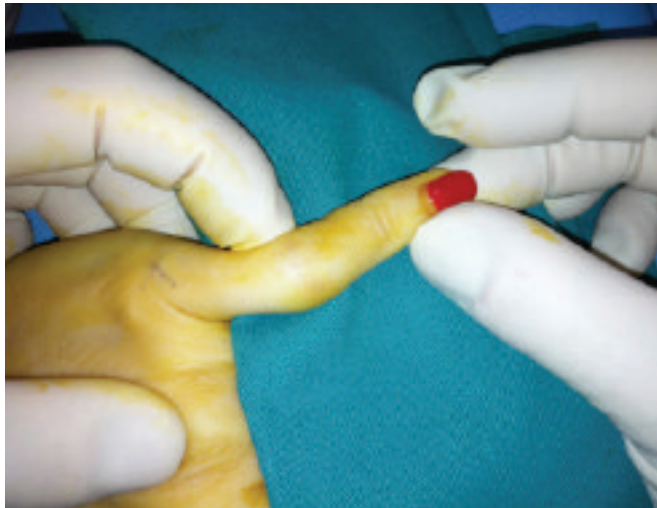

Figure 7 (left). Clinical examination of lateral dislocation

is flexed to maintain the reduction. The stability of the joint should be thoroughly assessed as outlined above. Once the dislocation is reduced, the finger should be managed as a volar plate or lip fractures as outlined above. Recurrent and chronic dislocations usually require open treatment.

The therapists have an important part to play in the care of the patient with a PIP joint injury. They conduct and supervise rehabilitation programmes to increase the range of motion and strength of the hand. They can provide off-the-shelf or custom-made splints for controlled motion or immobilisation of the joint. Oedema

control with coban wrap and gloves are important and aid in maximising mobilisation. Once functional range of motion is obtained, sports specific rehab is critical to getting the athlete back in the game. They also provide valuable advice, encouragement and reassurance to the athlete.

Collateral ligament injuries

Collateral ligament injuries are produced by a lateral force applied to the finger, with the radial collateral ligament injured six times more often than the ulnar (Eaton 1971). Failure of the collateral ligament almost always occurs at its proximal attachment and

is followed by separation from the accessory collateral ligament (Kiefhaber et al 1986). If the lateral force continues, the volar plate will be avulsed from the middle phalanx (Kiefhaber et al 1986). The patient who has had a collateral ligament injury will be tender and swollen over the ligament. The collateral ligaments should be tested in extension and 30° of flexion and compared to adjacent and contralateral fingers (Minamikawa et al 1993). If the extended PIP joint can be deviated more than 20° the collateral ligament can be assumed to be ruptured (Figures 7 & 8) (Kiefhaber et al 1986).

The majority of these injuries can be managed non-operatively; however, interposition of the collateral ligament may necessitate open reduction. When the finger is reduced the ligaments usually return to their anatomical position, therefore late instability is uncommon. Once reduced, the finger can be mobilised with buddy taping for four to six weeks, with the injured ligament abutting the adjacent normal finger. It is not uncommon for the collateral ligament to avulse a small bone

fragment, which does not change the management. Occasionally a large fragment with articular cartilage is avulsed, and requires open reduction to maintain alignment and joint congruity.

Central slip injuries

The central slip of the extensor mechanism is the prime extensor and the most important dorsal stabiliser of the joint. The dorsal capsule provides minimal stability because there is no formal capsular structure dorsal to the collateral ligaments (Eaton 1971). Injury to the central slip occurs following hyperflexion, resisted extension or laceration. The central slip should be tested by asking the patient to extend the PIP joint against resistance while the MCP joint is extended. Treatment consists of maintaining PIP joint extension with a splint, finger cast or a transarticular K-wire for six weeks. Fractures with a large fragment may require open reduction. A Capener dynamic extension splint can be worn for an additional four weeks (Figure 9) (Eaton & Malerich 1980).

Volar dislocations are rare and usually result from a hyperflexion

or rotatory force on the finger. The condyles of the proximal phalanx either rupture the central slip or perforate the extensor mechanism between the central slip and the lateral band (Dray & Eaton 1993; Weiss & Hastings 1993). Closed reduction is often unsuccessful. Following open reduction, the extensor mechanism is repaired and the joint immobilised in full extension for six weeks with a splint or transarticular wire (Dray & Eaton 1993).

Fractures involving the PIP joint

The volar lip fracture is the most common fracture that occurs following injuries to the PIP joint (Jupiter & Belsky 1992). Fortunately, while ubiquitous, they require minimal treatment and maintaining mobility is the priority, particularly in the athlete. Therefore, protective buddy splinting is crucial. Fractures which involve dorsal, volar and lateral lips have been discussed previously (Figure 10).

The unicondylar fracture is common in the athlete and results from a shearing force at the PIP joint. Undisplaced unicondylar fractures

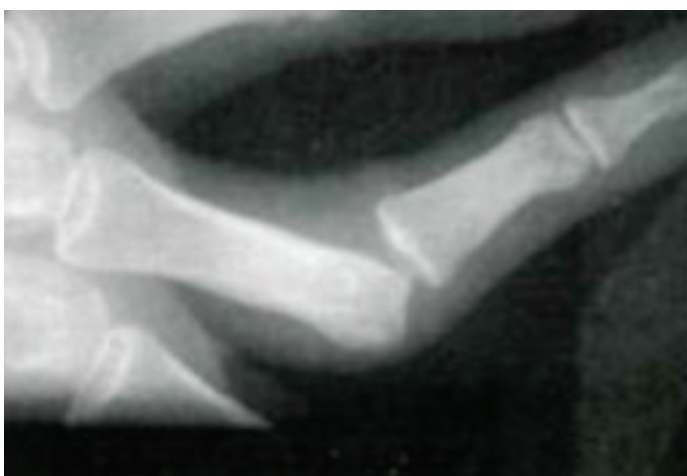


Figure 8. Radiograph of a lateral dislocation.

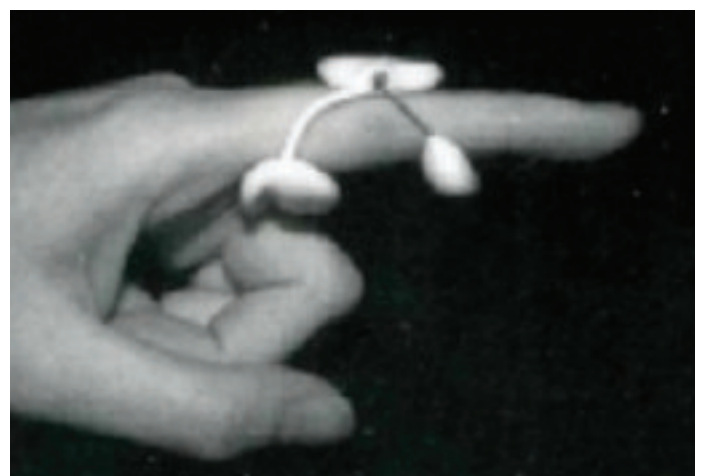

Figure 9. Capener dynamic extension splint.

have a tendency to displace (Weiss & Hastings 1993), so require close, radiological review until fracture union. In the displaced fracture the finger is often deviated, with the collateral ligament acting as a deforming force on the free fragment. An open reduction is often required to obtain an anatomical reduction of these fractures to prevent joint incongruity and deformity of the finger.

Bicondylar fractures result from an axial force applied to the finger. These fractures are often comminuted and difficult to manage. They often require open reduction or dynamic skeletal traction. Fractures of the lateral plateau of the base of the middle phalanx are produced by a lateral compressive force and are similar in mechanism and configuration to the lateral tibial plateau fracture (Hastings & Carroll 1988).

The articular cartilage of the plateau is depressed by the condyle. Oblique radiographs, fluoroscopy or even tomograms may be of value in the assessment of these complex fractures. Open reduction followed by occasional bone grafting may be required if joint congruency is to be achieved (Hastings & Carroll 1988). However the vast majority of articular comminuted fractures require relative anatomic reduction coupled with early motion in order to avoid significant limitations in range of motion compromising athletic function. Therefore, dynamic external fixation is usually the mainstay of treatment.

Distraction is achieved via external fixation and utilises Vidal's principle of ligamentaxis to provide a reduction, and has been reported to provide good results by a number of authors

Figure 10.
*Comminuted
fracture of
the base of
the middle
phalanx.*

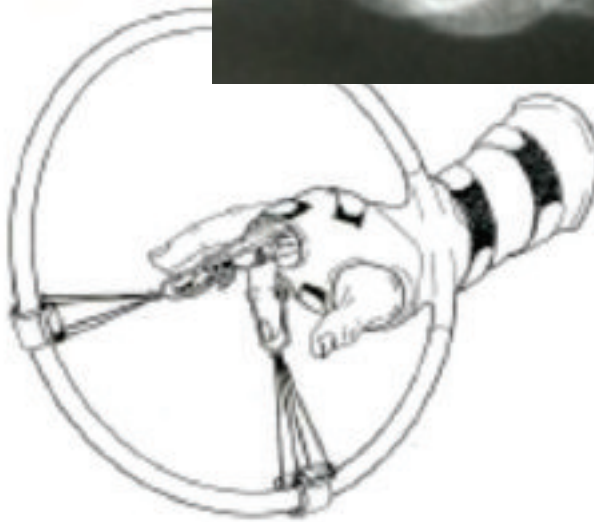
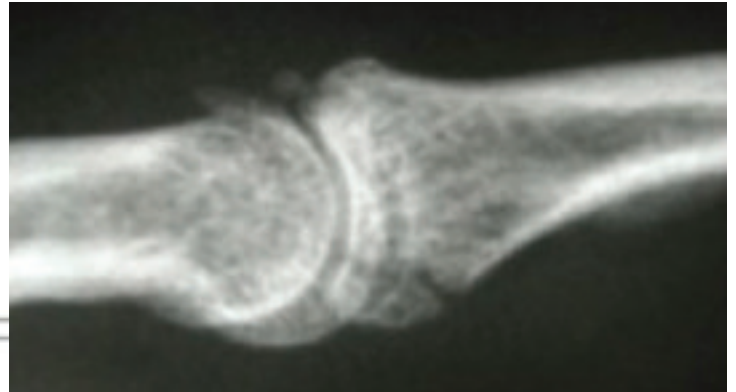

Figure 10. *Arcuate
splint provides
distraction and allows
passive mobilisation.)
Reproduced with
permission from
Schenck, R.R. (1994),
The dynamic traction
method. Hand Clinics
10:187-197.).*

(Schenck 1986; Robertson et al 1946; Stern et al 1991; Gutow & Slade 1997; Morgan et al 1995; Patel & Joshi 1994; Vidal et al 1979; Schenck 1994; Badia 2006). Distraction maintains the length of the capsuloligamentous structures of the joint, which aids in prevention of joint contractures. In addition, distraction unloads the joint to prevent collapse of the fragmented articular surface (Schenck 1994).

Most authors have utilised skeletal traction (Schenck 1986; Morgan et al 1995; Robertson et al 1946) although skin traction has also been proposed (Figure 10) (Hawk 1922). Schenck reported a unidirectional longitudinal skeletal traction attached onto a forearm-based arcuate splint via a rubber band (Schenck 1986; Schenck 1994). Passive mobilisation can be performed by sliding the traction

mechanism around the arcuate splint.

However, these forearm-based 'Banjo-style' splints are difficult to construct and cumbersome for the patient, especially when dressing and sleeping. A number of low profile distraction techniques have recently been published which avoid many of the compliance problems observed with the forearm-based splints (Gutow & Slade 1997; Dennys et al 1992; Allison 1996; Fahmy 1990). Dennys modified Schenck's arcuate splint to produce a lower profile lateral hinge traction splint (Dennys et al 1992).

Gutow and Slade utilised phalangeal K- wires constructed so that rubber bands provided distraction across the joint (Gutow & Slade 1997). The S-quattro method utilises serpentine springs to provide distraction between phalange





Figure 11 Badia's simple dynamic external fixator provides longitudinal distraction via ligamentotaxis achieved using only two simple .045 K-wires, but requiring precise bends in the first, proximal placed pin and allows alteration of this traction via changing the angle of bend.

K-wires (Fahmy 1990), while Allison's technique utilises stainless steel wire attached to ferrules mounted on phalangeal K-wires (Allison 1996). Patel and Joshi reported on the mini phalangeal distractor which utilises the Ilizarov principle of gradual fractional distraction for chronic lesions with soft tissue contractures (Patel & Joshi 1994).

Distraction and stabilisation are provided with bidirectional (Morgan et al 1995) and tridirectional (Robertson et al 1946) traction techniques. They have the advantage of providing longitudinal traction and a vector of traction to maintain reduction (Morgan et al 1995; Robertson et al 1946). However, these devices suffer from the same compliance problems as the arcuate splint described above (Schenck 1986; Schenck 1994).

Agee developed the 'force couple splint', which utilises phalangeal K-wires to provide a volar reduction force on the base of the middle phalanx (Agee 1987). This technique is clever but does not provide traction, and therefore cannot be used for comminuted fractures with loss of the dorsal buttress.

The rhomboid bilateral spring loaded external fixateur developed by Inanami et al provides distraction

and places a volar directed force on the base of the middle phalanx to maintain reduction of the PIPJ (Inanami et al 1993). Transverse K-wires are inserted across the head of the proximal phalanx, base and distal aspects of the middle phalanx and a spring wire rhomboid apparatus is applied to each side of the finger and secured to the K-wires with pulleys (Inanami et al 1993).

Hastings and Carroll reported on a modification of the Kessler lengthening device (Hastings & Carroll 1988; Hastings & Ernst 1993). This is a bilateral fixator that has a pin at the anatomical axis of the proximal phalanx and two pins in the middle phalanx. The proximal component consists of a block with a number of holes to allow dorsal and volar translation to correct the dorsal instability. Distraction is obtained by a threaded pin which connects the proximal and distal components. The joint rotates around the axis pin in the proximal phalanx. Therefore this fixator provides distraction and allows some correction of the instability while

allowing isometric mobilisation.

Badia described a simpler dynamic external fixator that did not rely upon rubber bands to obtain traction since these can break, be lost and lose tension via gradual plastic deformation (Badia 2006). The initial pin, placed through the P1 condylar central axis of rotation, is distally bent in order to engage the 2nd pin, placed in the P2 central axis. The tension of distraction can be modified by the degree of bend placed in the first pins distal engaging construct. Dorsal/volar translation can be achieved via transfixing pins placed perpendicular to the phalangeal axis but being careful to not interfere with the extensor tendon mechanism which would work against the desired principle of early active mobilisation. (Figure 11)

When desiring more controlled, gradual passive mobilisation, with the aid of a worm gear (Compass Proximal Interphalangeal (PIP) Joint Hinge. Smith & Nephew Richards, Memphis, TN, USA) is a radiolucent unilateral hinged external fixateur



Figure 12. Patient controlled passive mobilisation with the compass dynamic PIPJ hinge fixateur. (Reproduced with permission from Bain, G.I., Mehta, f.A., Heptinstall, R.f. and Bria, M. (1998), *Dynamic External Fixation for Injuries of the Proximal Interphalangeal Joint of the Finger*. *J Bone.Joint.Surg (Br)*.80-B:1014-9.).

which allows active and/or passive mobilisation whilst maintaining joint stability (Hotchkiss 1996; Bain et al 1998). A K-wire is advanced across the anatomical axis of the head of the proximal phalanx and becomes the mechanical axis of the compass hinge. Fluoroscopy is used to confirm the position of the wire. Other devices have provided distraction, stabilisation and mobilisation but not in a controlled manner (Hastings & Carroll 1988; Hastings & Ernst 1993; Inanami et al 1993). The worm gear is a unique device that, when engaged, allows the finger to be passively mobilised in a controlled fashion but, which can be disengaged to allow active mobilisation (Figure 12). The worm gear is patient controlled and mobilises the joint with a mechanical advantage similar to that obtained with a turnbuckle as used in the elbow. The angular markings on the hinge allows the patients to monitor their recovery and to set goals with the hand therapist. There is the capability to provide distraction across the joint.

Sequelae of pip joint injuries

The common sequelae of injured PIP joints are not instability or redisplacement but persistent restricted

range of motion and swelling (Eaton 1971). Factors associated with a poor prognosis include fractures which are intra-articular, comminuted or open. Severe soft tissue injury, especially involving skin loss or flexor tendon injury, predisposes to a poor outcome (Strickland et al 1982). Post-traumatic stiffness can be minimised by early joint motion. Rarely should immobilisation be continued for more than three weeks (Bowers 1987). Flexion contractures can be treated initially by dynamic extension splints, resting extension splints and serial casts (Bowers 1987). Resistant cases may require surgical release of the PIP joint.

Post-traumatic swelling is universal following injury to the PIP joint. It is common for this swelling to persist for at least six months. Following a severe injury such as a dislocation, the swelling may be permanent. The use of coban wrap, pressure garments, massage and mobilisation will help to minimise the swelling.

Degenerative arthritis is inevitable if there is joint incongruity or irregularity. Swan-neck deformity (Figure 13) may develop following volar plate injury, and boutonniere deformity following central slip injury. Angular deformities of the finger are usually

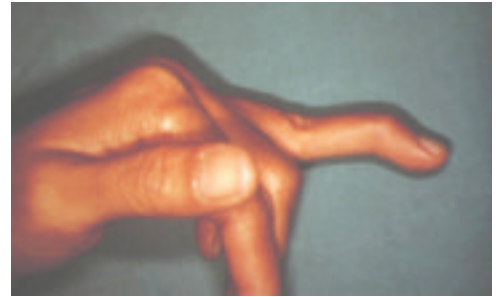

Figure 13. Late swan-neck deformity from untreated PIP joint volar plate injury

due to displaced fractures which have not been anatomically reduced. The majority of complications can be prevented by early diagnosis and appropriate treatment.

Conclusion

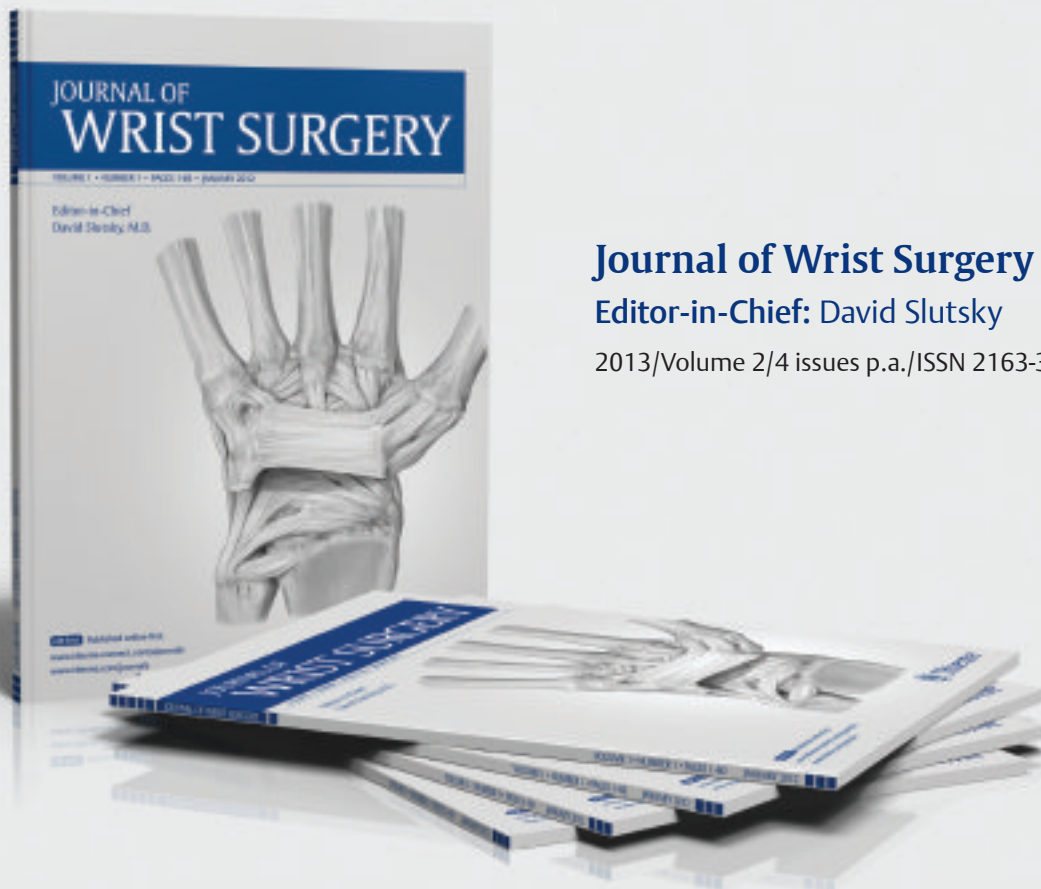
Athletic injuries to the PIP joint are relatively common yet are often undertreated and can have profound impact on sports performance. An early complete assessment of the finger is an important initial step in the management of PIP joint injuries. Radiographs of the finger are critical to assess fractures and subtle instabilities of the joint. Most patients are managed with buddy taping or extension block splinting while instabilities or marked disruption of the bony or soft tissue anatomy may require surgical intervention. Swelling and stiffness are common complications which can be managed with dedicated hand therapy. A sports specific rehabilitation programme will be necessary to allow the athlete to return to premorbid level of play. Therefore, early involvement of the hand specialist is crucial to maximise clinical outcome in managing these daunting injuries in the sportsman.

References:

- Badia A, Riano F, Ravikoff J, Orbay J, Gonzalez E, Khouri R. "Dynamic intra-digital external fixation for proximal interphalangeal joint fracture dislocations". *J Hand Surg Am*, vol. 30A, no.1 pp.154-160, Jan.05.
- Bain GI, Hunt, J and Mehta J A.(1997): Operative fluoroscopy in hand and upper limb surgery: First 100 cases. *JHS(B)* 22B(5):656-658.
- Bain GI, Polites N, Higgs B and Hepinstall R (1999): Functional motion of the joints of the hand. Presented to The American Academy of Orthopaedic Surgeons.
- Bain, G.I., Roth, J.H., Mehta, J.S.:Injuries of the Proximal Interphalangeal Joint. *British Journal of Hand Therapy*. 1999, 3(4): 9-12.
- Bain, G.I., Mehta, J.S.: Proximal Interphalangeal Joint: Surgical and Mobilisation Options. *British Journal of Hand Therapy*. 1999, 3(4): 13-18.
- Bowers WH (1987): Anatomy of the interphalangeal joints.In: The interphalangeal joints, edited by Bowers WH.New York: Churchill Livingstone.
- Bowers WH (1987): Injuries and complications of injuries to the capsular structures of the interphalangeal joints. In: The interphalangeal joints, Vol 3 No 4 edited by Bowers WH. New York: Churchill Livingstone.
- Dray CJ and Eaton RC (1993): Dislocations and ligament injuries in the digits. In: *Operative Hand Surgery*, edited by Green DP. New York: Churchill Livingstone.
- Eaton JW (1971): *Joint injuries of the hand*, Springfield:Charles C Thomas.
- Eaton RC and Malerich MM (1980): Volar plate arthroplasty for the proximal interphalangeal joint ten year review, *Journal of Hand Surgery* 5:260-268.
- Hastings H II and Carroll C (1988): Treatment of closed articular fractures of the metacarpophalangeal and proximal interphalangeal joints.*Hand Clinics* 4(3):503-527.
- Jupiter JB and Belsky MD (1992): Fractures and dislocations of the hand.In: *Skeletal trauma: Fractures, dislocations and ligamentous injuries*, edited by Browner BD, Jupiter JB, Levine AM and Trafton PC Philadelphia: W B Saunders.
- Kiefhaber TR, Stern PJ and Crood ES (1986): Lateral stability of the proximal interphalangeal joint. *Journal of Hand Surgery* 11 A:661-669.
- Leddy JP (1993): Flexor tendon-Acute Injuries. In: *Operative Hand Surgery*, edited by Green DP.New York: Churchill Livingstone.
- Liss FE and Green SM (1992): Capsular injuries of the proximal interphalangeal joint. *Hand Clinics* Nov; 8(4):755-768.
- McCue FC III, Andrews JR and Cieck JH (1974): The coach's finger. *Sports Med* 2:270-276.
- McElfresh EC, Dobyns JH and O'Brien ET (1972): Management of fracture-dislocation of the proximal interphalangeal joint by extension block splinting, *Journal of Bone and Joint Surgery American* 54A:1 705-1 711.
- Minamikawa Y, Horii E, Amadio PC, Cooney WP, Linscheid RL and An KN (1993): Stability and constraint of the proximal interphalangeal joint, *Journal of Hand Surgery* 18A:198-204.
- Strickland JW, Steichen JB and Kleinman WB (1982): Phalangeal fractures, factors influencing digital performance. *Orthop Review* 11:39-50.
- Weiss AC and Hastings C II (1993): Distal unicondylar fractures of the proximal phalanx, *Journal of Hand Surgery* 18A:594-59.
- Schenck 1986
- Robertson et al 1946
- Stern et al 1991
- Gutow & Slade 1997
- Morgan et al 1995
- Patel & Joshi 1994
- Vidal et al 1979
- Schenck 1994
- Badia 2006
- Hawk 1922
- Dennys et al 1992
- Allison 1996
- Fahmy 1990
- Agee 1987
- Inanami et al 1993
- Hastings & Ernst 1993
- Bain et al 1998

NEW SUBSCRIBERS: Take 20% off

A quarterly peer-reviewed periodical covering all aspects of wrist surgery and small bone surgery of the hand



Journal of Wrist Surgery

Editor-in-Chief: David Slutsky

2013/Volume 2/4 issues p.a./ISSN 2163-3916

USA and Canada

Individuals: \$176.00 \$141.00

Institutions: \$462.00

Contact customerservice@thieme.com

For institutional subscriptions, contact esales@thieme.com

Mexico, Central and South America

Individuals: \$192.00 \$154.00

Institutions: \$478.00

Contact customerservice@thieme.com

For institutional subscriptions, contact esales@thieme.com

Africa, Asia, Australia and Europe

Individuals: €136.00 €109.00

(Please add handling charges: €36.00)

Institutions: €348.00

Contact customerservice@thieme.de

For institutional subscriptions, contact eproducts@thieme.de

Bangladesh, Bhutan, India, Nepal, Pakistan and Sri Lanka

Contact customerservice@thieme.in for all subscription rates in INR.

ORDER TODAY



<http://www.thieme.com/jws>

Special introductory rates are only valid for new subscribers and are limited to the first year of subscription. Only qualified professionals and students are eligible for individual subscriptions. Orders from individuals must include the recipient's name and private address, and be paid by private funds.



Become a fan at www.facebook.com/thiemepublishers.



Follow us @ThiemeNY



Thieme

Evelyn Mackin

A Hand Therapy Pioneer

by Patricia Rappaport, MPT, CHT and Judy C. Colditz OT/L, CHT, FAOTA

Evelyn J. Mackin began her work as a physical therapist more than 60 years ago. After putting her career aside to raise her son, she returned to the clinic and focused on treating patients

with hand injuries. Working at the Philadelphia Hand Center with the well-known hand surgeon, James M. Hunter, Evelyn was instrumental in establishing, developing, and promoting hand

therapy as a recognized specialty. Today she is recognized as a world renowned leader and pioneer in the field.

Though a passionate practitioner, she understood the importance of education in this new specialty area and in 1974 was pivotal in launching the well-known Philadelphia Hand Meeting which she chaired for many years. This annual meeting continues to be a prominent symposium among hand surgery and hand therapy professionals with more than 600 therapists in attendance annually.

In 1977, Evelyn joined with other therapists in the United States (Margaret Carter, Bonnie Olivett, Karen Lauckhardt, Mary Kasch, and Judith Bell-Krotoski) to establish the American Society of Hand Therapists (ASHT). In the 36 years since its founding, ASHT has increased its membership to more than 3,000 therapists.

To further disseminate the developing body of knowledge of hand therapy, Evelyn collaborated with James Hunter, Lawrence Schneider and Judith Bell-Krotoski to create and edit the first volume of *Rehabilitation of the Hand*, published in 1978. Now in its 6th edition and expanded to two volumes, this work continues to be a key reference for the treatment of hand and upper extremity injuries.

While serving as President of ASHT



Evelyn with the five recipients of the IFSHT Evelyn Mackin Triennial Award, who were provided sponsorship to attend the IFSHT Congress in New Delhi in March 2013; L to R: Sokny Leang (Cambodia), Sumanta Ray (Bangladesh), Evelyn Mackin, Apsara Ghimire (Nepal), Yuting Zhang (China), Kalyani Hemalatha (Sri-Lanka)



in 1982, Evelyn launched a small paper newsletter called the International Network, to stimulate exchange of information among hand therapists worldwide. As the success of this international platform flourished, Evelyn recognized the need for a professional journal of hand therapy. Through her contacts in the publishing business in Philadelphia, she was instrumental in establishing the Journal of Hand Therapy in 1987. When asked, she will say the founding of the journal is her proudest professional accomplishment. As the first editor, she resolutely pursued acceptance of the journal by Index Medicus, assuring the journal's content be included with other reputable medical publications when searches are done. The journal continues to serve as a forum for research and knowledge about hand therapy and contributions are made by therapists and professionals the world over.

Although working as a clinician, editing a prominent reference book, chairing a popular annual symposium, leading a recently formed professional society, and editing a newly created journal would keep one busy, Evelyn's passion proved relentless. In 1986, she led a group of therapists who met during the joint meeting of the French

Hand Surgery and Hand Therapy Societies in Paris, France to discuss the formation of an international society. One year later, Belgium, France, Great Britain and the United States were the founding member societies of the International Federation of Societies for Hand Therapy (IFSHT) led, not surprisingly, by Evelyn as the founding president. The four original IFSHT member countries have now grown to thirty-three member countries and six corresponding countries.

It has long been Evelyn's vision to "Pass it on." To carry that vision forward and honor Evelyn's many contributions, the Hand Rehabilitation Foundation in Philadelphia has established the Evelyn J. Mackin Hand Therapy Fellowship to promote clinical training in hand management and patient care. Internationally, her vision is recognized through the IFSHT Evelyn Mackin Triennial Award (supported by both IFSHT and IFSSH) which supports therapists from countries where hand therapy is in the early stages of development to attend the IFSHT Triennial Congress.

Those who know her well are aware Evelyn is always quick to credit others, but repeatedly it was she who made certain an idea was carried forward.

When asked how Evelyn was able to engage the many individuals she credits, Judy Colditz, past-president of IFSHT, responded: "You just couldn't say 'no' to Evelyn. She sincerely believed and convinced you that your contribution was needed, important, and appreciated, and that you were destined to be a part of something much bigger."

Evelyn Mackin is now 90 years of age and retired, but remains enthusiastic about promoting and developing the field of hand therapy. Countless therapists, surgeons and patients have, and will, continue to benefit from her dedication to the specialty.

In March of 2013 Evelyn travelled to the 9th Triennial Meeting of IFSHT and the 12th Triennial Meeting of the International Federation of Societies of Hand Surgery in New Delhi, India where she was honored as a legend in the field of hand therapy. True to her form, her comments in the "Reflections of the Legends" video, focused on the recognition of others. We know, however, it was Evelyn's determination that created the many educational and networking opportunities for current and future generations of hand therapists. Hand therapy has become a professional specialty recognized worldwide.

Management of keloids and hypertrophic scars: current and emerging options

Germany

“Keloids, in contrast, may increase in size after ablative lasers without any adjunct therapies”

Dr Gerd Gauglitz from the Department of Dermatology and Allergy, Ludwig-Maximilian University in Germany, recently published a paper on the management of keloids and hypertrophic scars. The paper was in response to a growing aesthetic awareness linked with a rising number of patients feel disappointed with their scars following surgery or trauma.

“More and more patients are seeking help for functional and aesthetic improvement of their scars. Nevertheless, excessive scarring following surgery or trauma remains difficult to improve despite a plethora of advocated treatment strategies as frequently observed in daily clinical routine,” said Dr Gauglitz, adding that the aim of the paper was to give an overview on the currently available and novel options in order to improve scarring and to discuss their efficacy

According to Gauglitz, over the recent years only little progress has been achieved with regards to novel options for the prevention and treatment of excessive scarring. In general, the study data available remains relatively poor with only few therapeutic strategies being supported by well-designed

prospective studies with adequate control groups. “It thus remains critical to prevent scarring by minimising risk factors as much as possible. Physicians need to be aware of basic knowledge of healing mechanisms and skin anatomy, as well as an appreciation of suture material and wound closure techniques to minimise the risk of post-operative scarring,” he said.

Today, most of the propagated therapeutic approaches are usually being utilised for both, hypertrophic scarring and keloids. Nevertheless, clinical differentiation between hypertrophic and keloid scars is central before the initiation of any treatment particularly before starting any surgical or ablative laser related manipulation due to increased recurrence rates with keloids.

“With regards to prevention, a rising body of literature today is supporting the use of silicone based products and onion extract containing scar creams particularly in patients with increased risk to develop excessive scarring. Pressure garments are still frequently used after severe burns but might be associated with impaired compliance in patients suffering from

smaller keloids or hypertrophic scars. For treatment of existing hypertrophic scars and keloids, the use of intra-lesional corticosteroids directly after cryotherapy seems to show most successful results in many cases. In order to reduce the erythema of the scar a pulsed dye laser may be employed later on, as recommended in the current German guidelines for treatment of pathological scars. If these approaches are not successful, based on current study data and personal experience 5-Fluorouracil (5-FU) injected intra-lesionally (in combination with triamcinolon acetonide) may provide convincing results. Non-ablative and ablative fractional laser also seem to provide good results

for the improvement of burn and hypertrophic scars, however, only little data is available for this approach. Keloids, in contrast, may increase in size after ablative lasers without any adjunct therapies," he continued.

By surgical removal of excessive scar tissue a situation corresponding to a fresh wound is achieved, in which renewed excessive scarring can be reduced by adjuvant conservative therapy from the very beginning. However, excision of keloids without any adjuvant therapy (e.g. post-excisional corticosteroid injections, 5-FU, intra-operative cryotherapy, pressure or radiations) should be strictly avoided due to great recurrence rates.

In terms of future research, Gauglitz added that they are currently focusing on three-dimensional devices to objectively measure the decrease of keloid volume upon respective treatments. "We are also employing confocal microscopy and Optical Coherence Tomography techniques in order to determine the mechanism of action of the respective treatment in vivo," he concluded.

JOURNAL REFERENCE

Clinical, Cosmetic and Investigational Dermatology, April 2013, Volume 2013:6, Pages 103 – 114,

The relationship between displacement and clinical outcome after distal radius (Colles') fracture

Norway

Dr Vilhjalmur Finsen from the Department of Orthopaedic Surgery at St Olav's University Hospital in Trondheim, Norway, recently published a paper on the relationship between displacement and clinical outcome after distal radius (Colles') fracture.

"Distal radial fractures are the most common fractures treated by the

health services in northern Europe. They used to be treated almost exclusively conservatively, but during the last couple of decades more and more are being operated on. It is now more usual in Scandinavia to be treated for this fracture by operation than by reduction and PoP. By the way, half of them are so slightly

displaced that they need no other treatment than a plaster splint or cast for 3-4 weeks. There is enormous pressure from the many companies that produce implants to operate - in essence to make nice-looking radiographs. As there is no doubt that many wrists turn out perfectly okay in spite of healing with some

displacement, the purpose of our study was to try and find the limits of radiological displacement that are compatible with a good clinical outcome," Dr Finsen explained.

Finsen and his team reviewed 400 patients clinically and radiologically and found that there was hardly any connection between the radiological and the clinical outcome. "Most of the outcomes were due to other factors. Presumably initial soft-tissue injury is high on this list. Another point is that one year after fracture the clinical results in most patients are so good that it makes it very hard to determine if one treatment is better than another," he added.

For further research, the team has studied the 400 patients for the best way to obtain accurate radiographic measurements of distal radial fractures (1), (by tilting the lateral view 15 degrees) and the value of percutaneous pinning (2) (better x-rays, but same clinical outcome) and what to do if a moderate gap between the scaphoid and lunate is detected in conjunction with an extra-articular Colles' fracture (3) (nothing). "Among other patients we have found poor effect of the Blatt capsulodesis (4), and that it makes no difference to the final displacement if one uses PoP splint or full cast during the first 10 days after fracture reduction (5). We have reported on the results using one of the early implants for Colles' fracture (6) and on a new dynamic external fixator (7). I have been interested in distal radial fractures for a long time and back in the dark ages I did some epidemiological (8,9) and bone density studies (10) on these fractures," he concluded.

"the purpose of our study was to try and find the limits of radiological displacement that are compatible with a good clinical outcome"

References:

- (1) Rajabi B, Rød Ø, Rød K, Alm-Paulsen PS, Russwurm H, Finsen V. Accurate radiographic measurement of the distal radial tilt. *Hand Surg* 2011; 16: 259-62
- (2) Alm-Paulsen PS, Rød Ø, Rød K, Rajabi B, Russwurm H, Finsen V. Percutaneous pinning of fractures of the distal radius. *J Plast Surg Hand Surg* 2012; 46: 195-99.
- (3) Finsen V, Rajabi B, Rød Ø, Rød K, Alm-Paulsen PS, Russwurm H. The clinical outcome after extra-articular Colles' fracture and moderately increased scapholunate gap. (Submitted)
- (4) Finsen V, Borchgrevink G. Poor results of radio-scaphoid capsulodesis for scapholunate dissociation. *Hand Surg* (accepted)
- (5) Strømdal Wik T, Aurstad ÅT, Finsen V. Colles' fracture: dorsal splint or complete cast during the first 10 days? *Injury* 2009; 40: 400-04.
- (6) Finsen V, Aasheim T. Initial experience with the forte plate for dorsally displaced distal radius fractures. *Injury* 2000; 31: 445-48.
- (7) Hove LM, Krukhaug Y, Revheim K, Helland K, Finsen V. Dynamic compared with static external fixation of unstable fractures of the distal part of the radius. A prospective, randomized, multicentre study. *J Bone Joint Surg* 2010; 92-A: 1687-96
- (8) Finsen V, Benum P. Colles' fractures as an indicator of increased risk of hip fracture. *Ann Chir Gynaecol* 1987; 76: 114-18.
- (9) Finsen V, Benum P. The interrelationship of past and present fractures of the forearm and hand. *Acta orthop Scand* 1987; 58: 372-74.
- (10) Finsen V, Benum P. Regional bone mineral density changes after Colles' and forearm fractures. *J Hand Surg* 1986; 11-B: 257-259.

JOURNAL REFERENCE

J Hand Surg Eur Vol February 2013
38: 116-126

Pioneers in Hand Surgery

Raymond M Curtis, M.D.

Dr Curtis was born and raised in the State of Missouri in the United States of America. He started medical school at the University of Missouri and later transferred to New York University where he received his M.D. degree (1939). He completed a residency in general surgery at Union Memorial Hospital in Baltimore, Maryland.

Following his residency, he served as a Major in the United States Army Medical Corps and came under the tutelage of Dr Sterling Bunnell, the Civilian Consultant in hand surgery for the Armed Services, at Letterman Hospital in San Francisco. Upon his discharge from the army in 1947, he returned to Baltimore to the private practice of hand and upper extremity surgery.

During his career he became a renowned teacher and practitioner and was instrumental in developing techniques for the rehabilitation of the stiff hand. He founded the Raymond Curtis Hand Center at Union Memorial Hospital in Baltimore and began the Hand Fellowship program at that institution as Chief of the Division of Hand Surgery. He was Associate Professor of Plastic Surgery and Orthopaedic Surgery at The Johns Hopkins University School of Medicine.

Throughout his career he worked diligently to train U.S. Army hand surgeons for the Department of the Army, working with the Hand Fellowship program at the Walter Reed Army Medical Center, Bethesda, Maryland.

Dr Curtis received a Merit Service Award from the U.S. Army (1947), a Citation for Outstanding Service from the President's Committee on Employment of Physically Handicapped (1955), and an Award of Merit from the Governor's Committee (Maryland) to Promote Employment of the Physically Handicapped (1955).

Dr Curtis served as Secretary-Treasurer (1964 to 1968), Vice President (1968 to 1970) and President of the American Society for Surgery of the Hand (1970 to 1971). He was the Sumner L. Koch Lecturer, Chicago, Illinois, in 1969. He retired from the active practice of hand surgery in 1984 and then resided in Gibson Island, Maryland. In 1992, at the Fifth International IFSSH Congress in Paris, France, he was honoured as a "Pioneer of Hand Surgery".




Adrian E. Flatt, M.A., M.D., M.CHIR., F.R.C.S., F.A.C.S.

Adrian E. Flatt was born and educated in England, obtaining his degrees from Cambridge University. His surgical training was under Sir Reginald Watson Jones in orthopaedics and Professor Pomfret Kilner in plastic surgery. He served the Royal Air Force as a surgeon and was promoted to Squadron Leader (Major) (1949-1950). He was appointed Surgeon-in-Charge to all armed forces in Ceylon at the R.A.F. Services Hospital and was a Visiting Consultant to R.A.F. Stations in Ceylon, Malaya, Indochina and Hong Kong.

Dr Flatt trained in hand surgery under Dr Wm. J. Littler and Dr Daniel Riordan while on a Fulbright Scholarship in the USA. Later he emigrated to the USA, when invited by the University of Iowa where he started a hand surgery fellowship in 1961. During the 22 years he was in Iowa as Professor of Orthopaedics and Professor of Anatomy, he developed a department which contributed many innovative concepts both in clinical and basic biomechanical research. For the latter, he received the Kappa Delta Award from the American Academy of Orthopaedic Surgeons "for outstanding orthopaedic research" in 1972. After leaving Iowa, he spent three years as Clinical Professor of Orthopaedics at Yale University, and from 1982 to 1992 he was Chairman of Orthopaedics at Baylor University Medical Center in Dallas, Texas. Throughout his career he has taught anatomy and trained 50 hand surgeons from fourteen different countries.

He is a founder member of The Second Hand Club, which later evolved in the British Society for Surgery of the Hand. Since 1964 he has been Consultant in Hand Surgery to the Surgeon General, United States Air Force. After serving on many committees of the American Society for Surgery of the Hand, he served as President in 1976. The Journal of Hand Surgery was founded during his presidency and he was its Editor in Chief from 1980 to 1990. He is a Corresponding Editor for the Journal of Hand Surgery (British). He was appointed Hunterian Professor of the Royal College of Surgeons in 1962 and Watson Jones Memorial Lecturer in 1986. He has been the invited lecturer in many Universities and has received many honours including Honorary Memberships in Le Groupe d'Etude de la Main,

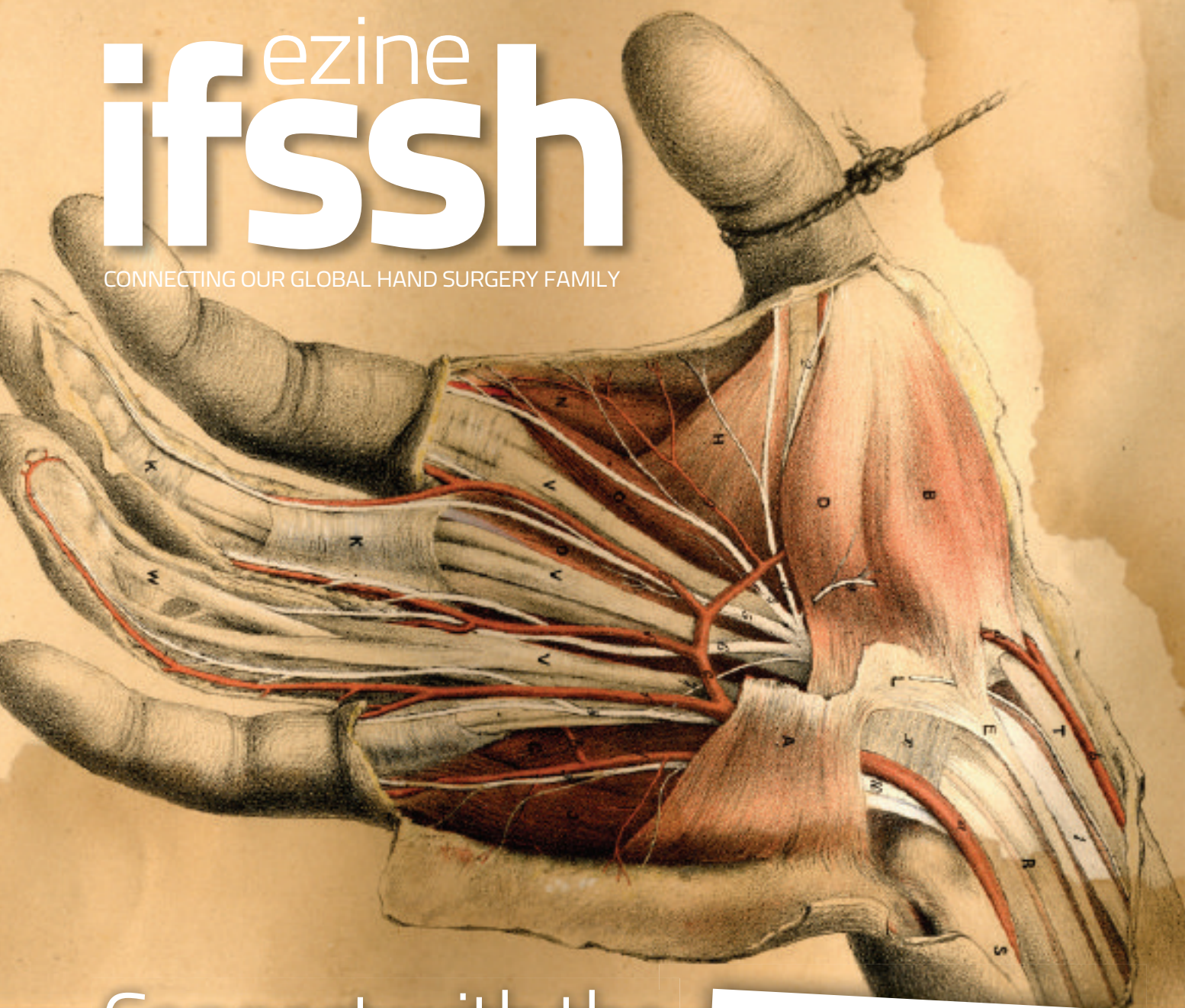

The British Society for Surgery of the Hand, the Venezuelan Hand Society, and the British Association of Plastic Surgeons.

Dr Flatt has written three textbooks, *The Care of Minor Hand Injuries*, *Care of the Arthritic Hand*, and *The Care of Congenital Hand Anomalies*. He was honoured by the IFSSH as "Pioneer of Hand Surgery" at the Fifth International Congress of the IFSSH in Paris, France in 1992.

ezine ifssh

CONNECTING OUR GLOBAL HAND SURGERY FAMILY



Connect with the global profession

The IFSSH ezine is created with the intention of engaging the global hand surgery community and to promote the profession through the sharing of knowledge. In order for the IFSSH ezine to remain relevant and topical, we rely on you, our readers, to:

- Subscribe to receive the ezine
FREE OF CHARGE 4 times per year
- Submit letters to the editor
- Provide us with feedback about the ezine



Journal Highlights

Below is a selection of contents pages from the latest issues of the following leading hand surgery journals. Hover your mouse over each article heading and click to go to the original abstract page of the article.

Journal of Wrist Surgery – Volume 03 • August 2013

- Technique: Osteochondral Grafting of Capitate Chondrosis in PRC
- Arthroscopic Osteochondral Grafting for Radiocarpal Joint Defects
- Thumb Carpometacarpal Arthroplasty with Ligament Reconstruction and Interposition Costochondral Arthroplasty
- Proximal Scaphoid Arthroplasty Using the Medial Femoral Trochlea Flap
- Rib Cartilage Graft for Posttraumatic or Degenerative Arthritis at Wrist Level: 10-Year Results
- Trends in Wrist Arthroscopy
- Volar Plate Fixation of Intra-Articular Distal Radius Fractures: A Retrospective Study
- Ligament Origins Are Preserved in Distal Radial Intraarticular Two-Part Fractures: A Computed Tomography-Based Study
- Trapezial Topography in Thumb Carpometacarpal Arthritis
- Malignant Giant Cell Tumor in the Carpal Tunnel: A Case Report and Review of Literature
- Clinical Evaluation of the Articulinx Intercarpometacarpal Cushion for the First CMC Joint: A Feasibility Study

Hand Clinics Volume 29 • Issue 3 August 2013

- Nerve Physiology: Mechanisms of Injury and Recovery
- How to Measure Outcomes of Peripheral Nerve Surgery
- Timing and Appropriate Use of Electrodiagnostic Studies
- Major Peripheral Nerve Injuries
- Evidence and Techniques in Rehabilitation Following Nerve Injuries
- Tendon Versus Nerve Transfers in Elbow, Wrist, and Hand Reconstruction: A Literature Review
- Management of Chronic Pain Following Nerve Injuries/CRPS Type II
- Management of Neuromas of the Upper Extremity
- Symptoms and Disability After Major Peripheral Nerve Injury
- Recurrent Carpal Tunnel Syndrome
- Ulnar Neuropathy at the Elbow: An Evidence-based Algorithm
- Uncommon Upper Extremity Compression Neuropathies

Hand **Volume 8 – Issue 3, September 2013**

- Examining the efficacy and maintenance of contracture correction after collagenase clostridium histolyticum treatment for Dupuytren's disease
- Replantation and revascularization vs. amputation in injured digits
- Benign upper extremity tumors: factors associated with operative treatment
- Perception of the esthetic and functional outcomes of duplicate thumb reconstruction
- One-stage Integra coverage for fingertip injuries
- Joint space height correlates with arthroscopic grading of wrist arthritis
- Hook of hamate fractures in competitive baseball players
- Improving accuracy and confidence in distal radius volar plate screw placement through supplemental radiography: examining specialty, education, and experience levels
- Biomechanical analysis of knotless flexor tendon repair using large-diameter unidirection barbed suture
- Dorsal radiocarpal dislocation in a patient with Goldenhar syndrome: case report
- Multidigit camptodactyly of the hands and feet
- Chronic thrombosis in the descending genicular artery during harvest of a medial femoral condyle corticocancellous flap: a case report
- Restoration of finger flexion by pronator teres muscle transfer after brachial plexus injury: a case report
- Symptomatic extra-articular scaphoid tuberosity nonunion: surgical excision of the ununited fragment after failed nonoperative management
- Two-stage tendon sheath reconstruction using sublimis tendon and silicone Penrose drain after severe purulent flexor tenosynovitis: a case report
- Hand fat grafting complicated by abscess
- Diagnostic dilemma: acute calcific tendinitis of flexor digitorum profundus
- Open isolated extensor carpi radialis brevis avulsion injury: a case report
- Dynamic neuromusculoskeletal ultrasound documentation of brachial plexus/thoracic outlet compression during elevated arm stress testing

Journal of Hand Surgery (European Volume)

October 2013 | Hand Surg Eur Vol 38, Issue 8

- Outcome measures and their measurement properties for trapeziometacarpal osteoarthritis: a systematic literature review
- Long term outcome of trapeziectomy with ligament reconstruction/tendon interposition versus thumb basal joint prosthesis
- Trapeziometacarpal narrow pseudarthrosis: a new surgical technique to treat thumb carpometacarpal joint arthritis
- A three-dimensional analysis of osteoarthritic changes in the thumb carpometacarpal joint
- Patients with metal-on-metal articulation in trapeziometacarpal total joint arthroplasty may have elevated serum chrome and cobalt
- Clinical and radiological outcomes of the Ivory arthroplasty for trapeziometacarpal joint osteoarthritis with a minimum of 5 years of follow-up: a prospective single-centre cohort study
- Bone mineral density of the trapezium in osteoarthritic trapeziometacarpal joints
- The exploded hand syndrome: a report of five industrial injury cases
- Union rates after proximal scaphoid fractures; meta-analyses and review of available evidence
- Paediatric hand fractures

Journal of Hand Therapy **Volume 26, Issue 4, July - October 2013**

- The use of joint mobilization to improve clinical outcomes in hand therapy: A systematic review of the literature
- Role of the extensor carpi ulnaris in the stabilization of the lunotriquetral joint. An experimental study
- The impact of a hand therapy screening and management clinic for patients referred for surgical opinion in an Australian public hospital
- The effect of finger joint hypomobility on precision grip force
- Clinical commentary in response to "The effect of finger joint mobility on precision grip force"
- Do patient-reported outcome measures capture functioning aspects and environmental factors important to individuals with injuries or disorders of the hand?
- Chronic stroke survivors achieve comparable outcomes following virtual task specific repetitive training guided by a wearable robotic orthosis (UL-EXO7) and actual task specific repetitive training guided by a physical therapist
- Is the UNB test reliable and valid for use with adults with upper limb amputation?
- Dynamic loading posture of the thumb: The Colditz Tear Test
- An innovative orthotic design for midcarpal instability, non-dissociative: Mobility with stability
- Creating a custom fabricated neoprene orthosis for optimal thumb positioning

Journal of Hand Surgery: American volume

Volume 38, Issue 7, Pages A1-A28, 1285-1468 (July 2013)

- Vascularized Graft From the Metatarsal Base for Reconstructing Major Osteochondral Distal Radius Defects
- A Simple Method for Choosing Treatment of Distal Radius Fractures
- Treatment of Avascular Proximal Pole Scaphoid Nonunions With Vascularized Distal Radius Bone Grafting
- Effect of Pisiform Excision or Pisotriquetral Arthrodesis as a Treatment for Pisotriquetral Arthritis: A Biomechanical Study
- Biomechanical Analysis of the Distal Metaphyseal Ulnar Shortening Osteotomy
- Cylindrical Corrective Osteotomy for Madelung Deformity Using a Computer Simulation: Case Report
- Experimental Model of Trigger Finger Through A1 Pulley Constriction in a Human Cadaveric Hand: A Pilot Study
- Fractures of the Lesser Sesamoids: Case Series
- Reconstruction of Chronic Thumb Metacarpophalangeal Joint Radial Collateral Ligament Injuries With a Half-Slip of the Abductor Pollicis Brevis Tendon
- Distraction for Proximal Interphalangeal Joint Contractures: Long-Term Results
- Extensor Tendon Lacerations From Arthroscopic Excision of Dorsal Wrist Ganglion: Case Report
- Treatment of Little Finger Carpometacarpal Posttraumatic Arthritis With a Silicone Implant
- Allograft Reconstruction for Digital Nerve Loss
- Multiple Intraneural Glomus Tumors on a Digital Nerve: Case Report
- Collagenoma in a Child With Tuberous Sclerosis Complex Causing Carpal Tunnel Syndrome and Thumb Overgrowth: Case Report
- Acute Idiopathic Blue Finger: Case Report
- Treatment of Upper Limb Extensor Hypertonia: Case Report
- Patterns of Recontracture After Surgical Correction of Dupuytren Disease
- Guillaume Dupuytren: His Life and Surgical Contributions
- First Hand: Stopping By the Hospital on a Snowy Evening (With Apologies to Robert Frost)
- Nonsurgical Treatment of Elbow Stiffness
- Percutaneous Trigger Finger Release
- Type II and IIIA Thumb Hypoplasia Reconstruction
- Minimally Invasive Endoscopic Decompression for Anterior Interosseous Nerve Syndrome: Technical Notes
- Dosage of Local Anesthesia in Wide Awake Hand Surgery
- Hand and Wrist Injuries in Golf
- MRI of Wrist Ligaments
- The Role of Magnetic Resonance Imaging in Scaphoid Fractures
- Lipofibromatous Hamartoma of the Median Nerve: A Comprehensive Review and Systematic Approach to Evaluation, Diagnosis, and Treatment
- Evidence-Based Reviews for Hand and Upper Extremity Surgery

Upcoming events

Dissection course on upper limb reconstruction

5-7 December 2013

Arezzo, Italy

www.sicm.it/storage-file/Program_Tos_Felici.pdf

The course is aimed at specialists in plastic surgery and orthopedics who wish to improve their technical skills in upper limb flap dissection. Theory will be introduced by experts in the field of reconstructive surgery by means of frontal lessons. Practical sessions will follow: participants will perform cadaver dissections under the supervision of the faculty. Surgical techniques and the clinical indication for using the flaps for covering the upper limb will be discussed in detail. One upper limb for each participant and one foot for each two participants will be available for dissection. All specimens are injected with colored latex.

Endoscopic cubital tunnel minimally invasive hand surgery

13 December 2013

Berlin, Germany

Presented by Drs Reimer Hoffmann and John Lubahn, this one-day workshop held at the Anatomical Institute of the University Charite in Berlin, will teach the techniques of endoscopic nerve surgery of the hand and forearm, especially with the Hoffmann technique to release the ulnar nerve in the cubital tunnel. In addition, you will be shown the complete spectrum of minimally invasive techniques using the illuminated speculum: trigger finger, de Quervain's tendinitis, tendon transfer to reconstruct EPL, tennis elbow and more.

Email info@hpc-oldenburg.de to book your place

Bangladesh Society for Surgery of the Hand (BDSSH) 8th National Conference

27-28 December 2013

Dhaka, Bangladesh

Bangladesh Society for Surgery of the Hand (BDSSH) is going to organize its 8th National Conference at Dhaka on 27-28 December. It will be a two days conference, one day is reserved for CME lectures.

I am inviting you to participate in this conference with your lectures and presentations. For faculty we offer free accommodation, free registration, local transport, two days post conference tour in Sundarban (Mangrove forest/world heritage) is complimentary. For more information contact asmmlam@yahoo.com

Dr ASM Monirul Alam, Honourary Secretary BDSSH

3rd European Symposium on Paediatric Hand Surgery and Rehabilitation

13 - 14 January 2014

London, United Kingdom

<http://www.bsash.ac.uk/education/courses/3rdeuropeansymposiumon>

The British Society for Surgery of the Hand are delighted to host the 3rd European Symposium on Paediatric Hand Surgery and Rehabilitation which will be held at the Institute of Child Health in London on 13th - 14th January 2014.

AAHS 2014 Annual Meeting

January 8-11, 2014

Kauai, Hawaii

<http://meeting.handsurgery.org/>

The AAHS 2014 Annual Meeting is being held at the Grand Hyatt Kauai, January 8-11, 2014, in Kauai.

The Preliminary Program for the Annual Meeting is now online.

Program Highlights include:

- Panel - Things that Therapists Know that Surgeons Need to Know
- Panel - Dupuytren's: What Is New In Needles, Enzymes, Widgets, Fat Grafting and Stretching To Help Simplify Your Practice?
- Panel - Can We Be More Aggressive and Get Better Results with Tendon Injuries?
- Panel - My Best Trick(s) - Simple Solutions That Have Helped Me In Managing Hand Problems
- Hands-On Surgeons & Therapists Development Workshop
- Lunch Symposiums & Hands-On Skills Labs

Invited Speakers:

Invited Guest Lecture: Jin Bo Tang, MD - "How I Do Flexor Tendon Repairs; Details Of Surgery and Early Active Movement Protocol"

Invited Guest Speaker: William P. Magee, Jr. DDS, MD - "The Power of Medicine"

Danyo Lecture: Elisabet Hagert, MD, PhD - "The Sensate Hand in Motion"

Joint Presidential Keynote Lecture: Peter A. Galpin, MD, FACS - "When Hawaii Bites Back"

Register before Friday, November 8, 2013 to receive the Early Bird Registration Rates!

Registration rates will increase after Friday, November 8, 2013.

ASSH 2014 Self-Assessment Examination

Registration deadline 2 April 2014

Exam deadline: 15 June 2014

www.assh.org/Professionals/Education/Pages/SAE.aspx

The American Society for Surgery of the Hand offers this annual exam to hand and upper extremity care professionals as a comprehensive review tool of basic principles and can also be used by practicing clinicians to stay abreast of new developments and concepts within the specialty. The examination covers diagnostic and therapeutic problems, both surgical and non-operative, basic science knowledge, and fundamental principles of hand surgery. The interpretation of the illustrative material (clinical photographs and radiographs) is an integral part of this examination.

In compliance with AMA policy, a minimum passing score of 50% is required for this exam. Only participants who meet the minimum passing score will receive CME credit for taking the examination. General surgeons need to achieve a minimum passing score of 75% to receive credit through ABS. Please check the ABS website for more information on MOC Part 2.

Second International Symposium on Arthrogryposis

17-18 September 2014

St Petersburg, Russia

<http://amc-2014.org/>

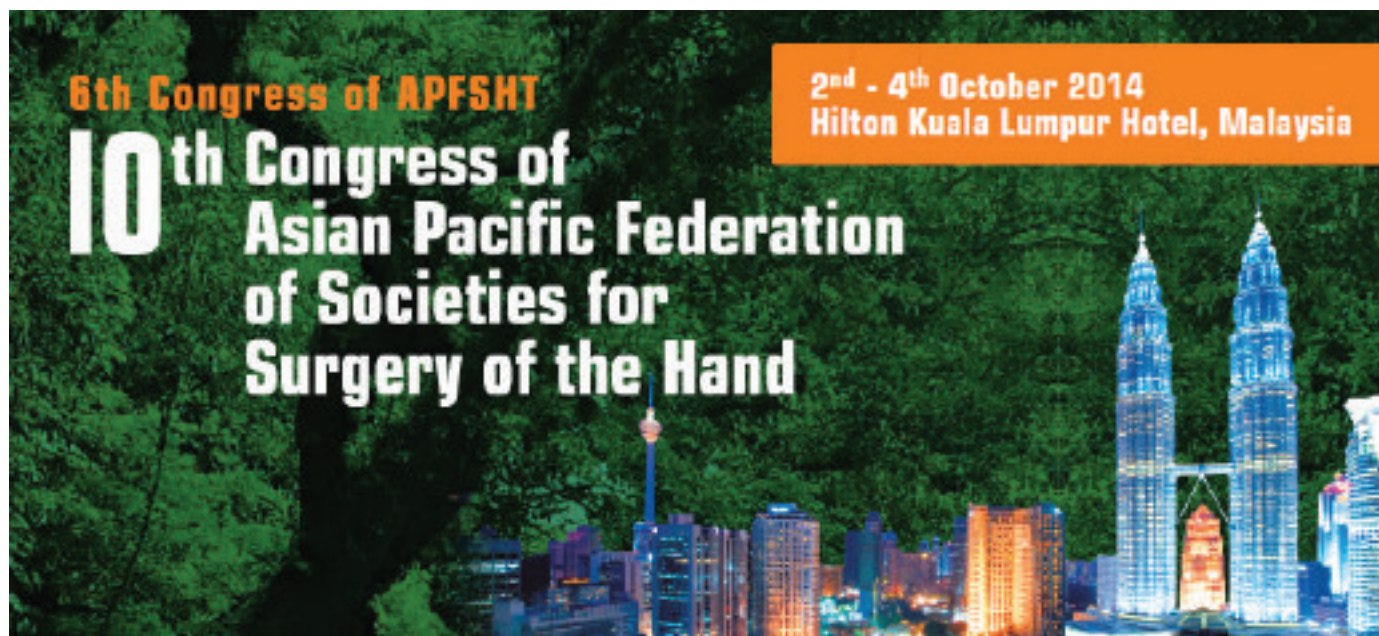We have pleasure in inviting you to join us to the SECOND INTERNATIONAL SYMPOSIUM ON ARTHROGRYPOSIS «UPDATES FROM AROUND THE WORLD» which will be held in Saint-Petersburg, Russia on 17th and 18th September 2014.

The faculty will consist of senior clinicians from all over the world with particular expertise in the management

of all aspects of the care of children and adults with Arthrogryposis including, geneticists, neuromuscular paediatricians, surgeons and rehabilitation experts. This is a unique opportunity to discuss the difficulties of managing this complex condition.

One of the world's most beautiful cities, St Petersburg has all the ingredients for an unforgettable

travel experience. The city offers an extraordinary history and rich cultural traditions, which have inspired and nurtured some of the modern world's greatest literature, music, and visual art. From the mysterious twilight of the White Nights to world-beating opera and ballet productions on magical winter evenings, St Petersburg charms and entices in every season



10th Congress of the Asian Pacific Federation of Societies for Surgery of the Hand

2-4 October 2014

Kuala Lumpur, Malaysia

www.apfssh2014.org

The Malaysian Society for Surgery of the Hand (MSSH) is pleased to invite you to the 10th Congress of the Asia Pacific Federation of Societies for Surgery of the Hand (10th APFSSH) and 6th Congress of the Asia Pacific Federation of Societies for Hand Therapists (APFSHT) which will be held from 2nd - 4th October 2014 at Hilton Kuala Lumpur Hotel, Kuala Lumpur, Malaysia. To make it more exciting and well worth your while, ISSPORTH and IBRA are also joining in the academic activities!

The conference programme includes:

- Cadaveric Pre-Congress Workshops
- 18 Industry Forms
- Five concurrent sessions with 99 symposia and 12 plenaries
- ISSPORTH - International Society for Sport Traumatology of the Hand Meeting
- Exhibition booth showcase
- Digital interface showcase
- International Bone Research Association (IBRA) meeting



NEXT IFSSH & IFSHT

October 09 -13, 2016

Argentina **Buenos Aires**

**Make your plan for attending
to the first Congress in South America!**

**Hilton Buenos Aires
& Convention Center**



Scientific Program: Symposia on the most controversial topics, updates by world renowned experts and best selected free papers.

Special Social Events and Tango Shows.
High quality meat and exquisite Malbec Wines.

High ranked Tourism: Patagonia and it's glaciers, Iguazú Falls, Mendoza's Wine Routes and the incredible views of Purmamarca (Salta and Jujuy).

www.ifssh-ifsht2016.com



