

ezine
ifssh

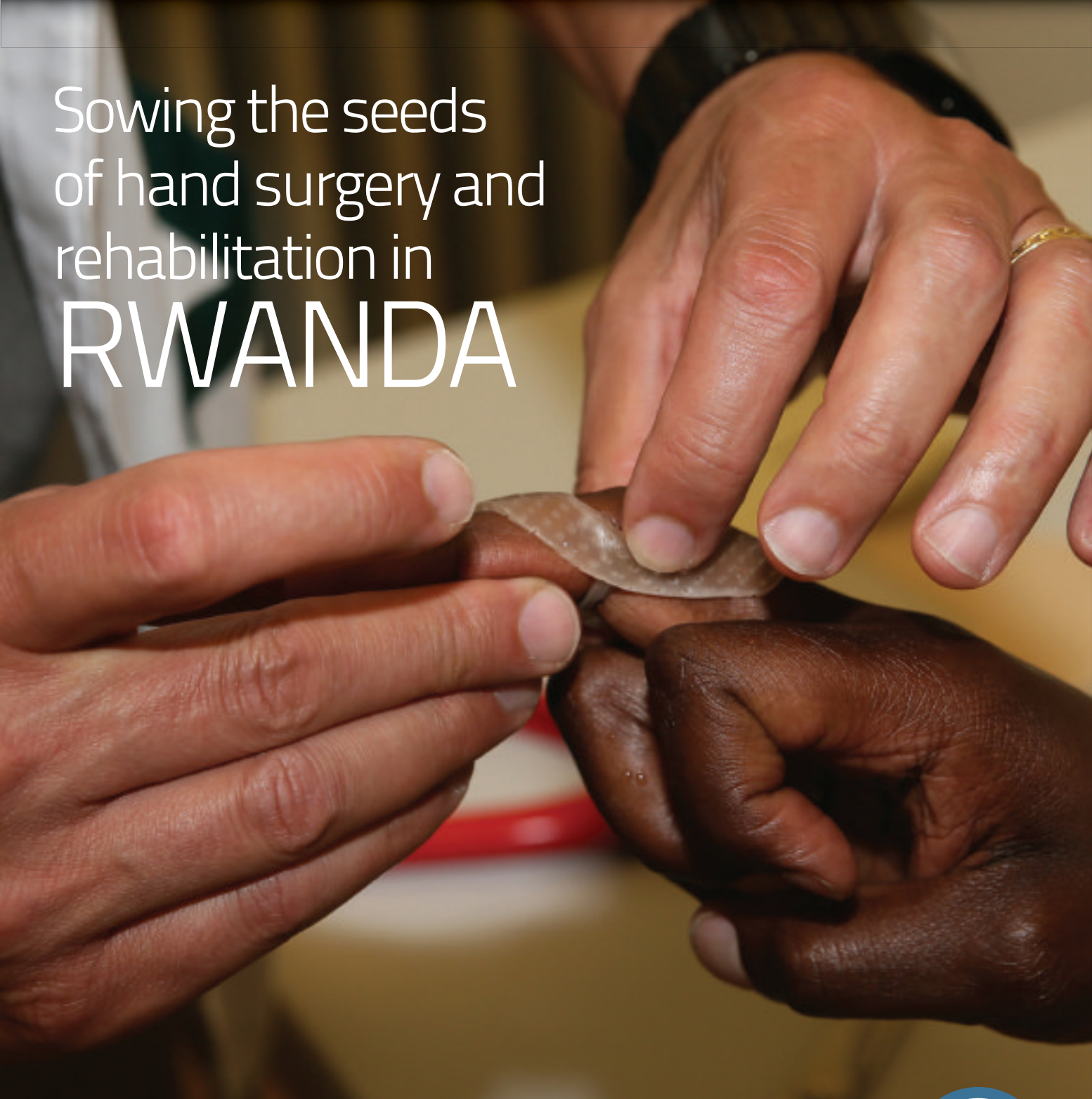CONNECTING OUR GLOBAL HAND SURGERY FAMILY

Journal highlights

Executive news

Member society updates

Sowing the seeds of hand surgery and rehabilitation in **RWANDA**



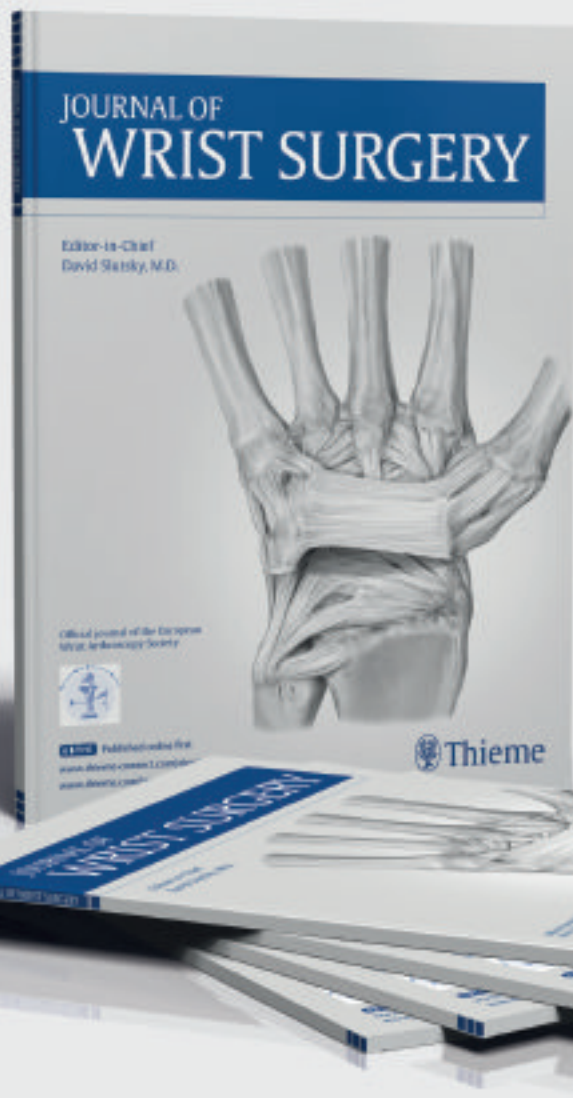SCIENTIFIC COMMITTEE REPORT: NEW
DIRECTIONS IN WRIST ARTHROSCOPY

ACTIVE RE-DIRECTION INSTEAD OF
PASSIVE MOTION FOR JOINT STIFFNESS



NEW SUBSCRIBERS: Take 20% off

A quarterly peer-reviewed periodical covering all aspects of wrist surgery and small bone surgery of the hand



Journal of Wrist Surgery

Editor-in-Chief: D. Slutsky

2014/Volume 3/4 issues p.a./ISSN 2163-3916

USA and Canada

Individuals: \$182 \$146

Institutions: \$492

Please contact customerservice@thieme.com

For institutional licenses, please contact esales@thieme.com

Mexico, Central and South America

Individuals: \$198 \$158

Institutions: \$510

Please contact customerservice@thieme.com

For institutional licenses, please contact esales@thieme.com

Europe, Africa, Asia, Australia, and New Zealand

Individuals: €139 €111

Institutions: €371

(Please add handling charges: €36)

Please contact customerservice@thieme.de

For institutional licenses, please contact eproducts@thieme.de

Bangladesh, Bhutan, India, Nepal, Pakistan, and Sri Lanka

For subscription rates in INR, please contact

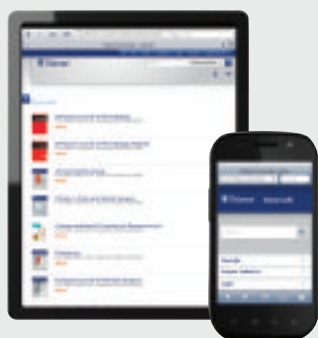customerservice@thieme.in

SUBSCRIBE NOW AND STAY UP-TO-DATE IN 2014

Visit www.thieme.com/jws in order to subscribe or renew your subscription.

Take full advantage of your individual subscription by registering online at <https://www.thieme-connect.de/products>

- Individual subscribers get **free online access to current and back issues** of their journal(s)
- Advanced online access for select journals via the **eFirst service**
- Compatibility with **smartphones and mobile devices**
- Advanced search across our entire library of journals



ORDER TODAY



<http://www.thieme.com>

Special introductory rates are only valid for new subscribers and are limited to the first year of subscription. Only qualified professionals and students are eligible for individual subscriptions. Orders from individuals must include the recipient's name and private address, and be paid by private funds.



Become a fan at www.facebook.com/thiemepublishers.



Follow us @ThiemeNY



Thieme



Contents

4 Editorial

- By Professor Michael Tonkin President, IFSSH
- Letters to the editor
- Living textbook of Hand Surgery:
Beta version now online

8 Executive news

- Newsletter from the Secretary-General:
Marc Garcia-Elias

10 Member society updates

- Hand and Wrist Biomechanics International (HWBI)
- Egyptian Society for Surgery of the Hand and Microsurgery
- Italian Society of Hand Surgery: Study Group for Hand Injuries Prevention
- German Society for Surgery of the Hand

14 Committee reports

- IFSSH Scientific Committee on Degenerative Arthritis - Distal Radioulnar Joint (part 2)
- IFSSH Scientific Committee on Microsurgery: Propeller Perforator Flaps in Forearm and Hand Reconstruction
- IFSSH Scientific Committee on Arthroscopy: New Directions in Wrist Arthroscopy

41 Hand therapy

- Active re-direction instead of passive motion for joint stiffness - Judy C. Colditz

45 Research roundup

- A review on the instability of the distal radioulnar joint - Professor Jesse Jupiter

47 Special feature

- Sowing the seeds of hand surgery and rehabilitation in Rwanda

50 Pioneer profiles

- Kauko A. Solonen, MD
- Paul Woodrow Brown, MD

52 Journal highlights

Tables of Content from leading journals such as The Journal of Wrist Surgery, The American Journal of Hand Surgery, Journal of Hand Surgery Asian Volume, Journal of Hand Surgery European Volume and the Journal of Hand Therapy.

56 Upcoming events

List of global learning events and conferences for hand surgeons and therapists

The IFSSH: A Global Community

The International Federation of Societies for Surgery of the Hand (IFSSH) was formed in 1966 with eight founding societies. Currently there are 55 constituent societies with the most recent member societies being Bangladesh, Bolivia and Russia. Hand surgeons from other countries, such as Pakistan and Myanmar, have expressed interest in joining our community. Conversations are underway with China and it is hoped that this powerhouse of hand surgery will join our Federation. The IFSSH could then consider itself to be truly of a global nature.

It is timely to consider whether our Federation has adapted and is adapting optimally to present circumstances relating to the development, teaching and delivery of hand surgery services throughout the world. Of course, there are a number of realistic challenges which confront any global institution. The first of these is language, as those without English as a first language are disadvantaged. Distance and costs of travel are other challenges which particularly affect those hand surgeons and therapists from financially disadvantaged areas. These problems place a significant responsibility on members of the IFSSH Executive Committee and Delegates' Council. Constantly there is a concern that all are treated fairly and evenly. The allocation of congress venues and hosts and the levelling of annual subscription fees are two pertinent matters. I would like to address the methods that the IFSSH Executive Committee and Delegates' Council have undertaken to minimise perceptions of unfairness.

With current member societies numbering over 50 and the restriction of the IFSSH Congress to once every three years, a period of over 150 years must elapse before all

societies have had an opportunity to host our congress. Clearly it is not possible to satisfy all. There are many opinions regarding the factors which should be taken into account when considering allocation of congress host and venue, including: the realistic ability of a society to conduct an international congress; the contribution of any applicant society to IFSSH activities during the time of membership; the duration of society membership; an even geographic distribution of congress sites with optimal ease of access for as many as possible to attend; a fair distribution amongst peoples of disparate language, economic development and differing cultures; and, finally, an assessment of the quality of the application. More recently the IFSSH has agreed that it would be beneficial for the International Federation of Societies for Hand Therapy (IFSHT) congress to be held in conjunction with our triennial congress. As some surgical societies do not have a counterpart therapy society in their country, and it is inappropriate to exclude such societies from offering an application to act as hosts, we have agreed that combined congresses, although ideal, are not essential.

In 2010, the Delegates' Council approved an Executive Committee recommendation for a geographic rotation system to be implemented in the allocation of congress venues and hosts. The formula which was agreed upon took into account the number of member societies and the number of individual members within each society. These societies were placed in three geographic regions, Europe, the Americas and Asia/Oceania, with some countries such as South Africa being allocated to one of the above regions rather than creating another region. The formula

IFSSH disclaimer: The IFSSH ezine is the official mouthpiece of the International Federation of Societies for Surgery of the Hand. The IFSSH does not endorse the commercial advertising in this publication, nor the content or views of the contributors to the publication. Subscription to the IFSSH ezine is free of charge and the ezine is distributed on a quarterly basis. To subscribe, please **click here**. Should you wish to support this publication through advertising, please **click here**.

IFSSH ezine editorial team:

Editor: Professor Ulrich Mennen (Immediate Past President of the IFSSH)

Deputy Editor: Professor Michael Tonkin
(President of the IFSSH)

Publication coordinator:

Marita Kritzinger (Apex ezines)

Graphic Designer: Andy Garside



which was agreed upon by the Delegates' Council was that over nine successive congresses, four be allocated to Europe, three to Asia/Oceania and two to the Americas, in a manner which distributed the venues and hosts in as fair and as even a manner as possible. It was also agreed that if a society had conducted a congress, then they should not conduct a second congress if an application of acceptable quality was received from a society which had not done so. The intent of this method of allocation was to avoid concentration of multiple congresses in one part of the world, and to provide even opportunities for our disparate member societies to be involved in the conduct of a congress. It was accepted that this intent was ideal, although it is recognised that not all of the factors listed above are provided for within this rotation system. The formula does not preclude two successive congresses in one geographic region, particularly in Europe which is allocated four congresses in the nine congress rotation, but rather should be seen as a transparent method with as fair a distribution as possible. The first three of nine congresses have been allocated to Asia/Oceania (India, 2013), the Americas (Argentina, 2016) and Europe (Germany, 2019). The formula determines that there would be three further European congresses, two Asia/Oceania congresses and one further congress in the Americas over the subsequent six congresses.

It is interesting to review the distribution of congresses since the first meeting in 1980 up to and including 2019 – six have been allocated to Europe, five to Asia/Oceania and three to the Americas, which very closely mirrors the formula which all of us have approved. Conflict and perception of unfairness may still arise but I would request all member societies to give close consideration to the problems associated in satisfying all. The congress rotation guidelines are simply guidelines which the Executive Committee uses to make recommendations to the Delegates' Council. The decision to adopt any recommendation remains with the Delegates' Council.

These principles of fairness also apply to our annual subscription fees. Recently, in 2009, the Executive

“I believe that we can safely claim that our field of hand surgery is nurtured by capable hands and minds.”

Committee suggested that the Delegates' Council consider a two-tier subscription rate, in which those countries that are designated by the World Bank as countries of lower economic development pay a lesser subscription rate. Currently those countries which are financially advantaged pay \$100 per society and \$10 per member of the society per annum. In the second tier, those societies from countries of relative financial disadvantage pay an annual rate of \$50 per society plus \$5 per member of the society. In spite of the best efforts to achieve economic fairness, there may remain perception by some that the amount of payment either by their own society or by other societies is unfair in comparison. This is another difficult area but is a subject that should be discussed openly and transparently. In 2011, it was considered that those societies with a greater number of members may consider that their subscription is disproportionate, both with the amount paid by others and with the measurable benefits obtained from membership. As such, the subscription guidelines have been altered to decrease the per person payment once membership of a single society is above 700.

It is pertinent to consider the use of IFSSH funds. For some time we have slowly accumulated funds. The costs of administration and maintenance of the secretariat are significant. There has been a determination to develop a capital amount upon which interest (profit) obtained from that capital amount was used for administrative costs and distribution to worthy educational projects. The Executive Committee and Delegates' Council now believe that we are in a position to distribute funds in a broader and more generous manner. The Committee for Educational

Sponsorship (CES) was established under the chairmanship of the Secretary General Elect, with two other members – one being the chair of the host society for the upcoming congress and the other being the IFSSH member-at-large. The CES receives applications for educational sponsorship via the Secretary-General and makes recommendations to the Executive Committee. Decisions by the Executive Committee are forwarded to the Delegates' Council members. Sponsorship is available to support the conduct of regional educational courses; applications to receive a Harold Kleinert Visiting Professor; specific applications for educational purposes; and, separately, assistance to attend IFSSH congresses. The last of these is according to

recommendations made by the host organising society. A repayable loan is also available to the triennial congress host to cover set-up costs.

We encourage all to read closely the guidelines for application for sponsorship on the IFSSH website.

The value of the IFSSH and its allied Federations - Federation of European Societies for Surgery of the Hand (FESSH), Asian Pacific Federation of Societies for Surgery of the Hand (APFSSH), Federação Sul Americana de Cirurgia da Mão (FSCM) - and our association with the IFSHT and specific groups such as Hand and Wrist Biomechanics International (HWBI), lies in the ability for us to communicate with each other, meet with each other and

Letters to the editor

Reviewing opportunities: Journal of Hand Surgery (European volume)

The Journal of Hand Surgery (European volume) is seeking new reviewers who can advise our editorial team on submitted articles. Regular reviewers may be asked to evaluate 1 to 3 submissions per month, depending on their area of expertise.

Guidance will be given on the type of reviews required and on the use of our online peer review system.

The editorial team are entirely dependent on the recommendations of reviewers and of editorial board members and, with the number of submissions increasing each year, we are keen to expand our list of reviewers. It is important that reviewers are able to make a commitment to provide reviews of sufficient depth and detail within the required time period (21 days) as this enables us to maintain the quality and reputation of the journal and to process submissions in a rigorous and timely fashion. Reviewers usually complete a three month trial period before becoming regular members of the reviewing team. If you have any questions about the role please send these to editor@journalofhandsurgery.com. Becoming a reviewer for the Journal of Hand Surgery carries the

benefit of providing evidence of Continuing Professional Development for revalidation. The role is also highly advantageous to those wishing to be considered for the editorial board of the journal, and then to progressing from an editorial board member to an editor.

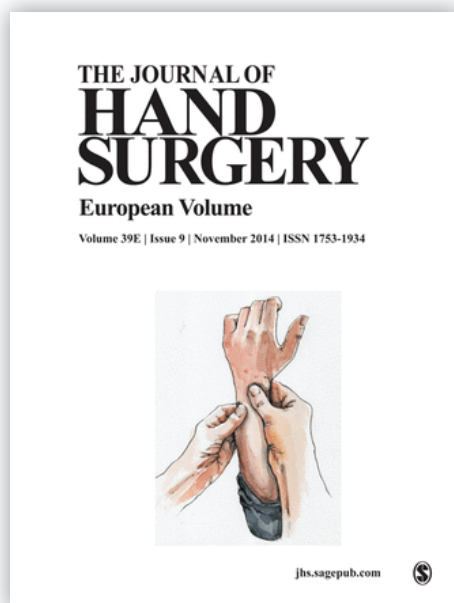If you would like to become a reviewer for the journal, please send a short message setting out your experience and particular areas of expertise to editor@journalofhandsurgery.com

Grey Giddins
Editor-in-Chief

Feedback: VTE after upper limb surgery

Click here to read the original article
In response to IFSSH ezine

volume 4 issue 3
From: Redfern Daniel
Sent: 11 August 2014
Subject: RE: August 2014 Issue -



agree upon optimal methods to develop the field of hand surgery, particularly in areas which are socio-economically disadvantaged. We can also assist in encouraging and supporting those societies amongst us, which, with the advantages of better funding and refined systems, can engage in complex research, the development of sophisticated techniques and equipment, and provision of education for others.

In the last two years, I have had the privilege of attending the IFSSH Congress in India (2013), the American Society annual meeting in San Francisco (2013), the FESSH meeting in Paris (2014) and the APFSSH meeting in Kuala Lumpur (2014). The organisation and academic content

of all have been most impressive, indeed of outstanding quality. We look forward to joining our South American colleagues at the next triennial IFSSH Congress in Buenos Aires in 2016. In the meantime, the IFSSH ezine and our regular newsletters aid in distributing hand surgery information throughout the world.



I believe that we can safely claim that our field of hand surgery is nurtured by capable hands and minds.

Michael Tonkin

President, IFSSH

IFSSH ezine

To Professor Mennen and Mr Warwick,

We have recently completed our second study into the incidence of VTE within 90 days following upper limb surgery. Some of the results were recently presented at BESS. Having reviewed more than three thousand cases, we found the incidence of VTE to approximate that of 'spontaneous' incidence in the general population.

We have one case of a VTE following a carpal tunnel release and one following an shoulder arthroscopy.

We have found similar results in a similar sized cohort following foot and ankle surgery. We proposed that the occurrence seems to be related more to hypercoagulability than immobilisation.

We question the legitimacy and cost effectiveness of current risk assessments and prophylaxis in this entire patient group.

Danny Redfern

Living textbook of Hand Surgery: Beta version now online

Despite delays in software development, the team behind the Living Textbook of Hand surgery is glad to announce the website has now gone live in beta format with its first scientific chapter. The scope of the beta version is to test functionality and stability of the website. From 1 November visitors can view the table of contents, preface and acknowledgements, the list of authors and the Editorial Board. David Warwick and his team have also finished the first scientific subchapter about Dupuytren's disease which can be found in the chapter "Special diseases". They includes several new drawings, photos and videos in the treatment sections.

The Editorial Board and the Editorial Office appreciate any comments and proposals. The next chapters will be available soon after the beta version



has been tested and first updates are finished.

Please feel free to take part in testing the beta version. In some chapters we also need authors who are interested to contribute in their special fields. Do not hesitate to contact us or the responsible member of the Editorial Board.

Visit www.handbookhand.com

Richarda Boettcher

Handchirurgie Weltweit e.V.

richarda.boettcher@hand-ww.de

Message from the Secretary-General: Marc Garcia-Elias

Dear friends,

In the last IFSSH Newsletter we summarised some of the matters discussed at the annual IFSSH Delegates' Council Meeting held on June 19th in Paris, including the recently updated bylaws of our Federation, the activities of the Committee for Educational Sponsorship, and the guidelines for the newly created IFSSH Harold Kleinert Visiting Professorship. However, one newsletter cannot cover all the subjects that were discussed at that meeting. Today I'll share with you some thoughts about another topic that generated discussion in recent Delegates' Council meetings: How to identify candidates to be nominated for the honour of "IFSSH Pioneer of Hand Surgery"?

If you visit the IFSSH website, you will notice that the number of Pioneers honoured during the last two IFSSH congresses almost doubled those of the previous congresses: 15 in Tokyo (1986); 13 in Paris (1992); 17 in Helsinki (1995); 15 in Vancouver (1998); 15 in Istanbul (2001); 7 in Budapest (2004); 13 in Sydney (2007); 28 in Seoul (2010); and 19 in Delhi (2013). Is that an expression of more societies paying attention to this opportunity, or a result of a sub-optimal definition of the criteria to be considered when nominating a Pioneer, making it easier for a hand surgeon to achieve that honour? The first explanation is probably correct, but certainly the criteria in the guidelines for nominating Pioneers needed re-evaluation.

Based on discussions in the Delhi

"If you visit the IFSSH website, you will notice that the number of Pioneers honoured during the last two IFSSH congresses almost doubled those of the previous congresses"

meeting, a revised list of criteria was presented to the Delegates' Council in Paris. These guidelines are on the IFSSH website and will apply for the nomination of Pioneers to be awarded at the 2016 Buenos Aires Congress.

Societies should consider the following criteria when considering potential nominations:

1. Exceptional ability to teach and train hand surgeons at registrar and fellowship level
2. Significant contributions to basic hand surgery research
3. Significant contributions to clinical hand surgery research
4. Publications in peer reviewed journals which substantially add to our understanding of hand surgery
5. Publication of chapters and/or books which made major contributions
6. Involvement in outreach programmes of significant importance
7. Specific international contributions to promote hand surgery, such as involvement in federation activities; and involvement in regional activities
8. Specific contributions to promote hand surgery nationally, such as

society activities

9. Visiting Professorships and invitations to lecture internationally
10. Paper and poster presentations at international meetings
11. Preparation of video programs for teaching purposes
12. Development of equipment and processes for clinical use or academic programmes

This list is not exhaustive, nor must each nominee have excelled in all criteria. However, for the Committee to recommend the award of "Pioneer of Hand Surgery", the nominee must have made outstanding contributions.

Those being nominated as Pioneers must also be over 70 years of age at the time of the next IFSSH congress, or deceased.

Please remember that the guidelines specify that the nomination must come from the society, not from an individual member or a sole executive officer. Each society must take responsibility for considering their society's exceptional contributors and discuss these as a group, before submitting the nominations.

The deadline for submitting nominations for the Buenos Aires congress is April 24th, 2016.

As you will appreciate, the goal of this re-evaluation is to uphold the standard of nomination of Pioneers and ensure that only the most deserving of our colleagues receive their place on the honour list of IFSSH Pioneers of Hand Surgery.

Best regards, Marc Garcia-Elias

Secretary-General, IFSSH.

Email: secretary@ifssh.info

UPPER LIMB IMPAIRMENT CALCULATOR

Upper Limb Impairments Simplified

FIRST NAME John

LAST NAME Citizen

GENDER Male

DATE OF BIRTH J


SIDE L

Thumb

Abnormal Motion


IPJ	Injured	Uninjured	Corrected	MCPJ	Injured	Corrected
Flexion	30° 4%	40° 3%	1%	Flexion	30° 3%	1%
Extension	10° 2%	5° 2%	0%	Extension	10° 1%	1%
Ankylosis				Ankylosis		
Total IPJ	6%	5%	1%	Total MCPJ	4%	

Amputation Impairment F16-4



7%

Sensation Impairment F16-6 T16-6



25%

Other Impairment Mild radial deviation at IP

10%

Hand Impairment Summary

Total Hand Impairment	18%	16%
Convert hand impairment to Upper limb impairment	16%	10%
Add proximal thumb amputation	()	

UPPER LIMB CALCULATOR

18/09/2014

Cancel Add Report

THUMB 2 INJURED Summary

Abnormal Motion

MCPJ Angle 16%

Flexion 30 3%

Extension 10 1%

Ankylosis insert value 4%

Impairment 4%

Back Next

- Easy calculation of upper limb impairments following AMA Guides either 4th or 5th editions
- ROM entered and impairment automatically generated
- All combinations and additions done as data is entered
- Easy correction for uninjured joint ROM below normal
- Comprehensive PDF report generated with uncorrected and corrected values with digit, hand, upper limb and whole person values which may be stored or emailed
- Works on iPad, iPhone and iPod Touch

www.upperlimbcalculator.com



Download on the
App Store



Member society updates

Hand and Wrist Biomechanics International (HWBI)

The Hand and Wrist Biomechanics International (HWBI) is delighted to become an Allied Organisation of the International Federation of Societies for Surgery of the Hand (IFSSH). With this alliance, the HWBI benefits from IFSSH's established excellence as the premier international federation focused on hand surgery and its vast umbrella network of hand surgery societies. In turn, the HWBI contributes its biomechanics specialty knowledge to the IFSSH's pursuit to advance hand surgery and research.

The HWBI has a history of more than 20 years that began in 1992 at the 1st Triennial International Symposium on Hand and Wrist Biomechanics in Brussels, Belgium. Subsequently, the triennial event has taken place in San Francisco (USA), Minneapolis (USA), Izmir (Turkey), Syracuse (USA), Tainan (Taiwan), Cleveland (USA), and Yokohama (Japan). These symposia have provided a valuable forum for global scientific exchange among surgeons, therapists, and researchers who are interested in hand and



wrist biomechanics and its clinical applications.

At the most recent symposium, the 8th Triennial International Hand and Wrist Biomechanics Symposium in 2012 in Yokohama, Japan, the international advisory board decided to form the HWBI to enhance the

development of hand and wrist biomechanics through collaborative efforts across multiple disciplines and countries. At that time, the HWBI Board of Directors was established; its members include Kai-Nan An, PhD, Moroe Beppu, MD, Marc Garcia-Elias, MD, Zong-Ming Li, PhD, David L. Nelson, MD, Frederic Schuind, MD, PhD, William H. Seitz Jr., MD, Fong-Chin Su, PhD, and Frederick W. Werner, MME. Collectively, the HWBI strives for excellence in specialty research and clinical translation for the hand and wrist.



Following our tradition of international symposia, the planning of the next HWBI Symposium is currently underway. It is scheduled to take place in Milan, Italy during June 15-17, 2015. This time, the symposium will be held in conjunction with the XXth Congress of Federation of European Societies for Surgery of the Hand (FESSH). We cordially invite everyone who is interested in hand and wrist biomechanics to join our symposium. By bringing together hand and wrist researchers and clinicians, we hope to integrally advance hand science and to collectively address challenging clinical problems of the hand. Please visit our website (www.hwbi.org) for more information about the HWBI and our upcoming symposium.

HWBI Board of Directors

Kai-Nan An, PhD, Mayo Clinic, USA
 Moroe Beppu, MD, St. Marianna University, JAPAN
 Marc Garcia-Elias, MD, Insitut Kaplan, SPAIN
 Zong-Ming Li, PhD, Cleveland Clinic, USA (Chair)
 David L. Nelson, MD, San Francisco Bay Area Hand Club, USA
 Frederic Schuind, MD, PhD, Universite Libre de Bruxelles, BELGIUM
 William H. Seitz, Jr. MD, Cleveland Clinic, USA
 Fong-Chin Su, PhD, National Cheng Kung University, TAIWAN
 Frederick W. Werner, MME, SUNY Upstate Medical University, USA



Faculty and attendees at the Hurghada international hand surgery conference

Egyptian Society for Surgery of the Hand and Microsurgery

The Egyptian Society for Surgery of the Hand and Microsurgery has had a busy year. The year started with the 4th annual international hand surgery congress jointly sponsored by the Orthopaedic Department of Sohag University, which was held in Hurghada, a resort on the Red Sea, on November 20-22, 2013.

On January 23rd, 2014, a clinical meeting was held at El Helmia Military Hospital in conjunction with the Orthopaedic and Plastic Surgery Departments of the Armed Forces. The third annual Brachial Plexus and Microsurgery workshop was held in collaboration with Assuit University on March 18-19, 2014 in Assuit in Upper Egypt. The 6th annual international Hand Surgery conference was held in Hurghada, by the Red Sea. The meeting was very successful and was



The faculty of the combined meeting of ESSHM and the Armed Forces' Orthopaedic and Plastic Surgery units.

attended by many international guest faculty members.

The annual instructional course was held in Alexandria, the charming city by the Mediterranean Sea, on October 24-26, 2014. The programme committee, under the leadership of the ESSHM president, Professor Essam El Karef, has put a very stimulating interactive programme and the theme of the conference was "Wrist Surgery".

The 7th annual International Hand Surgery Conference will be held in Cairo in April 2015. We would like to invite all the colleagues, members of IFSSH to honour us with their presence at that meeting. For information please contact Professor Abdel Hakim Massoud at mass321@hotmail.com.

Respectfully submitted by

Nash Naam, MD, FACS

Representative to IFSSH

dnaam@handdocs.com

Italian Society of Hand Surgery: Study Group for Hand Injuries Prevention

A Study Group for Hand Injuries Prevention was formed by the Italian Society of Hand Surgery (SICM), to look not only at the traditional artisanal and industrial injuries, but also at the accidents in daily life activities. This latter group has been highlighted recently by the World Health Organisation (WHO).

Two million patients were diagnosed with an upper extremity injury between 01 January 2012 and 31 December 2012 in the Italian Health Authority database. According

to this authority's methodology, this represents an estimated total of 197,000 upper extremity injuries presenting to an emergency department in Italy during this time period. The majority were finger injuries (38.4%), followed by shoulder (16.8%), lower arm (between the elbow and the wrist) (15.3%), wrist (15.2%), elbow (10.5%), and upper arm (between the shoulder and the elbow) injuries (3.7%). The majority of upper extremity injuries occurred at home (45.4%), while 16.2% were work related. Other common sites included schools (6.6%), other public property (4.1%), and street (2.5%). However, 25.1% of locations were not recorded. Most injuries occurred between the ages of 9–14 years and 65–87 (recorded data by ISS - Superior Institute of Health - Italy).

While international legislation has paid close attention in recent years to the prevention of artisanal and industrial accidents, a significant portion (both in terms of quantity and severity) of injuries to both adults and children occur in protected environments – houses, schools, sports and recreational activities.

A voluntary National Prevention Campaign for Hand Injuries in Children programme is being undertaken in Italy. The campaign utilises behavioural guidelines and awareness of risk factors for children, drawn from the clinical and territorial professional experiences of the hand surgeons of the Study Group. These are portrayed in a more engaging and attractive model of communication to families and the children themselves, by means of

comics and simple languages. The campaign has a dedicated website - www.manisicure.eu – which contains general information on hand injuries and specific guidelines. In collaboration with the Health and Instructional Italian Ministers, a booklet summarising the prevention guidelines for children has been distributed to those working and playing with children (teachers, caregivers and educators) and families. Comic books and drawings were a result of collaborations with some of the children from the primary schools. The format has been shared by Hand Trauma Committee of Federation European Societies of Surgery of the Hand (FESSH) and by a WHO newsletter (53 countries) for use in prevention campaigns all over the world.

Dott.ssa Anna De Leo, Dott. Andrea Leti Acciaro, Prof Giorgio Pajardi SICM

German Society for Surgery of the Hand

The German Society for Surgery of the Hand (DGH) has a board consisting of four members forming the closer board and an additional 25 associated officers. This includes the delegates for the various German societies involved in hand surgery and hand therapy as well as the delegates for the FESSH and IFSSH. The complete group meets twice a year to discuss, plan and delegate the activities and the projects for the year. The focus for the year 2013 was to further intensify the relationship to the German Society of Surgery, the German

Society for Plastic and Reconstructive Surgery, the German Society for Traumatology and the German Society for Orthopaedic Surgery. As a first result the DGH organised specific hand sessions at the annual meetings of these societies this year and the close and friendly relationship to these societies was further deepened.

During the two day workshop and board meeting this February the council group decided to focus this year on the development of a network of German hand trauma centres including the implementation of a hand trauma register to collect general data on hand trauma. During a first meeting in July (picture 1) thoughts on possible items collected in a register as well as specific criteria for a network and its internet



ABOVE: Founding members of the German Hand Trauma Network committee

LEFT: The congress president Nicola Borisch and the president of the DGH Jörg van Schoonhoven invite you to participate at the 55th annual meeting of the DGH



presentation were shared. The group will meet a second time this year to further develop these ideas.

One major project for the upcoming years is the organisation of the IFSSH congress 2019 in Berlin. Members for the organising committee have been identified and the almost 800 members of the German Society for Surgery of the Hand are excited and looking forward to welcome the world of hand surgery in 2019.

The next major event in Germany will be 55th annual meeting of the DGH from October 9th to 11th combined with the annual meeting of the German Association for Hand

Therapy in Baden Baden. Our host will be Dr. Nicola Borisch (picture 2) and the focus of the meeting will be the rheumatoid hand and arthroscopy in hand surgery with guest lectures from all around the world. As the location of Baden Baden is close to France and Switzerland we especially invite all our friends from the neighbour countries to share this event with us.

IFSSH Scientific Committee on Degenerative Arthritis – Distal Radioulnar Joint

Chair: Luis R. Scheker (USA)

Committee: Chris Milner (United Kingdom), Ilse Degreef (Belgium), Gregory I. Bain (Australia), Eduardo R. Zancolli III (Argentina), Richard A. Berger (USA)

Report submitted April 2014

The previous issue of the IFSSH ezine published part 1 of this report. [Click here](#) to read it.

Part 2 - Management of Distal Radioulnar Joint Degeneration

Non-Operative Management

Non-surgical management of distal radioulnar joint (DRUJ) osteoarthritis (OA) includes supportive general measures including analgesia and steroid or hyaluronan (HA) injections into the joint itself. As the pattern of wear across the joint surface may be restricted to certain zones of pronosupination, dynamic splintage can be used to restrict motion away from these areas in favour of healthy cartilage contact.

The Evolution of Surgery at the DRUJ

Many procedures have been described for the management of DRUJ dysfunction, reflecting the varying spectrum of pathology that is encountered. Until recently, the DRUJ was a poorly understood joint and hence problems associated with it were addressed with little grounding in the necessary basic biomechanical

principles. This has led to sub-optimal outcomes from diverse attempts at surgical improvement through a wealth of different operations that typically indicate the lack of any single successful intervention.

The earliest reference to distal ulnar resection was by Bernard and Huette from the illustrated manual of operative surgery and surgical anatomy⁴⁷. This was first published in French in the year 1851 and was translated to German in 1855 and English in 1857. Another reference to this procedure was made in a book written by Malgaigne in 1855⁴⁸. He suggested resection of the ulnar head when it was dislocated and protruding through skin. Further reference to distal ulnar resection was made by George in his book on his observations of the American civil war in the year 1876. Moore in 1880 and Tillmans in 1891 made further reference to distal ulnar resection

but mostly in the acute situation. Von Lesser reported a subperiosteal resection of the ulnar head to improve the range of pronosupination in a patient with post traumatic OA as a result of a malunited distal radius fracture in 1886. Lauenstein (1887), van Lennep (1897), Angus (1908), Darrach (1912), Douglas (1914), and Bazy and Galtier (1935) also described excision of the ulnar head for a similar indication⁴⁹. Smith- Petersen et al (1943) described excision of the ulnar head in patients with rheumatoid arthritis. Darrach's name became the preferred eponym for excision of the ulnar head following reports by Hucherson in 1941 and Dingman in 1952⁵⁰. Destot in 1908 observed that the absence of a portion of the ulnar diaphysis with an ankylosed DRUJ provided improved pronosupination. He did not propose intentional pseudoarthrosis though. This was later proposed by several authors including

Baldwin, Colalian and Wheeler.

Baldwin in 1921 reported restoration of pronosupination after excision of a segment of ulnar diaphysis in a patient with a malunited distal radius fracture.

In most of these cases the DRUJ had undergone ankylosis and was not intentionally arthrodesed. The earliest report of surgical arthrodesis of the DRUJ was by Berry from New Zealand in 1931. He performed this procedure in a 20 year old patient who had a nonunion of the ulnar styloid process with chronic instability. He felt that the surgery was a good option for malunited distal radius fractures as compared to distal ulnar excision. He also advocated this procedure in Madelung's deformity. Arthur Steindler in his text book "The traumatic deformities and disabilities of the upper extremity", mentions two cases of DRUJ arthrodesis with ulnar diaphysis excision. He wrongly attributed this to Lauenstein when in fact he had proposed only a distal resection of the ulna. In the USA the fusion of the DRUJ with a small segment of the metaphysis of the ulna, was for a long time, known as the Lowenstein procedure until Taleisnik indicated that this was the work of Sauvé and Kapandji who published the description in 1936^{51,52}. Outside of the USA, the eponym became popular after reports by Vergoz and Baciú. Because of forearm instability that results after the above mentioned procedures, Bowers in 1985 proposed the hemi-resection with pronator quadratus interposition and Watson in 1986 described the matched resection of the ulnar head^{53,54}. As these two operations proved to be

as unsatisfactory as straightforward ablation, in 1998 Wolfe et al described the wide excision of the distal ulna to solve the problems of pain due to radioulnar impingement with similarly dismal results⁵⁵. Although widely accepted, these ablative procedures at the distal end of the ulna do not restore the normal biomechanics of the forearm and bring with them known adverse consequences as described by Bell et al. known as the ulnar impingement syndrome²⁸.

Current Surgical Management of DRUJ Pathology and Salvage Techniques

DRUJ pathology and its treatment options can be truly challenging⁵⁶. A well-balanced DRUJ that retains the mobility needed for daily function necessitates a stable, congruent joint with healthy articular cartilage that is free from degenerative change.

Maintaining the health of the DRUJ can be considered under the following categories, and should always be approached with the overall intention of establishing joint integrity and the preservation of the health of the articular cartilage wherever possible.

- 1: Restoration of DRUJ ligamentous support and joint stabilisation.
- 2: Acute fracture management with restoration of DRUJ congruence and simultaneous assessment and correction of DRUJ ligament injury.
- 3: Secondary correction of DRUJ incongruence following fracture malunion.
- 4: Alignment of radioulnar length to decompress positive ulnar variance or improve joint congruity.
- 5: Treatment of established

degenerative joint disease with joint arthroplasty techniques

- 6: Secondary reconstruction / salvage following previous ulnar head ablative procedures and in cases of bone loss necessitated through resection for other disease such as neoplasia.

Surgical planning to address DRUJ pathology requires the consideration of a number of factors as there is frequently an inter-dependence between several of the categories listed above. Perhaps the most important aspect lies in the timing of DRUJ treatment, where a domino effect of joint deterioration occurs, passing through biomechanical disruption, cartilage damage, established joint degeneration, clinical pain and loss of function. Successful restoration of lost DRUJ stability, for example, will only be fruitful if performed before instability-induced arthrosis has set in. After this window of opportunity has lapsed, stabilisation may still be required, but in addition to a joint resurfacing procedure. How fast this progressive deterioration takes place may vary from one situation to another but must always be considered at the outset during decision making for DRUJ reconstruction.

Surgical Approaches

Surgical approaches can be divided into open versus arthroscopic techniques. Minimally invasive techniques have the advantage of both detailed visualisation of joint anatomy and faster recovery from minimised scarring and associated joint stiffness. Wrist arthroscopy has become a widely accepted technique

for the evaluation and treatment of injuries of the TFCC ^{57,58}. Wrist and DRUJ arthroscopy both help in the evaluation and diagnosis of TFCC lesions, wrist instability and arthritic joint surfaces. Arthroscopic treatment options include synovectomy and TFCC repair/resection ^{57,59}. However, any cartilage ablative procedure has no place in reconstructive DRUJ surgery and should not be considered. This includes the arthroscopic 'wafer' removal of the distal pole of the ulna for ulnocarpal abutment correction.

DRUJ Stabilisation

DRUJ instability following acute, isolated dorsal or volar dislocation is typically reduced to congruency in neutral forearm position and if this is possible, six weeks of immobilisation in a neutral long arm cast is usually satisfactory. If closed reduction is not possible, open reduction should be attempted to remove any interposition. Chronic instability without associated forearm fracture malunion can be treated by soft tissue reconstruction. However, before such surgery is contemplated, the DRUJ must be congruent, with stable radiocarpal and ulnocarpal ligaments and the integrity of these structures must be assessed individually. If satisfactory radiocarpal or ulnocarpal stability is absent, attempts should be made to stabilise those structures before attention is paid to the DRUJ, and if the DRUJ is not itself congruent, soft tissue reconstruction procedures are destined to fail. Soft tissue stabilising procedures aim to restore DRUJ stability, and may or may not be associated with reconstruction of the TFCC itself.

"Until recently, the DRUJ was a poorly understood joint and hence problems associated with it were addressed with little grounding in the necessary basic biomechanical principles."

Well known procedures include the anatomical palmaris tendon DRUJ stabilisation techniques developed by Scheker in 1994 and the subsequent palmaris graft approaches of Adams in 2002 or the brachioradialis transfer developed by Gupta ⁶⁰⁻⁶⁴. Pure dorsal radioulnar ligament defects can be addressed by the Herbert plasty, where the extensor retinaculum is used for reconstruction ⁶⁵. More recently, arthroscopic techniques for TFCC reconstruction with tendon grafting to stabilise the DRUJ are gaining popularity ^{57,59}.

Acute Fracture Management

Acute fractures of the distal radius and ulna require optimal reduction and restoration of DRUJ congruence and stability, paying close attention to fractures involving the volar, ulnar region of the sigmoid notch in an attempt to limit direct chondral injury within the DRUJ. Surgically treated distal radial fractures require assessment of DRUJ stability following bone fixation

and soft tissue repair of the TFCC as indicated. Likewise, remote fractures that impact upon the DRUJ such as the Galeazzi fracture dislocation similarly require assessment of DRUJ stability and repair as necessary.

Congruence Surgery and Correction of Malunion

In situations where the radial articular surface is abnormally flat, DRUJ congruency and therefore stability can be improved by an osteotomy of the sigmoid notch ^{66,67}. This technique is reserved for specific cases in which an abnormally flat sigmoid notch or post traumatic joint deformity can be improved by addressing volar or dorsal rim insufficiency of the otherwise intact DRUJ. Similarly, early signs of degenerative arthritis at the DRUJ can sometimes be successfully treated by minor re-alignment of the chondral contact surfaces within the DRUJ through ulnar shortening osteotomy ⁶⁸. Malunion of the distal radius that produces an incongruent DRUJ should likewise be addressed through corrective opening or closing wedge osteotomy techniques.

Adjustment of Ulnar Variance

Ulnar shortening plays an important role in the restoration and maintenance of DRUJ health. Isolated positive ulnar variance is associated with primary DRUJ OA and also underlies the ulnocarpal abutment syndrome ⁶⁹. As the joint itself is involved in many of the wide range of available shortening techniques for positive variance, careful consideration needs to be given towards technique selection in order to

avoid inadvertent DRUJ damage. The ulna should be shortened at either of two different levels, via a shortening osteotomy either within the DRUJ or at the ulnar diaphysis. Ulnar shortening within the DRUJ has the potential to damage the joint surfaces and therefore may not be feasible in severe ulna plus pathology^{70,71}. In these cases, a diaphyseal shortening osteotomy may be preferred. This osteotomy should be done as distal as possible to minimise risks of nonunion, which is a well-known complication of ulnar shortening osteotomy. Diaphyseal ulnar shortening can also be used to tension the TFCC in cases of mild instability and also realign the ulnar head and sigmoid notch in early post-traumatic OA. Schecker reported the results of using ulnar shortening to treat early DRUJ OA and achieved 57% excellent or good results^{68,72}. The osteotomy itself can be performed in a transverse, diagonal or step-cut manner; the latter two techniques increasing the bony contact surface area with the aim of optimising union but which are more challenging to perform. Intra-articular ulnar shortening has the advantage of both faster consolidation due to the high cancellous bone content and the avoidance of plate fixation. Many variations of intra-articular ulnar shortening have been suggested. The Sennwald osteotomy with a sliding shortening osteotomy of the ulnar head has proved to be very efficient in selected cases with a stable DRUJ requiring a maximal 4 to 5 mm shortening⁷³. If cartilage on the distal ulna is intact, a subchondral cartilage-retaining wafer osteotomy of the distal ulna is an option⁷⁴.

"A well-balanced DRUJ that retains the mobility needed for daily function necessitates a stable, congruent joint with healthy articular cartilage that is free from degenerative change."

Resection Arthroplasty

The destruction of the DRUJ through total or partial ablation of the head of the ulna began in the 1850s and in many hand surgery facilities, persists to this day⁴⁷. With the clear demonstration of the load bearing function of the DRUJ, it must be appreciated that the removal of the ulnar head destroys its load-bearing function, and whether this translates into clinically significant radioulnar impingement or not, it is to be expected and evaluated for if we are to avoid doing the patient so-treated a great disservice. So called low-demand patients traditionally fit into the bracket of being a good surgical candidate for resection arthroplasty, as it is assumed that their frailty will mitigate against the possibility of painful impingement. This is a dangerous assumption to make and in fact these patients are the very individuals at greatest risk of serious loss of function and independence after ulnar head

ablation. Impingement following resection arthroplasty can render even the most basic functions of daily living such as lifting the hand to the mouth to eat or drink, to get dressed or manage personal hygiene, a painful and disabling process. If it is accepted that even the 'low demand' individual can suffer from radioulnar impingement, there therefore is no 'ideal' patient for resection arthroplasty and patients selected to undergo the procedure should be carefully counselled pre-operatively regarding the risk of instability and impingement syndrome. Patients receiving ulnar head resection need to be followed closely after surgery and this must include an assessment of satisfactory stability and load-bearing capacity for the activities of normal daily living. It is appreciated that in certain communities, there may be little or no access to prosthetic arthroplasty techniques, and in these circumstances, ulnar head resection may continue to remain an option for severe end stage DRUJ dysfunction. In all other cases of worn-out DRUJ or symptomatic impingement following resection arthroplasty, there now exist a number of alternative implant arthroplasty techniques that are accruing an excellent track record for total DRUJ reconstruction (see following sections). Indeed, in the face of such continued evidence, the place of the Darrach and Sauve-Kapandji techniques (and their derivatives) are becoming increasingly untenable, and hopefully, in the near future, will be consigned to the pages of history. Until then and in its simplest form, ulnar head resection in the

Darrach procedure removes the pain of advanced joint wear in situations of bone-on-bone contact within the DRUJ. Greater support for the carpus can be achieved through the Sauve-Kapandji procedure with retention and fusion of the ulnar head to the sigmoid notch of the radius. Pronosupination moves to the ulnar head osteotomy site but may be lost if bone bridges back across the gap left by the 15mm or so of excised ulna.

Joint Replacement Arthroplasty

Techniques for DRUJ reconstruction now include silastic, metallic or ceramic replacement for part or all of the ulna as well as total distal radioulnar joint replacement^{58,75,76}. In selecting the most appropriate technique for any given situation, it is important to bear in mind that hemi-arthroplasty techniques involving only one half of a load-bearing synovial joint run the risk of developing degenerative changes in the conserved half of the joint as has been well described for the hip and shoulder. Furthermore, instability of a hemi-arthroplasty and an unconstrained total joint prosthesis frequently occur and can be a difficult problem to manage. Establishing implant stability is an important key of the primary operation and begins with pre-operative planning. The joint should be assessed for stability based on clinical and radiological examination. If the joint is unstable then it is important to address the anatomical factors that contribute to instability, ie the sigmoid notch and the TFCC. If the TFCC is deficient, it must be stabilised with a TFCC repair

“Techniques for DRUJ reconstruction now include silastic, metallic or ceramic replacement for part or all of the ulna as well as total distal radioulnar joint replacement”

or reconstruction, stabilisation of the TFCC to the ulnar head prosthesis, or selection of a semi-constrained prosthesis instead. To obtain stability of a uni-polar ulnar prosthesis, it needs to be correctly positioned, the soft tissue balanced and stabilised and the sigmoid notch needs to provide a volar and dorsal buttress. A good quality closure of the dorsal capsule-retinacular tissues is also important for a hemi-arthroplasty and an unconstrained prosthesis and the forearm is often immobilised in the position of maximal stability for a few weeks to allow the soft tissues to heal.

Ulnar Resurfacing Techniques

Patients with predominant degenerative changes affecting the head of the ulna can be managed with a resurfacing arthroplasty to replace only the ulnar seat, and thereby preserve the stabilizing TFCC attachments at the fovea. Examples include the Ascension and Eclipse™ ulnar head systems that replace the articulating half of the ulnar head to retain the ulnar neck, ulnar styloid, extensor carpi ulnaris groove,

ulnocarpal ligament attachments, extensor carpi ulnaris sheath, and the TFCC attachments to the ulnar styloid. The Eclipse™ prosthesis is a pyrocarbon based design where the soft tissue envelope and joint wear is reduced with a bipolar ulnar construct in which the pyrocarbon arthroplasty component twists around an internal ulnar stem axis, thereby lowering friction with the radial notch⁷⁷. Sizing of any resurfacing prosthesis is critical as, if the prosthesis is too large, the joint will be tight, producing pain and restricting range of motion. If it is too small, the joint will be unstable and the ulnar head adjacent to the prosthesis can impinge upon the sigmoid notch during forearm rotation.

Total Ulnar Head Replacement

Complete distal ulnar replacement involves the joint surface and the remainder of the ulnar head. The uHead™ by Small Bone Innovations (SBI) and the E-Centrix by Wright Medical Tech, have the ability to capture sutures to allow repair of the TFCC for added stability. Instability of the ulnar head replacement prosthesis can occur if the soft tissues are not balanced, or if the sutures, which stabilise the prosthesis to the TFCC, rupture on the eyelets. Although positive short-term results are often touted, recurrent pain and joint instability due to the failure of the surrounding stabilizing soft-tissues represent the main challenges to success with such unconstrained unilateral joint replacement techniques⁷⁸. To address this problem, different soft tissue reconstruction techniques that aim to wrap around the arthroplasty have been described⁷⁹.

Total DRUJ Replacement

For those patients who have advanced degeneration involving both the distal ulna and the sigmoid notch, a total joint replacement can be considered. These are indicated in those cases with degeneration on both sides of the articulation, including those with instability. There are two options: unconstrained or semi-constrained designs.

Unconstrained Prosthesis

An unconstrained prosthesis involves the replacement of both the ulnar head and sigmoid notch joint surface and aims to work like a normal joint with normal kinematic motion and loading. In these systems, the articular surface of the arthroplasty is frequently intended to provide a similar stabilizing effect as in the anatomic situation (about 20%) and the soft tissue envelop needs to be intact or reconstructed to avoid gross instability. The Small Bone innovations implant utilises an ulnar component as described above for mono-polar reconstruction, partnered with a sigmoid notch replacement that has a metallic base plate with a polyethylene insert. It relies on good soft tissue stabilisation and good bone stock, and is therefore contra-indicated if these two pre-requisites are not available. The metallic base plate and the polyethylene insert introduce other potential complications including over distension of the joint, dissociation of the polyethylene liner and polyethylene wear.

Semi-Constrained Prosthesis

If the DRUJ is both degenerative and unstable, a semi-constrained prosthesis is a good option. A semi-constrained

"Patients with a destroyed DRUJ can now be offered salvage reconstruction techniques that have the possibility of transforming their functional capacity, alleviating pain, and offering great rewards for both the patient and treating surgeon alike."

prosthesis can mobilise in its primary plane, but has limited or constrained motion in alternative planes. This has the dual advantages of both preventing prosthetic instability whilst permitting small out of plane motion that minimizes unwanted force transmission at the prosthesis / bone (or cement) interface. This approach fits the biomechanics of the DRUJ very well with the major plane of motion through pronosupination and minor proximo-distal motion from physiological ulnar variance alteration as the radius moves from full supination to pronation. The Scheker arthroplasty was developed to replace the DRUJ in such a semi-constrained manner, and allows complete stability through the full range of pronosupination whilst accommodating minor axial length changes associated with physiologic longitudinal translocation 75,80-82.

The ulnar component of the Scheker prosthesis consists of an un-cemented stem that extends to the level of the DRUJ to become the centre of rotation of the joint and on which is mounted a freely rotating polythene ball. A plate is secured to the distal radius, containing a cage that encases the polythene ball. The primary motion of the joint, forearm rotation, occurs as the polyethylene ball rotates unrestrained around the ulnar stem. Alternative axial motion and minor tilt occur at the ball-ulnar stem and ball-cage interfaces respectively. Anterior posterior motion is completely restrained and so reconstructs the stability component of the DRUJ.

Salvage Surgery

Much has been written in the literature about possible salvage procedures for the worldwide population of patients who suffer from radioulnar impingement following ablation of the ulnar head. It is the opinion of the senior author that they offer no significant benefit in addressing this problem and the reader is therefore directed to other works in the literature for historical information on these techniques. Alternatively, for those cases where the ulnar head has been removed, and in unique cases of distal ulnar loss for tumour extirpation or trauma, there are now custom implant fabrications that can be used for reconstruction, possibly in conjunction with free tissue transfer to replace and reconstruct missing bony and soft tissue elements.

Concluding remarks

Osteoarthritis is a complex disease that continues to carry a high morbidity for affected individuals and is as yet

refractory to efforts aimed at arresting the destructive process on affected synovial joints. Whilst new insights into the underlying pathobiological processes are now forthcoming, it will be a long time before reconstructive joint surgery can be consigned to the pages of history through pharmacological arrest of the disease process. For the DRUJ, this is of great importance for two reasons. Firstly, there is now an excellent spectrum of operative procedures that can restore good function both when there remains a salvageable joint and through arthroplastic techniques when the joint is beyond repair. Secondly, there is a potentially huge population of people in the international community who have undergone previous DRUJ ablation producing radioulnar impingement. This situation has arisen through a lack of appreciation of the essential biomechanical role that the DRUJ fulfils. This appreciation has steadily caught up with the great advances in radiocarpal pathology thanks to the research efforts of many hand surgery giants, including Hagert, Palmer, and others^{26,33,83}. Patients with a destroyed DRUJ can now be offered salvage reconstruction techniques that have the possibility of transforming their functional capacity, alleviating pain, and offering great rewards for both the patient and treating surgeon alike.

References

47. Bernard C, Huette C. Illustrated Manual of Operated Surgery and Surgical Anatomy. In: Buren WHV, Isaacs C, ed. New York 1857.
48. Malgaigne JF. Traite des fractures et des luxations. Volume II. Paris 1855.
49. Darrach W. Anterior Dislocation of the Head of the Ulna. *Annals of Surgery*. 1912;56:802-803.
50. Dingman PV. Resection of the distal end of the ulna (Darrach operation); an end result study of twenty four cases. *The Journal of Bone and Joint Surgery American Volume*. 1952;34(A(4)):893-900.
51. Taleisnik J. The Sauve-Kapandji procedure. *Clin Orthop Relat Res*. 1992(275):110-123.
52. Sauve L, Kapandji M. Nouvelle technique de traitement chirurgical des luxations récidivantes isolées de l'extrémité inférieure du cubitus. *J Chirurgie*. 1936;47:589-594.
53. Bowers WH. Distal radioulnar joint arthroplasty: the hemiresection-interposition technique. *J Hand Surg Am*. 1985;10(2):169-178.
54. Watson HK, Ryu JY, Burgess RC. Matched distal ulnar resection. *J Hand Surg Am*. 1986;11(6):812-817.
55. Wolfe SW, Mih AD, Hotchkiss RN, Culp RW, Keifhaber TR, Nagle DJ. Wide excision of the distal ulna: a multicenter case study. *J Hand Surg Am*. 1998;23(2):222-228.
56. Bain GI, Bergman FJ. The distal radioulnar joint: contemporary perspectives. *Tech Hand Up Extrem Surg*. 2007;11(1):37.
57. Anderson ML, Larson AN, Moran SL, Cooney WP, Amrami KK, Berger RA. Clinical comparison of arthroscopic versus open repair of triangular fibrocartilage complex tears. *J Hand Surg Am*. 2008;33(5):675-682.
58. Thomas BP, Sreekanth R. Distal radioulnar joint injuries. *Indian J Orthop*. 2012;46(5):493-504.
59. Tse WL, Lau SW, Wong WY, et al. Arthroscopic reconstruction of triangular fibrocartilage complex (TFCC) with tendon graft for chronic DRUJ instability. *Injury*. 2013.
60. Adams BD, Berger RA. An anatomic reconstruction of the distal radioulnar ligaments for posttraumatic distal radioulnar joint instability. *J Hand Surg Am*. 2002;27(2):243-251.
61. Gupta A. Brachioradialis Wrap: A New Method of Stabilizing the Distal Radioulnar Joint. In: Slutsky D, ed. *Principles and Practice of Wrist Surgery*. Philadelphia: Saunders Elsevier. 2010; 358-361.
62. Scheker LR, Ozer K. Ligamentous stabilization of the distal radioulnar joint. *Tech Hand Up Extrem Surg*. 2004;8(4):239-246.
63. Scheker LR, von Schroeder H. Dorsal stabilization of the distal radioulnar joint. *Tech Hand Up Extrem Surg*. 1998;2(4):234-241.
64. Scheker LR, Belliappa PP, Acosta R, German DS. Reconstruction of the dorsal ligament of the triangular fibrocartilage complex. *J Hand Surg Br*. 1994;19(3):310-318.
65. Dy CJ, Ouellette EA, Makowski AL. Extensor retinaculum capsulorrhaphy for ulnocarpal and distal radioulnar instability: the Herbert sling. *Tech Hand Up Extrem Surg*. 2009;13(1):19-22.
66. Tham SK, Bain GI. Sigmoid notch osseous reconstruction. *Tech Hand Up Extrem Surg*. 2007;11(1):93-97.
67. Wallwork NA, Bain GI. Sigmoid notch osteoplasty for chronic volar instability of the distal radioulnar joint: a case report. *J Hand Surg Am*. 2001;26(3):454-459.
68. Scheker LR, Severo A. Ulnar shortening for the treatment of early post-traumatic osteoarthritis at the distal radioulnar joint. *J Hand Surg Br*. 2001;26(1):41-44.
69. Milch H. Cuff Resection of the Ulna for Malunited Colle's Fracture. *Journal of Bone and Joint Surgery*. 1941;20A:959-964.
70. Lapner PC, Poitras P, Backman D, Giachino AA, Conway AF. The effect of the wafer procedure on pressure in the distal radioulnar joint. *J Hand Surg Am*. 2004;29(1):80-84.
71. Markolf KL, Tejwani SG, Benhaim P. Effects of wafer resection and hemiresection from the distal ulna on load-sharing at the wrist: a cadaveric study. *J Hand Surg Am*. 2005;30(2):351-358.
72. Nishiwaki M, Nakamura T, Nakao Y, Nagura T, Toyama Y. Ulnar shortening effect on distal radioulnar joint stability: a biomechanical study. *J Hand Surg Am*. 2005;30(4):719-726.
73. Sennwald G, Della Santa D, Beaulieu JY. A comparison of diaphyseal and metaphyseal techniques of ulna shortening. *J Hand Surg Eur Vol*. 2013;38(5):542-549.
74. Barry JA, Macksoud WS. Cartilage-retaining wafer resection osteotomy of the distal ulna. *Clin Orthop Relat Res*. 2008;466(2):396-401.
75. Laurentin-Perez LA, Goodwin AN, Babb BA, Scheker LR. A study of functional outcomes following implantation of a total distal radioulnar joint prosthesis. *J Hand Surg Eur Vol*. 2008;33(1):18-28.
76. Stanley D, Herbert TJ. The Swanson ulnar head prosthesis for post-traumatic disorders of the distal radio-ulnar joint. *J Hand Surg Br*. 1992;17(6):682-688.
77. Garcia-Elias M. Eclipse: partial ulnar head replacement for the isolated distal radio-ulnar joint arthrosis. *Tech Hand Up Extrem Surg*. 2007;11(1):121-128.
78. Willis AA, Berger RA, Cooney WP, 3rd. Arthroplasty of the distal radioulnar joint using a new ulnar head endoprosthesis: preliminary report. *J Hand Surg Am*. 2007;32(2):177-189.
79. Sauerbier M, Hahn ME, Berglund LJ, An KN, Berger RA. Biomechanical evaluation of the dynamic radioulnar convergence after ulnar head resection, two soft tissue stabilization methods of the distal ulna and ulnar head prosthesis implantation. *Arch Orthop Trauma Surg*. 2011;131(1):15-26.
80. Coffey MJ, Scheker LR, Thirkannad SM. Total distal radioulnar joint arthroplasty in adults with symptomatic Madelung's deformity. *Hand (N Y)*. 2009;4(4):427-431.
81. Degreef I, De Smet L. The Scheker distal radioulnar joint arthroplasty to unravel a virtually unsolvable problem. *Acta Orthop Belg*. 2013;79(2):141-145.
82. Scheker LR. Implant arthroplasty for the distal radioulnar joint. *J Hand Surg Am*. 2008;33(9):1639-1644.
83. Palmer AK, Werner FW. The triangular fibrocartilage complex of the wrist—anatomy and function. *J Hand Surg Am*. 1981;6(2):153-162.

IFSSH Scientific Committee on Microsurgery

Chair: Alexandru Georgescu (Romania)

Committee: Michel Saint-Cyr (USA), Joon Pio Hong (South Korea), Pierluigi Tos (Italy), Ferit Demirkan (Turkey)

Report submitted March 2014

Propeller Perforator Flaps in Forearm and Hand Reconstruction

Historical Perspective

Various methods have been used over the time for reconstruction of challenging tissue defects of the upper limb. But, if for the arm and proximal half of the forearm, the use of a free split thickness graft (FSTG) is generally adequate, the problem becomes more difficult for coverage of tissue defects in the distal forearm and hand. The superficial positioning of important anatomical structures (i.e. tendons, vessels, nerves, bones) in these regions imposes in the large majority of cases the use of local, regional, pedicled or free flaps. A good reconstructive procedure should achieve both cosmetic and functional results and should be customised for a specific defect.

After a long evolution in flap surgery, which included random pattern flaps, muscle and musculocutaneous flaps, fasciocutaneous flaps, Taylor and Palmer¹ reappraised the works of Manchot² and Salmon^[3] regarding skin blood supply. They developed the angiosome concept, showing that this represents a block of tissue supplied by a same source artery and vein through branches for all tissues

between skin and bone. At the same time, neighbouring angiosomes are linked to each other via "choke vessels". A step forward was represented by the work of Saint-Cyr et al⁴, which focused on the perforator vessels and not the source vessel anymore. After conducting several anatomical studies, they defined the "perforasome" as the vascular territory of a single perforator (Fig. 1), and enunciated four clinically relevant principles:

1. The perforasomes are interconnected by direct and indirect linking vessels (Fig. 2). The direct linking vessels are macroscopic vessels establishing a direct "bridge" between branches of adjacent perforators. The indirect linking vessels are the equivalent

of the "choke vessels" described by Taylor and Palmer¹, and constitute the microscopic subdermal network.

2. The orientation of linking vessels dictates the design of a flap: axial in the extremities (Fig. 3), and perpendicular to the midline in the trunk.
3. Perforators from a specific source have perforasomes that will be preferentially filled before filling perforasomes from adjacent source vessels
4. The location of a perforator is critical for the inter-perforasome blood flow: the blood flow in linking vessels is distal from joints or non-mobile skin, but when a perforator is relatively centrally located in between two joints, the flow is multi-directional.

Moreover, Rubino et al⁵ have shown that by harvesting a flap based on a single perforator, the perfusion in this perforator will increase and contribute to the recruitment of adjacent perforasome territories. That can explain the large dimensions of some flaps.

As a result of this evolution, and

"A good reconstructive procedure should achieve both cosmetic and functional results and should be customised for a specific defect."

following the harvesting of the first flaps sparing the source artery and underlying muscle performed by Kroll and Rosenfield in 1988⁶ and Koshima and Soeda in 1989⁷, the use of perforator flaps became increasingly more extensive. Free perforator flaps such as the anterolateral thigh flap, thoracodorsal artery perforator flaps, lateral arm perforator flap, inferior epigastric artery perforator flap, and the biceps femoris perforator flap are used successfully for reconstruction of tissue defects in the upper limb.

The distant donor site, the difficulties in obtaining a similar reconstruction, and the technical high-demand procedure are some of the factors that stimulated surgeons to find alternatives to free flaps. In recent years, the use of local perforator flaps gained a big popularity, mainly due to some advantages: (1) replacing like with like, (2) donor site in the same area, (3) possibility of complete or partial donor site primary closure, (4) less demanding from technical point of view, because they do not need microvascular sutures (microsurgical non-microvascular flaps), and (5) shorter operating time⁸⁻¹¹.

Chang et al¹² described for the first time in 1988 a fasciocutaneous forearm reverse flap by sparing the radial artery (RA), but the real interest in using local perforator flaps only became manifest from 1994. Starting with this moment, the use of local perforator flaps in forearm and hand reconstruction became increasingly extensive. Even if these flaps can be used as pedicled and transposition flaps, their use as propeller flaps seems to be more useful and is preferred by most surgeons.

Hyakusoku et al¹³ introduced in 1991 for the first time the term, propeller flap, to describe an adipocutaneous flap with blood supply through a random subcutaneous pedicle and rotated through 90 degrees. Later on, Hallock¹⁴ used this term for the first time to define a perforator flap rotated through 180 degrees. The Advisory Panel of the First Tokyo Meeting on Perforator and Propeller Flaps established in 2009 the definition and terminology of propeller perforator flaps: a skin island with two paddles demarcated by the perforator vessel, which has to rotate through at least 90

to 180 degrees¹⁵.

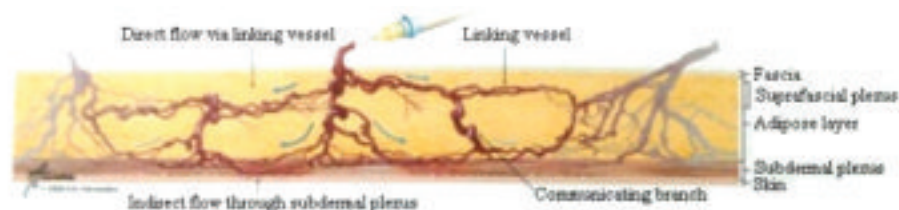
Besides the advantages described above, there are also some possible drawbacks in using these flaps. The most important complications are represented by complete or partial flap loss due to venous problems, but the general complication rate is similar to that for free flaps. In an attempt to minimise the complication rate, the venous supercharging of a flap may be necessary. Of great importance is also the very thoughtful planning and design of the flap, as well as the length of the perforator. One of the most important factors in diminishing the complication rate is the necessity to establish the realistic dimensions of such a flap, in other words the safe vascular limits of a perforator pedicle. While at the beginning it was considered that the dimensions of a perforator

Perforasome

Figure 1 (left):

Figure 2 (below): Direct and indirect linking vessels

Figure 3 (right): Direction of flow via linking vessels



flap should not exceed the distance between two perforators, Saint-Cyr et al.⁴ demonstrated that the single perforator of a flap is hyperperfused, which increases its filling pressure and opens the linking vessels with adjacent territories. It is easy to understand that the possibility of establishing before or during surgery the safer dimensions of a flap can dramatically ameliorate the success rate. A lot of methods were used for this purpose, such as handheld Doppler, colour Doppler, Duplex ultrasound, arteriography, magnetic resonance angiography, and high-resolution computed tomography. No single method provides information regarding flap viability, but only about the perforator's distribution and/or calibre¹¹. The flap perfusion, but not the dimensions of a flap, can be tested during surgery by fluorescein^{11, 16, 17} or indocyanine green near-infrared angiography^{11, 18-20}.

Due to the superficial location of the main axial source vessels in the distal forearm and hand, the identification of perforator vessels by Doppler examination before surgery is not very useful, because of possible false positive or negative results^{9, 10}. In these conditions, it seems more reasonable to find the perforators during surgery by careful microsurgical dissection, and only after that to design the flap: that means to perform a free-style propeller perforator flap.

Propeller Perforator Flaps in the Forearm and Hand

The methods used in the reconstruction of substance loss in the forearm and hand aim to transfer

"The reconstruction with propeller perforator flaps replaces like-with-like by using tissues of similar texture, thickness, pliability, and colour"

structurally and functionally similar tissues with the price of a low or absent donor site morbidity. It is more than evident that the better way to replace like with like is through the use of local or regional flaps.

Anatomical considerations

The main axial arteries of the forearm, i.e. RA, ulnar artery (UA), posterior interosseous artery (PIOA), and anterior interosseous artery (AIOA), contribute to the perfusion of specific areas of the skin, and constitute a rich anastomotic network with perforator branches providing blood supply to the skin, as well as the muscles. In the forearm, the main vessels follow the axis of the limb, and their perforators connect to each other by means of direct and indirect linking vessels⁴. Between the main arteries there are also some transverse connections, which allow harvesting flaps with pedicles based proximally or distally on the perforators of those arteries²¹.

The hand has also a very rich vascularisation, based on perforators from the vascular arches realised mainly between the dorsal carpal arch (DCA) and the palmar arterial system^{22, 23}, but also on perforators of the common digital arteries (CDA) and proper digital arteries (PDA)²⁴.

Radial Artery

The RA vascularises the skin between the projection of the palmaris longus and the projection of the lateral edge of the extensor digitorum communis, excepting a small area over the lower part of the extensor pollicis brevis and abductor pollicis longus, which is supplied by the AIOA²⁵. The territory of the RA extends proximally up to 5-8cm distal to the epicondylar line of the elbow, but when the inferior cubital artery is present its territory can extend more proximally.

As demonstrated by Saint-Cyr et al, the main perforators of the RA are distributed in two clusters of clinical relevance²⁶. The first one is located in the proximal third of the forearm, whereas the second one can be found in the distal fifth of the forearm (Fig. 4). These perforators arise between brachioradialis and pronator teres in the proximal third of the forearm and between brachioradialis and flexor carpi radialis in the distal two thirds of the forearm. In the proximal part the perforators are both muscular and septocutaneous, but in the distal part they are only septocutaneous. One of the septocutaneous perforators in the proximal part is represented by the inferior cubital artery described by Lamberty and Cormack, which is the largest RA perforator and which allows the harvesting of a flap extending 10cm distally from the apex of the antecubital fossa. Two large perforators can be also found within 2cm proximal to the radial styloid (Fig. 5). Other numerous but smaller perforators can be found between 2 and 7cm above the radial styloid (external diameter of 0.3-0.5mm). Moreover, one of the

Figure 4 (left): Dissection in a fresh cadaver forearm, after latex injection. The picture shows the distribution of the perforators of RA and UA. The small stars indicate the main perforators of RA and UA.

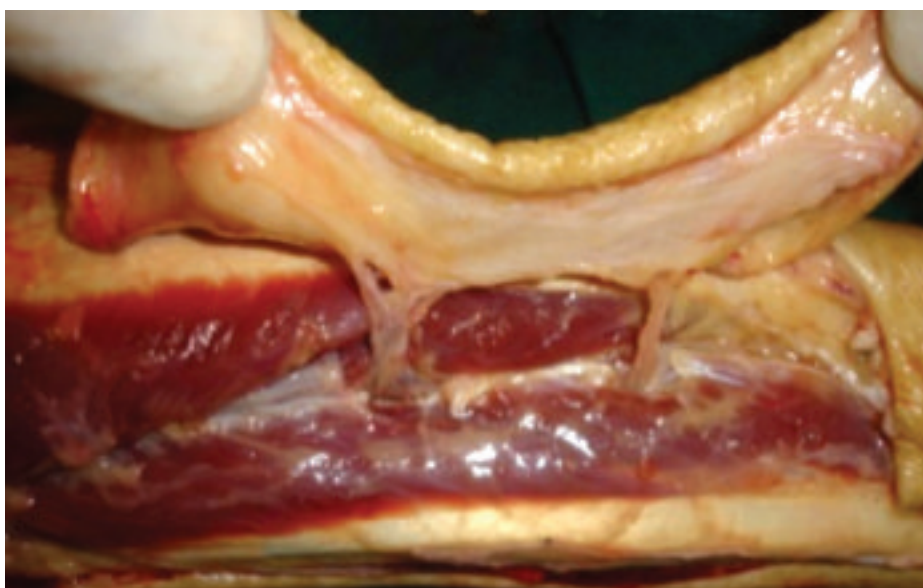
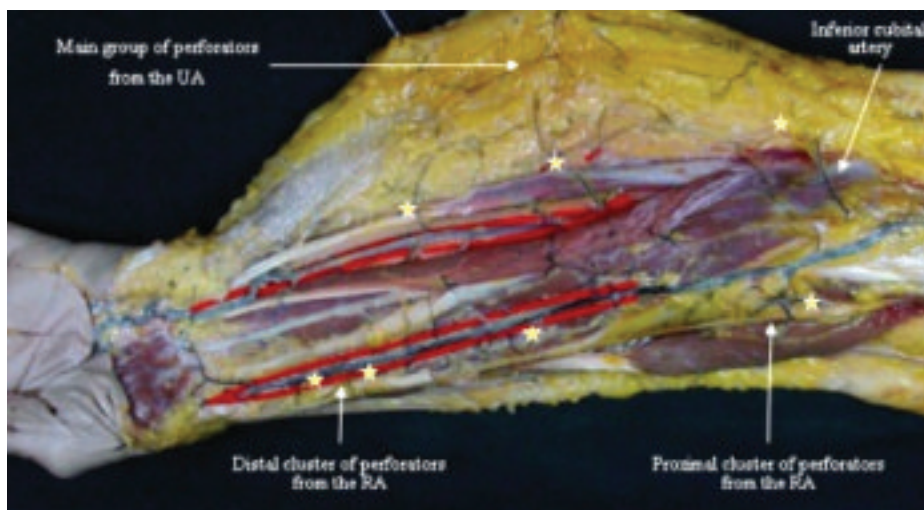
Figure 5 (right): Dissection in a fresh cadaver forearm. The two main perforators of the RA in the distal cluster can be viewed.

dorsal perforators given by the RA in the distal part, and which is running under or over the brachioradialis tendon and penetrating through it and the abductor pollicis longus tendon, represents the vascular pedicle of a flap described by Koshima et al ²⁷.

Ulnar Artery

The territory vascularised by the UA extends between the projection of the palmaris longus and the projection of the posterior subcutaneous border of the ulna.

The main group of perforators is found in the distal 2/3 of the forearm, the most important being located most frequently at about 8cm proximal to the pisiform bone (Figure 4). Yu et al have demonstrated that at least 2 or 3 perforators were consistently found in the forearm, on a line connecting the pisiform and the volar aspect of the epicondyle, or slightly ulnar to this line ²⁸. Sun et al demonstrated that the ulnar artery had two main clusters of perforators in the proximal one-third (7.73cm +/-1.14 distal to the medial epicondyle) and distal one-fourth (4.57cm +/-0.59 proximal to the pisiform bone) of the forearm. Both these clusters emerged from the space between the flexor digitorum



superficialis and the flexor carpi ulnaris muscles. In a large series over 27 years, Mathy et Al. have found between 0 and 6 perforators in each forearm. At least one perforator was found in 94% of the cases within 3cm of the midpoint of the line joining the pisiform bone and the medial epicondyle, and in 100% of the cases within 6cm of the midpoint of the same line ²⁹.

Posterior Interosseous Artery

The perfusion territory of the PIOA extends in a 5cm wide strip from the

lateral epicondyle to the head of the ulna.

There is an average of 5 large clinically relevant perforators arising from the PIOA and providing blood supply to the dorsal aspect of the forearm. These perforators tend to be more proximally located (Fig. 6). The perforators found in the lower third of the dorsal aspect of the forearm arise from the AIOA rather than the PIOA ³⁰⁻³². Angrigiani et al ³⁰ and Hubmer et al ³¹ have studied the anastomotic network between the AIOA and PIOA

and have found that the distal third of the posterior forearm is vascularised by a recurrent dorsal branch of the AIOA.

On the wrist level, the most distal perforators of the PIOA realise anastomoses with the AIOA, the dorsal carpal arch, and the UA ³³.

Anterior Interosseous Artery

The perfusion territory of the AIOA is represented by the skin over the lower part of extensor pollicis brevis and abductor pollicis longus, and is realised through three perforating branches. The most important of these perforators emerges at the proximal border of the pronator quadratus muscle and supplies the skin over the distal 2/3 of the dorsal aspect of the forearm ³⁴.

As shown by Yousif et al, the perforators emerging from these

source arteries can travel either within or in close proximity to the deep fascia or through the subcutaneous tissue ³⁵. It seems that the main source of the blood supply for the skin remains the subcutaneous arterial network. This was demonstrated by Schaverien and Saint-Cyr in a CT-angiography analysis on fresh cadavers. The authors investigated the perfusion patterns of both the subfascial and suprafascial forearm flaps with computed tomography. The 3D angiographies that were obtained showed no statistically relevant differences between the two techniques, indicating that a suprafascial dissection of the radial forearm flap does not compromise its blood supply ³⁶.

The venous drainage of the skin is realised through one or two venae comitantes accompanying each

perforator artery, and which realise a very rich venous plexus draining both into the superficial and deep systems of veins.

Metacarpal Arteries

The first dorsal metacarpal artery (DMA) and the DCA originate directly from the RA before it enters the palm. The second through fifth DMAs emerge subsequently from the DCA. The first, second and third DMAs are present in over 95% of the cases, whereas the fourth and fifth DMAs appear less consistent ^{37,38}. The first through fifth DMAs have a mean diameter of respectively 0.6, 0.8, 0.5, 0.4 and 0.2mm. The DMAs provide four to eight perforators (0.1-0.3mm in diameter) to the skin ³⁸. The DMAs run distal and pass through to the palmar arterial system at the metacarpal head level. A perforator originates from the junction between these vascular systems ²³. This perforator supplies the dorsal skin of the hand and is known as the perforator from the dorsal communicating branch of the common digital artery (CDA) or Quaba perforator. The blood flow is provided by the anterograde flow from the DMA or retrograde flow from the palmar artery system or dorsal digital arteries. The flaps based on this perforator can cover defects to the distal interphalangeal (DIP) joint. At the level of the proximal half of the first phalanx (P1) of the long fingers, corresponding to the 2nd to 4th web spaces, there

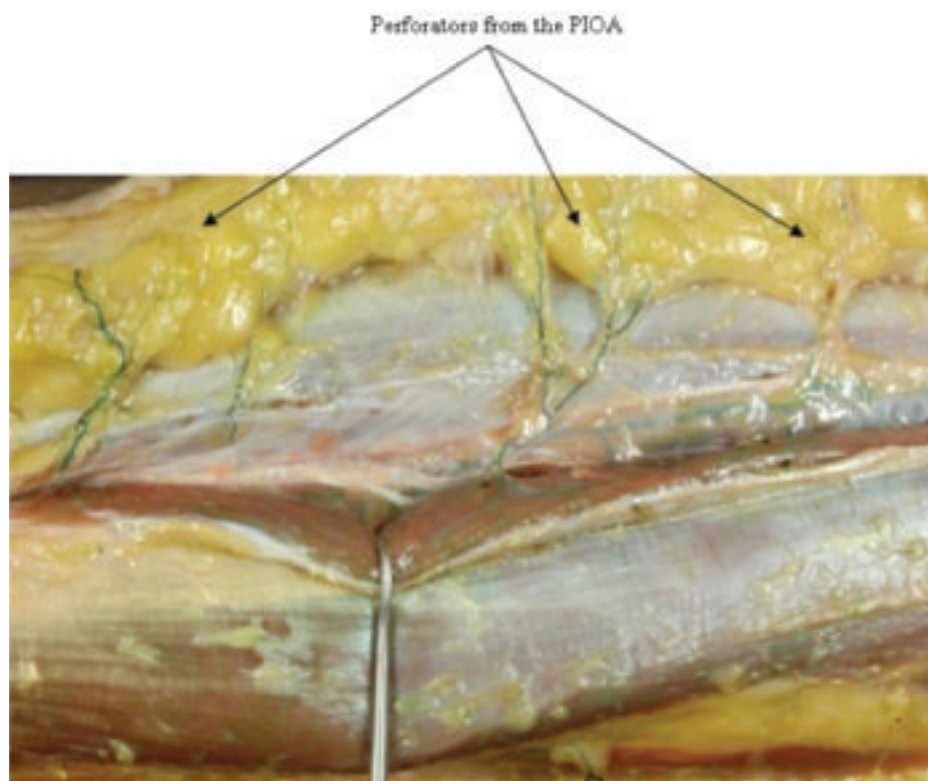


Figure 6: Dissection in a fresh cadaver forearm, after latex injection. The main perforators of the PIOA can be viewed.

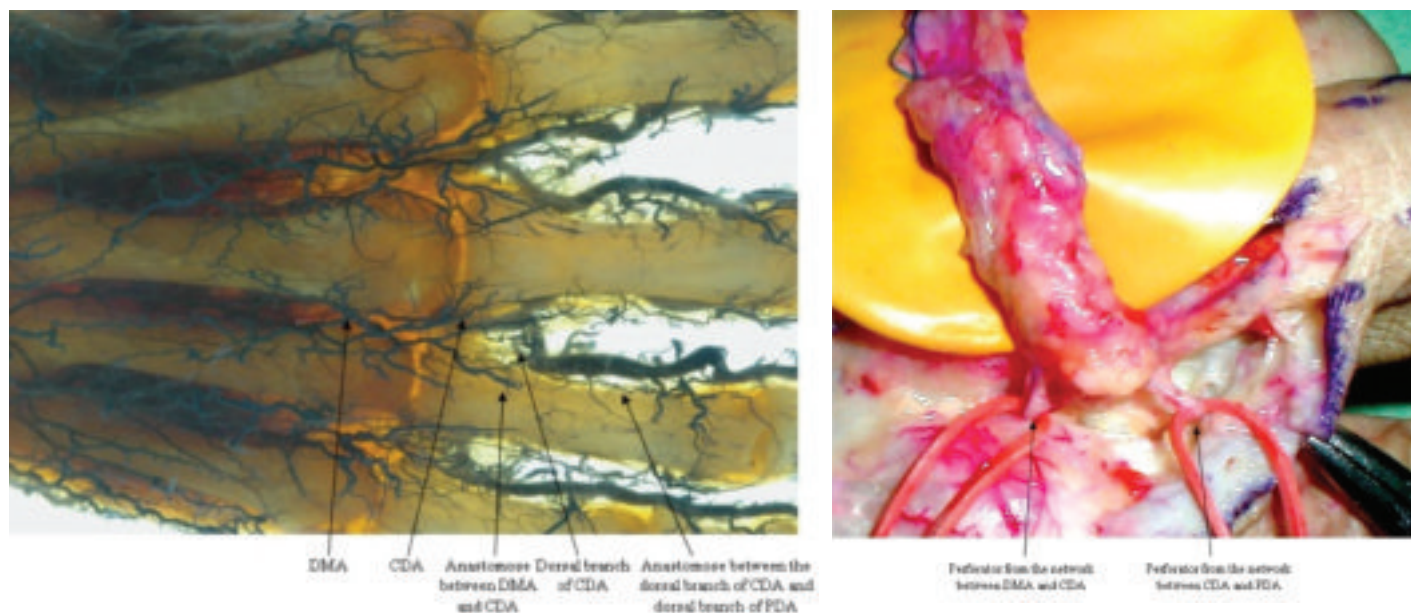
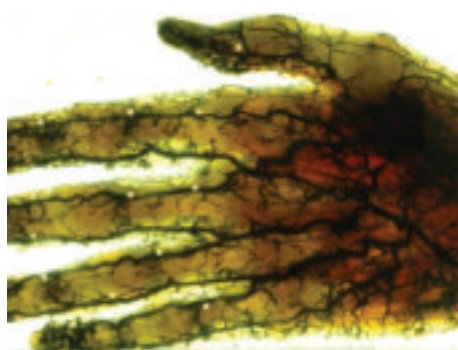


Figure 7: Dorsal metacarpal artery (DMA) and its anastomoses with the digital arteries. Left: Transparentation technique applied on fresh cadaver hand specimen with the arterial system injected with latex. Right: Dissection in a fresh cadaver hand showing the above mentioned anastomoses. (CDA - common digital artery; PDA - proper digital artery)

are two important anastomoses: (1) at the union of the proximal with the middle third of the P1, between the DMA and the CDA; (2) at the middle of the P1, between the dorsal branch of the CDA and the dorsal branch of the PDA (Fig. 7). Because of the more distal situation of the pivot point, these flaps

Figure 8: Transparentation technique applied on fresh cadaver hand specimen with the arterial system injected with latex. The small stars indicate some of the perforators of the PDAs.



can reach also the distal phalanx, both dorsal and volar³⁹.

Digital Arteries

The digital arteries give many branches on both lateral and medial aspects of the fingers⁴⁰ (Fig. 8). After perforating the thin fascia and subcutaneous tissue, these branches end through multiple arterioles into the subdermal layer. There are very rich anastomoses between these perforators at the level of the lateral and medial midlines of the fingers. The venous drainage is realised through small venules, which connect to the dorsal and palmar cutaneous venous systems in the subcutaneous tissue. Small branches of the digital nerves, together with their rich vascular network, are also present and very close to the vascular network. In conclusion, the blood supply of the dorsal aspect of the long fingers is realised as follows: (1) through

perforators from the DMA at the level of the web space and metacarpal head; (2) through dorsal digital arteries emerging from the DMA in the proximal half of the P1; (3) through branches of the PDA; (4) through 1-2 small branches of the PDA at the level of the middle phalanx; (5) through a few arches originating in the PDA at the level of the distal phalanx.

Flap designs and harvesting techniques of propeller perforator flaps in the forearm and hand

Design of the flap.

The preoperative planning of perforator flaps by using diverse imaging techniques and hand-held Doppler is not very useful in the forearm because of the proximity of the main source arteries as well as their superficial location within the forearm. It is also relatively difficult to do this in the hand and fingers^{9, 10, 26}. This is

why, generally, the identification and isolation of the perforators is done intraoperatively through a careful dissection and consideration of the defect needs.

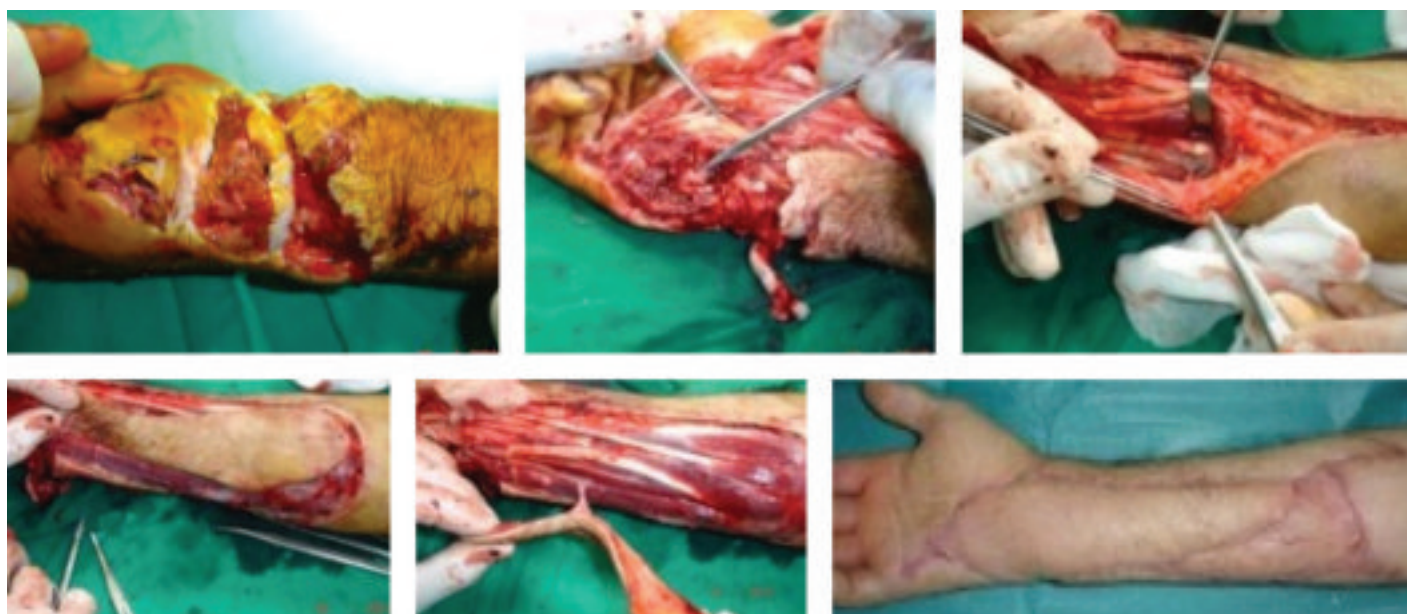Harvesting technique (Fig. 9)

Only one edge of the potential flap is incised at the beginning. It is better to place this incision so that it is possible to be the limit of a second flap option, if a suitable perforator is not found. The incision can be either supra or subfascial. The dissection is performed under magnification and all the identified perforators are preserved. If more adjacent perforators of similar calibre are found, it is better to keep them until the releasing of the tourniquet, and decide on which will be used as the vascular pedicle of the flap only after clamping them

alternately. The definitive design of the flap is accomplished according to the chosen perforator, and its location, size, number of venae comitantes, course and orientation. The long axis of the flap should be orientated in the long axis of the segment. The length of the flap should be greater than the distance between the perforator and the most distant edge of the defect adding 1-2cm in the forearm and 0.5-1cm in the hand and fingers. Similar, to the width of the defect is added 0.5-1cm to allow closure without tension. After enlarging the perforator foramen, the perforator is cleared of all muscular branches and fascial strands for at least 2cm in the forearm and 1cm in the hand and fingers, but no longer than needed for an optimal rotation of the flap. It is not necessary to completely skeletonise

the perforator pedicle, but it is better, especially in the fingers, to retain a small cuff of tissue around it to avoid the vessel spasm. After that, the incision around the flap is completed, but the flap should be rotated only after releasing the tourniquet and observing the pulsation of the perforator. If pulsation is not yet present, it is better to maintain the flap in its original position for 10-15 minutes to allow the spasm to disappear. Attention should be paid to the correct rotational direction to avoid kinking of the perforator. Closure of the donor site under tension should be avoided to prevent reduction of the flap's blood supply by compression of the source vessel and swelling of the distal segment. If closure by direct suture is not possible, the use of a FSTG is indicated.

Figure 9: Complex wound in the distal forearm and hypothenar region - technique of harvesting of a propeller perforator flap – A) Preoperative aspect; B) Remaining defect after debridement; C) Incision of only one edge of the potential flap and identification of a perforator of the ulnar artery through careful microsurgical dissection; D) After the final design of the ulnar artery propeller perforator flap, according to the location of the chosen perforator, the flap is completely incised; E) The harvested flap will be rotated 180 degrees to cover the defect; F) Postoperative result after 6 months.



Indications for propeller perforator flaps in the forearm and hand

The main advantages of propeller perforator flaps recommend them as a valuable option in the reconstruction armamentarium. The surgical procedure is relatively easy and less time consuming, which offers a lot of benefits to the elderly, multiple injured patients, or to those with a compromised general health status. The reconstruction with propeller perforator flaps replaces like-with-like by using tissues of similar texture, thickness, pliability, and colour. Moreover, this method avoids the complexity, the multiple surgical sites and the high costs associated with free flaps and microsurgery. Preserving the source artery and the underlying muscle, the propeller perforator flaps reduce drastically the donor site morbidity. For flaps with a width less than 4-5cm the donor site can be closed by direct suture, but even bigger defects can be partially directly sutured. The cosmetic appearance of the donor site can represent a significant drawback, but generally this one can be easily tolerated in very complex defects. A potential disadvantage can be related to the location of the perforator within the zone of injury, but generally this fact does not interfere with the viability of the flaps.

The main indication for propeller perforator flaps is the coverage of small to medium size defects, but sometimes their dimensions could be larger. This happens in cases in which a perforator vessel cannot be found close to the defect. We harvested some larger flaps based on

"the presence of numerous perforator vessels supplying the forearm, hand and fingers makes the harvesting of local perforator flaps in order to cover small and medium size defects"

a single perforator, and the largest one in the forearm in our experience was an ulnar artery perforator flap of 28X6cm (170sqcm). The explanation for survival of such big flaps can be found in the perforasome concept of Saint-Cyr et al⁴, according to which the hyperperfusion in a perforator allows the capture of multiple adjacent perforasomes through direct and indirect linking vessels.

The radial artery propeller perforator flap (RAPPF) is very thin and pliable, and can be harvested as chimeric flap including bone, muscle, tendons, but can also be innervated and used as a sensate flap. Based on perforators from the proximal group, the flap is very useful for coverage of elbow defects. The flaps based on distal perforators are very useful for coverage of hand defects. The RAPPF can also be used as an adipofascial perforator flap, very useful in the coverage of volar and dorsal hand wounds, treatment of recurrent de Quervain's tendonitis, flexor tendon sheath reconstruction and wrist and median nerve padding. The use in such a way avoids the bulkiness

observed after using a fasciocutaneous flap and ameliorates very much the donor site appearance. The donor site morbidity associated with the RAPPF when used as a fasciocutaneous flap, can sometimes surpass its advantages. Even if from a functional point of view the morbidity can be minimised by harvesting the flap in a suprafascial plane, there still remain some drawbacks from the cosmetic point of view.

The ulnar artery propeller perforator flap (UAPPF) is also very thin and pliable, but is thinner and hairless if compared with the RAPPF (Fig. 9). It can be also designed as a chimeric flap including bone, muscle and tendon. It seems that because of all these facts, but also due to the lesser exposure of the tendons, the UAPPF leads to better functional and cosmetic outcomes²⁸. The flap is very useful in the coverage of the dorsal aspect of the hand, of the hypothenar area and of the volar aspect of the wrist.

Both the posterior interosseous artery propeller perforator flap (PIOAPPF) and the anterior interosseous artery propeller perforator flap (AIOAPPF) have a structure very close to the hand skin texture, which allows reconstructions of the dorsal hand with good outcomes, both functional and cosmetic.³² The PIOAPPF can be also harvested based on proximal perforators, finding its indication in coverage of elbow defects.

The dorsal metacarpal propeller perforator flap finds its indication in the coverage of small defects of the dorsal aspect of the hand and fingers to the DIP joint, but also for

more extensive defects of the fingers up to the distal phalanx, both volar and dorsal, when they are harvested based on commissural perforators – commissural propeller perforator flap (Fig. 10).

The digital artery propeller perforator flap (DAPPF) was first described by Koshima et al for fingertip reconstruction⁴⁰, but the flap can be successfully used also for covering more proximal defects on both palmar and dorsal aspect of the fingers (Fig. 11, Fig. 12). It can be used also as sensate flap in covering the palmar aspect of the fingers.

For a width of the flap less than 0.8cm the donor site can be directly closed, but for larger flaps a free skin graft is needed. To avoid this disadvantage, the flap can be designed as a bi-lobed pedicled flap based on the same perforator vessels, which

need not be identified (Fig. 13, Fig. 14). In this case, the first lobe represents the flap which will cover the defect, and is designed transversely or slightly obliquely; the second flap, which will cover the donor site of the first flap, is designed longitudinally and has a maximum width of 2/3 from the width of the first one. The donor site of the second flap can be directly sutured.

Complications

The most common complication of propeller perforator flaps is represented by venous congestion of the tip or of the entire flap, and is due to the insufficient flow in the perforator pedicle. This happens either because of inadequate selection of the perforator, or due to its insufficient dissection and mobilisation, especially around the vein. If venous congestion is observed intra-operatively, venous

supercharging of the flap can be done by performing a microvascular venous anastomosis. In instances of signs of ischemia, derotation of the flap to its original position can be attempted. In instances of vascular problems appearing after surgery, some flaps can be saved by removing the stitches, by doing small punctures or incisions and applying local heparinisation, or by using leeches.

If compared with free flaps, the loss of a propeller perforator flap, involves generally only partial thickness of the flap. If a free flap is lost, everything is lost, while generally in a propeller perforator flap only the superficial part is lost. This means that the flap has done its job of covering the denuded anatomical elements, because after debridement granulation of the wound is very fast and allows skin grafting.

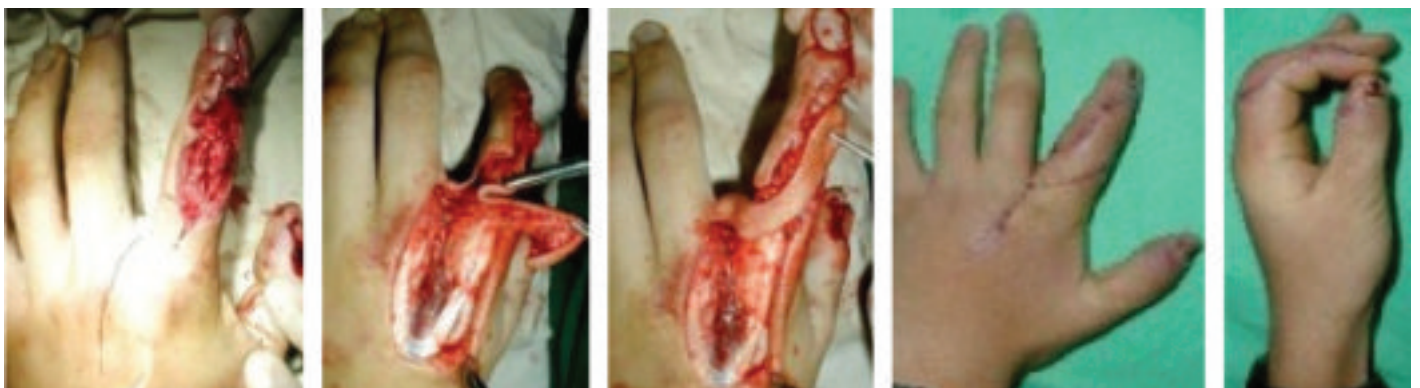

Figure 10 (above): Complex defect of the dorsoradial defect of the index finger: A) Preoperative defect and design of a propeller perforator flap based on perforators from the anastomoses between the dorsal branch of the CDA and the dorsal branch of the PDA; B) The flap is harvested based on the above mentioned perforator. Because the very small caliber of the perforator and in the attempt to avoid the spasm, a small cuff of tissue is preserved around it; C) Rotation of the flap for 180 degrees to cover the defect; D) and E) Postoperative aspect after 2 months.

Figure 11 (right): Schematic representation of a digital artery propeller perforator flap (PDA – proper digital artery).

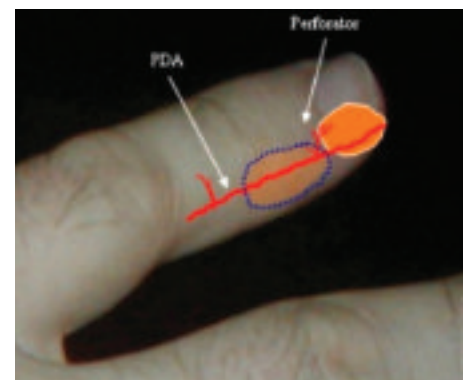

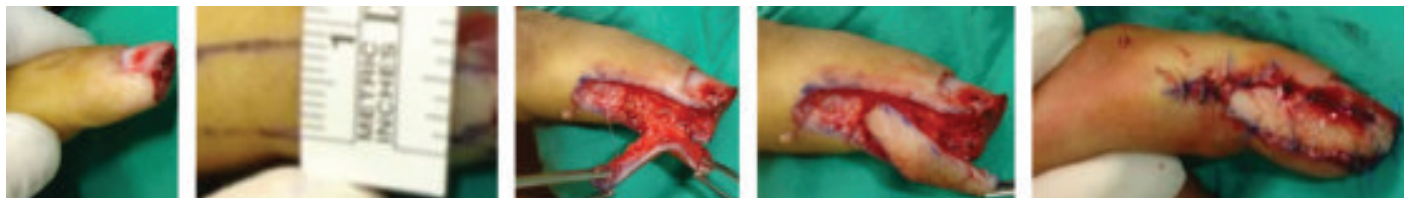


Figure 12 (above): Fingertip amputation: A) Preoperative; B) Design of a propeller flap based on a perforator originating in the PDA. The width of the flap (0.8cm) allows donor site closure by direct suture; C) The harvested flap. A small cuff of tissue is preserved around the perforator; D) Rotation of the flap for 180 degrees; E) Postoperative - donor site closed by direct suture.

Figure 13 (right): Schematic representation of a bi-lobed pedicled perforator flap: 1 - first lobe of the flap, which will be rotated into the defect; 2 - second lobe of the flap, which will be rotated into the remaining defect (PDA - proper digital artery)

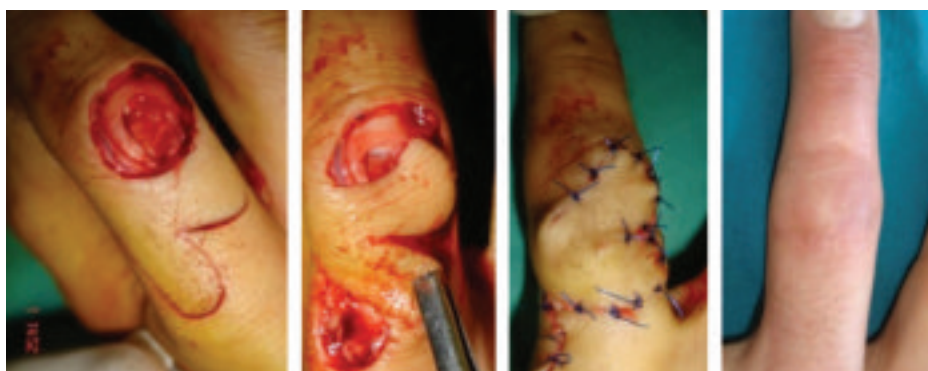
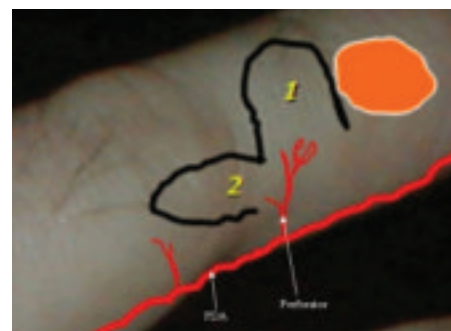
Figure 14 (left): Defect over the dorsal aspect of the proximal interphalangeal joint of the index finger, including skin and extensor tendon: A) Preoperative aspect and design of the bi-lobed flap; B) The bi-lobed flap harvested; the first lobe includes also a small strip harvested from the proximal part of the extensor tendon; C) Immediate postoperative aspect; the donor site of the second flap closed by direct suture; D) Postoperative aspect one year after surgery

To conclude, the presence of numerous perforator vessels supplying the forearm, hand and fingers makes rational and reliable the harvesting of local perforator flaps in order to cover small and medium size defects. The

functional and aesthetic outcome is more than acceptable, but their use needs further research especially regarding the real possible dimensions of these kinds of flaps.

References

1. Taylor GI, Palmer JH. The vascular territories (angiosomes) of the body: Experimental study and clinical applications. *Br J Plast Surg* 1987;40:113-41.
2. Manhot C. The cutaneous arteries of the human body. New York: Springer-Verlag; 1983
3. Salmon M. In: Taylor GI, Tempest M, editors. *Arteries of the skin*. London: Churchill Livingstone; 1988
4. Saint-Cyr M, Wong C, Schaverien M, et al. Perforator theory: Vascular anatomy and clinical implications. *Plast Reconstr Surg* 2009;124:1529-44
5. Rubino C, Coscia V, Cavazzuti AM, et al. Haemodynamic enhancement in perforator flaps: the inversion phenomenon and its clinical significance: A study of the relation of blood velocity and flow between pedicle and perforator vessels in perforator flaps. *J Plast Reconstr Aesthet Surg* 2006;59:636-43
6. Kroll SS, Rosenfield L. Perforator-based flaps for low posterior midline defects. *Plast Reconstr Surg* 1988;81:561-6
7. Koshima I, Soeda S. Inferior epigastric artery skin flap without rectus abdominis muscle. *Br J Plast Surg* 1989;42:645-8
8. Lecours C, Saint-Cyr M, Wong C, et al. Freestyle pedicle perforator flaps:

- Clinical results and vascular anatomy. *Plast Reconstr Surg* 2010;126:1589-603
9. Georgescu AV, Matei I, Ardelean F, et al. Microsurgical nonmicrovascular flaps in forearm and hand reconstruction. *Microsurgery* 2007; 27: 384-94
 10. Matei I, Georgescu AV, Chiroiu B, et al. Harvesting of forearm perforator flaps based on intraoperative vascular exploration: Clinical experiences and literature review. *Microsurgery* 2008;28:321-30
 11. Lee BT, Lin SJ, Bar-Meir ED, et al. Pedicled perforator flaps: A new principle in reconstructive surgery. *Plast Reconstr Surg* 2010; 125:201-8
 12. Chang YT, Wang XF, Zhou ZF, et al. The reversed forearm fasciocutaneous flap in hand reconstruction: 10 successful cases. *Chin J Plast Surg Burns* 1988; 4:41-49
 13. Hyakusoku H, Yamamoto T, Fumiiri M. The propeller flap method. *Br J Plast Surg* 1991;44:53-4
 14. Hallock GG. The propeller flap version of the adductor muscle perforator flap for coverage of ischial or trochanteric pressure sores. *Ann Plast Surg* 2006;56:540-2
 15. Pignatti M, Ogawa R, Hallock GG, et al. The "Tokyo" consensus on propeller flaps. *Plast Reconstr Surg* 2011;127:716-22
 16. McCraw JB, Myers B, Shanklin KD. The value of fluorescein in predicting the viability of arterialized flaps. *Plast Reconstr Surg* 1977;60:710-9
 17. Morykwas MJ, Hills H, Argenta LC. The safety of intravenous fluorescein administration. *Ann Plast Surg* 1991;26:551-3
 18. Eren S, Rubben A, Krein R, et al. Assessment of microcirculation of an axial skin flap using indocyanine green fluorescence angiography. *Plast Reconstr Surg* 1995;96:1636-49
 19. Holm C, Mayr M, Hofter E, et al. Intraoperative evaluation of skin-flap viability using laser-induced fluorescence of indocyanine green. *Br J Plast Surg* 2002;55:635-44
 20. Matsui A, Lee BT, Winer JH, et al. Real-time intraoperative near-infrared fluorescence angiography for perforator identification and flap design. *Plast Reconstr Surg* 2009;123:125e-127e
 21. Kanellakos GW, Yang D, Morris SF. Cutaneous vasculature of the forearm. *Ann Plast Surg* 2003; 50:387-92
 22. Maruyama Y. The reverse dorsal metacarpal flap. *Br J Plast Surg* 1990; 43:24-7
 23. Quaba AA, Davison PM. The distally-based dorsal hand flap. *Br J Plast Surg* 1990; 43:28-39
 24. Koshima I, Urushibara K, Fukuda N, et al. Digital artery perforator flaps for fingertip reconstructions. *Plast Reconstr Surg* 2006; 118: 1579-84
 25. Cormack GC, Lamberty BG. Fasciocutaneous vessels: Their distribution on the trunk and limbs, and their clinical application in tissue transfer. *Anat Clin* 1984; 6:121-31
 26. Saint-Cyr M, Mujadzic M, Wong C, et al. The Radial Artery Pedicle Perforator Flap: Vascular Analysis and Clinical Implications. *Plast Reconstr Surg* 2010; 125:1469-78
 27. Koshima I, Moriguchi T, Etoh H, et al. The radial artery perforator based adipofascial flap for dorsal hand coverage. *Ann Plast Surg* 1995; 35:474-479
 28. Yu P, Chang EI, Selber JC, Hanasono MM. Perforator patterns of the ulnar artery perforator flap. *Plast Reconstr Surg* 2012; 129:213-20
 29. Mathy JA, Moaveni Z, Tan ST. Vascular anatomy of the ulnar artery perforator flap. *Plast Reconstr Surg* 2013; 131:115e-6e
 30. Angrigiani C, Grilli D, Dominikow D, et al. Posterior interosseous reverse forearm flap: experience with 80 consecutive cases. *Plast Reconstr Surg* 1993. 92:285-93
 31. Hubmer MG, Fasching T, Haas F, et al. The posterior interosseous artery in the distal part of the forearm. Is the term "recurrent branch of the anterior interosseous artery" justified? *Br J Plast Surg* 2004; 57:638-44
 32. Mei J, Morris SF, Ji W, et al. An anatomic study of the dorsal forearm perforator flaps. *Surg Radiol Anat* 2013; 35:695-700
 33. Landi A, Luchetti R, Soragni O, et al. The distally based interosseous island flap for the coverage of skin loss of the hand. *Ann Plast Surg* 1991; 27: 527-36
 34. Syed SA, Zahir KS, Zink JR, et al. Distal dorsal forearm flap. *Ann Plast Surg* 1997; 38:396-403
 35. Yousif NJ, Ye Z, Grunert BK, et al. Analysis of the distribution of cutaneous perforators in cutaneous flaps. *Plast Reconstr Surg* 1998; 101:72-84
 36. Schaverien M, Saint-Cyr M. Suprafascial compared with subfascial harvest of the radial forearm flap: an anatomic study. *J Hand Surg (Am)* 2008; 33:97-101
 37. Bailey SH, Andry D, Saint-Cyr M. The dorsal metacarpal artery perforator flap: a case report utilizing a quaba flap harvested from a previously skin-grafted area for dorsal 5th digit coverage. *Hand (NY)*, 2010. 5(3): p. 322-5.
 38. Omokawa S, Tanaka Y, Ryu J, et al. The anatomical basis for reverse first to fifth dorsal metacarpal arterial flaps. *J Hand Surg (Br)* 2005; 30:40-4
 39. Bakhach J, Demiri E, Conde A, et al. Le lambeau métacarpien dorsal à pédicule rétrograde étendu. Etude anatomique et à propos de 22 cas cliniques. *Ann Chir Plast Esthet* 1999; 44:185-193
 40. Koshima I, Urushibara K, Fukuda N, et al. Digital artery perforator flaps for fingertip reconstructions. *Plast Reconstr Surg* 2006; 118: 1579-84

IFSSH Scientific Committee on Arthroscopy

Chair: Francisco del Piñal (Spain)

Committee: Andrea Atzei (Italy), PC Ho (Hong Kong), Christophe Mathoulin (France), Lee Osterman (USA), David Slutsky (USA)

Report submitted March 2014

New Directions in Wrist Arthroscopy

Introduction

Despite the fact that wrist arthroscopy is still in its infancy, progress in the last few years has been enormous. Some surgeons can now perform operative procedures unthinkable just a couple of years ago.

This report seeks not to go against current tides of thought, but intends to spark the minds of the Hand Surgery community to show where the restless arthroscopic minds are heading.

For this report I have asked some of the world leading arthroscopists to present their experience in some pathologies where the use of magnification, good lighting and minimal devascularisation-scarring may change the outcome and prognosis. Needless to say, some of these efforts will be fruitless, whereas others will succeed and become the "standard way"...only time will tell. However, while waiting for this future to unfold, lest you miss the opportunity to be involved in this "future"...my advice is to not let the bandwagon get too far away. Jump on it now!

1. Arthroscopic Dorsal Capsuloligamentous Repair in Chronic Scapholunate Ligament Tears (Prof. Christophe Mathoulin, MD)

The rupture of the scapholunate ligament occurs most often after a fall on an outstretched hand. Arthroscopy is the most valuable tool for the diagnosis and treatment of acute scapholunate dissociation. In chronic lesions treatment options are more controversial. Most forms

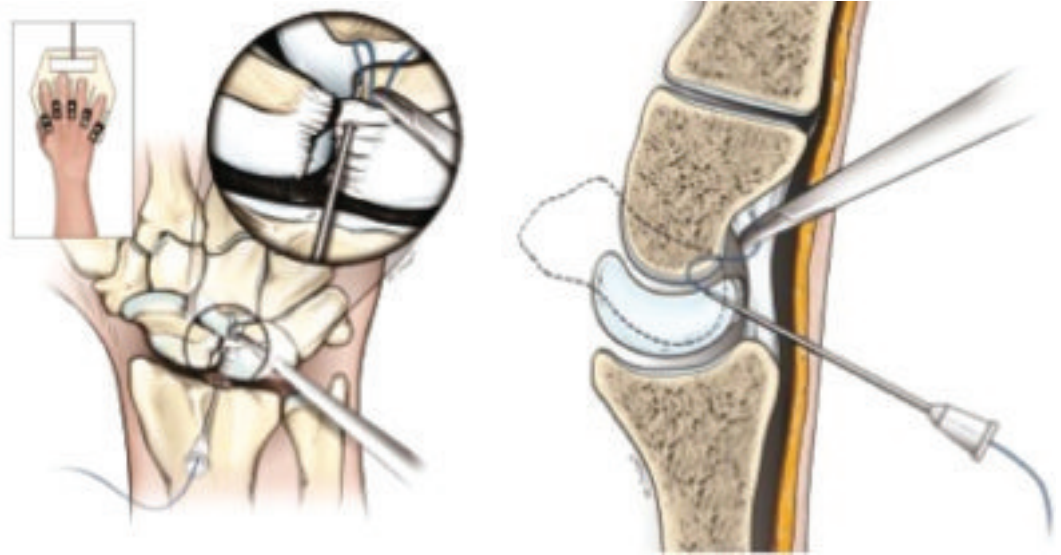
"Despite the fact that wrist arthroscopy is still in its infancy, progress in the last few years has been enormous. Some surgeons can now perform operative procedures unthinkable just a couple of years ago."

of treatment recommended in the literature consist of an open repair or alternative reconstruction techniques which can improve pain and grip strength, but very often lead to stiffness in the wrist joint. We have developed an arthroscopic dorsal capsuloplasty technique to avoid open dissection of the wrist capsule. In cases where the ligament is partially or completely ruptured and where the scaphoid is well-aligned or can be reduced, we propose the new technique of arthroscopic dorsal capsuloplasty which may be combined with K-wire fixation of the scapholunate and the scaphocapitate joints where the scaphoid appears to be mal-aligned.¹

The procedures were performed on an outpatient basis. We used the standard arthroscopic 3-4 and 6R portals for the radiocarpal joint and midcarpal radial [MCR] and midcarpal ulnar [MCU] for the midcarpal joint.

Usually, the scapholunate ligament is detached from the scaphoid and remains attached to the lunate, but on the dorsal aspect, close to the normal insertion of the scapholunate ligament to the capsule, there are remaining parts

Figure 1: Schema representing an AP and lateral view of the passage of the first suture through the dorsal capsule with a remaining dorsal fragment of the scapholunate ligament attached to the dorsal horn of lunate. The passage made from the radiocarpal to midcarpal joint.



of scapholunate ligament on both, the dorsal horn of lunate and the scaphoid.

A needle is inserted under visual control through the 3-4 portal but rather than penetrating the radiocarpal joint it is inserted through the dorsal capsule and used to spear the radial and ulnar remnants of the SL ligament with the needle tips coming out in the midcarpal joint. The scope is then changed to the MCU portal and a 3.0 PDS suture thread is passed through the needles and pulled out through the MCR portal with forceps under visual control from the MCU portal

(Fig. 1). A knot is tied between the two sutures. Following this, proximal traction is applied to both proximal ends of the sutures in order to place the first knot into the mid-carpal joint between the scaphoid and the lunate, volar to the dorsal part of the SL ligament (Fig. 2). A second knot is tied between the two proximal ends and introduced in the 3-4 portal incision, dorsal to the capsule. This knot lies outside the radiocarpal joint on the dorsal capsule. The net effect of this is to achieve a capsule ligamentous repair between the scapholunate

ligament and the dorsal capsule overlying the ligament (Fig. 3).

Our series of 57 patients shows very encouraging preliminary results even with highly demanding patients in a short-term follow-up. Pain relief and recovery of grip strength were observed as with the other techniques. A very low incidence of post-operative wrist stiffness was noted. Post-operative improvement of mean wrist motion was observed in all planes and all professional athletes returned to their pre-injury level of sports training and competition.

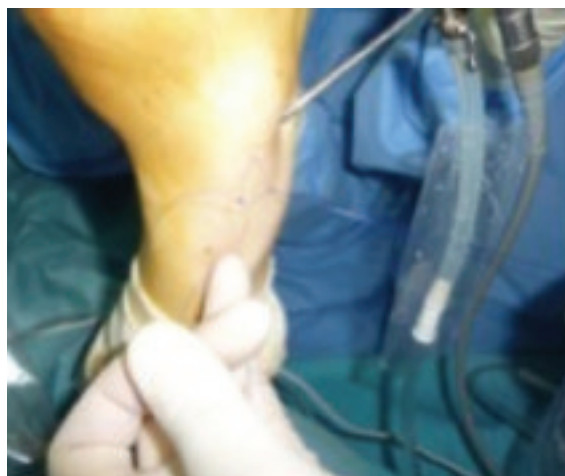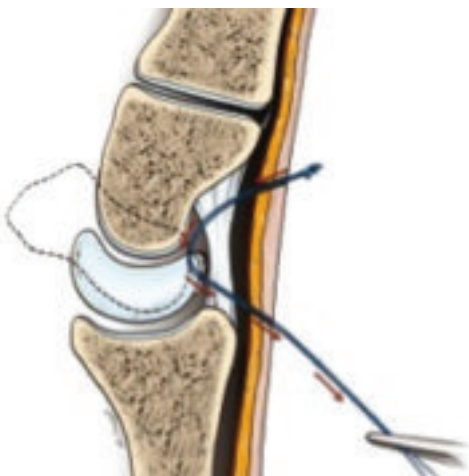


Figure 2: After a first knot is tied between the two sutures, proximal traction is applied to the both proximal ends of the sutures in order to seat the first knot into the midcarpal joint between the scaphoid and the lunate, volar to the dorsal part of SL ligament.

2. Update on Arthroscopic Excision of Wrist Ganglion Cysts (Lee Osterman, MD)

Arthroscopic resection of these common tumours was pioneered by Osterman and Raphael² and has grown in popularity in the last 20 years. The present literature supports arthroscopic excision as a first line treatment for operative treatment of all dorsal, radiocarpal volar, and recurrent ganglion cysts. Kang et al. compared arthroscopic and open dorsal ganglion excision in 72 patients and found no differences in recurrence rate or residual pain between the two treatments at 12 month follow-up³.

Arthroscopic volar wrist ganglion excision was first described in 2003 using standard radiocarpal portals including a 1-2 portal⁴. Rocchi and colleagues prospectively compared treatment of volar wrist ganglion cysts in 50 patients randomised to either open or arthroscopic excision and found comparable complication rates between open and arthroscopic excision of radiocarpal volar ganglion cysts but with a shorter functional recovery in the arthroscopic group⁵.

Arthroscopic excision of wrist ganglion cysts is not without complications. Recent reports place the risk of recurrence at 0-12% and complications at 0-6%, including multiple extensor tendon lacerations.^{4,6-8} A higher complication rate has been associated with arthroscopic excision of midcarpal volar ganglion cysts including recurrence rate but data is limited⁵. Despite the risk of recurrence with all techniques, revision excision has shown to be effective arthroscopically. Shih et al.⁹ treated 32 patients with arthroscopic dorsal ganglion excision, 5 of which had recurrent cysts after open excision, and found results comparable to open excision. Similarly Edwards and Johansen¹⁰ prospectively followed 55 dorsal wrist ganglion cysts after arthroscopic excision, 10 of which were recurrent cysts, and found significant improvements in clinical outcomes at 6 weeks, 6 months and 2 years with no recurrences in all patients.

Arthroscopic excision of wrist ganglion cysts is an important treatment option for this common diagnosis. Future directions for scientific investigation include the

safety and effectiveness of arthroscopy in the treatment of midcarpal volar ganglion cysts.

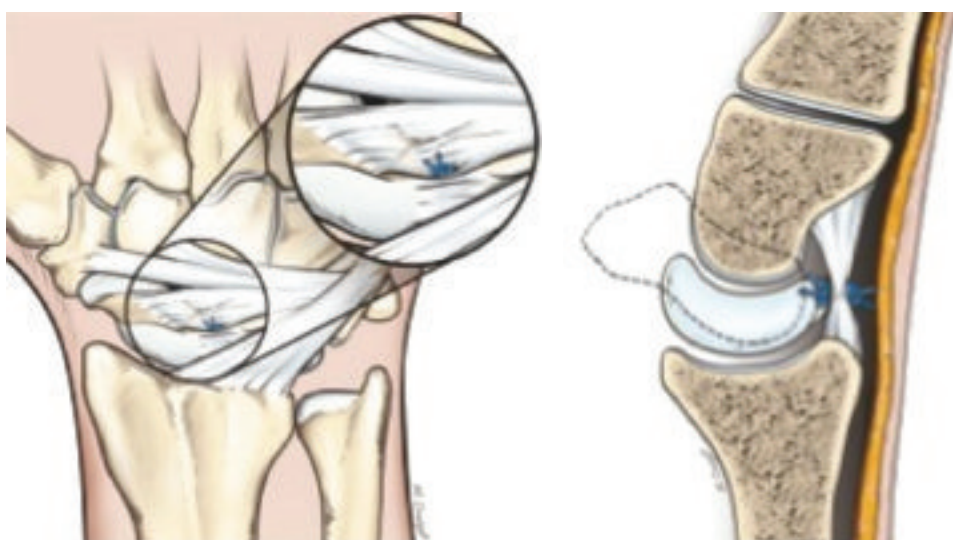
3. Arthroscopic Bone Grafting in Scaphoid Nonunion (Pc Ho, MD)

The entire intra-articular location of scaphoid nonunion allows an arthroscopic approach for both evaluation and therapeutic intervention with maximal preservation of blood supply and ligamentous architecture and hence favours union and functional restoration. We present the technique developed in our centre since April 1997 and discuss the long-term outcomes and indications¹¹.

Fifty-six established symptomatic nonunion and 12 delayed union cases were operated between April 1997 and November 2009. There were 64 male and 4 female, with an average age of 27.5 (ranged 14-53). The median duration of symptoms was 8 months (ranged 1- 276 months). Radiologically, there were 10 distal third, 30 mid-third and 28 proximal third fractures. Twenty cases had DISI deformity.

Evaluation started at the radiocarpal

Figure 3: Schema representing an AP and lateral view of the second knot tied between the two proximal ends and introduced in the 3-4 portal incision, dorsal to the capsule. This knot lies outside the wrist joint on the dorsal capsule. The net effect of this produces a capsuloplasty between the scapholunate ligament and the dorsal capsule overlying the ligament.



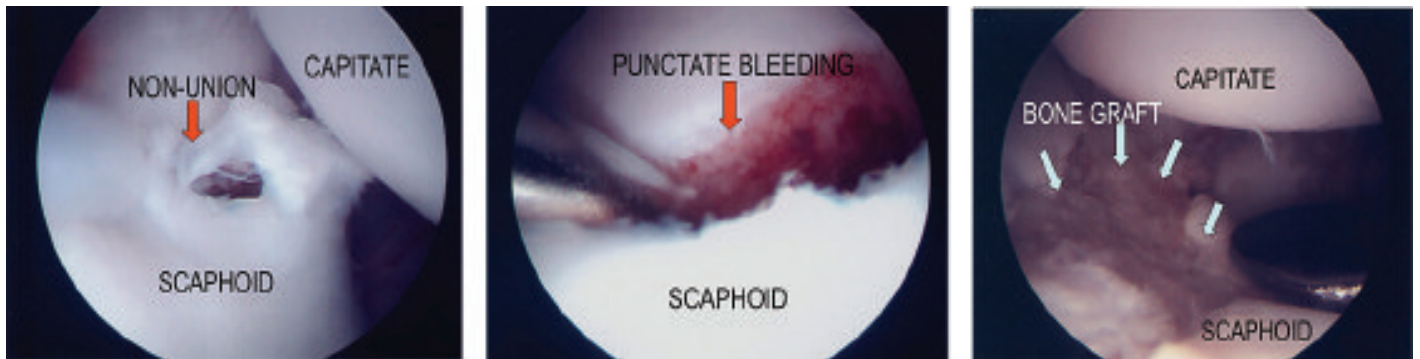


Fig 4 (left): Nonunion site located by the disruption of articular cartilage and fibrous tissue interposition.

Fig. 5 (centre): Both ends of nonunion site burred till healthy looking cancellous bone with punctate bleeding is seen.

Fig. 6 (right): The bone graft has been delivered to the nonunion site through an arthroscopic cannula and impacted. A small depressor is employed to mould the graft into contour of the articular surface of the scaphoid.

joint arthroscopy to check for any SNAC wrist changes and concomitant ligament lesions. Stage 1 SNAC wrist could be managed by arthroscopic radial styloidectomy. The standard repair procedure included a take-down of the nonunion site at the midcarpal joint with motorised burr till healthy cancellous bone was encountered (Fig. 4). Tourniquet was not inflated so that vascularity of both fragments could be appreciated critically (Fig. 5). DISI deformity could be corrected by closed Linscheid manoeuvre under fluoroscopic guidance. The fracture was then transfixed with a single K wire inserted percutaneously at the scaphoid tubercle. Cancellous chip graft harvested from the iliac crest was delivered and densely packed into the fracture site through 4mm arthroscopic cannula. We considered bone graft from distal radius as inadequate. Fibrin glue was injected at the end to stabilise the bone graft and to protect the articular surface (Fig. 6). Fixation was completed either by inserting 2 additional K wires (42 cases) or with cannulated screw (26

cases). Wounds were apposed with steri-strips. Early active mobilisation was initiated two weeks after the procedure. Buried K wires were removed under local anaesthesia when union was evidenced.

At final follow up, all patients were evaluated radiologically on union status, carpal alignment, arthritic changes and clinically with regard to pain, motion, grip power and complications.

The average follow up was 39.5 months (range 5-125 months). Overall union rate was 92.7% (63/68). The average radiological union time was 12 weeks (6-39 weeks). While good bleeding from the proximal scaphoid fragment predicted union in 40 out of 42 cases (95.2%), unsatisfactory bleeding still permitted union in 16 out of 19 cases (84.2%) Complications were few. There was no pain in 53 patients while the average pain score according to a visual analog scale in the remaining was 1.8. There was significant improvement in ADL performance score, ADL pain score, exertion pain and grip power ($p < 0.05$). The average

scapholunate angle was 62.3° and AP intra-scaphoid angle was 34.5° .

With minimal surgical insult to the blood supply of the carpal bones and their ligamentous connections, arthroscopic bone graft provides a more favourable biological environment for the nonunion to repair with a shorter time of rehabilitation. A high union rate is uniform at 92.7% and the clinical outcome is satisfactory. Avascular necrosis is not a contraindication as a union rate of 84.2% can be expected and compares favourably to other techniques. DISI and humpback deformity can be corrected and tackled. Therefore arthroscopic bone grafting represents a significant breakthrough in arthroscopic surgery of the wrist.

4. Arthroscopic Assisted Fixation of Distal Radius Fractures and Malunions (David J. Slutsky, MD)

Doi and coworkers¹² performed a prospective study comparing 34 intra-articular distal radius fractures treated with arthroscopic reduction,

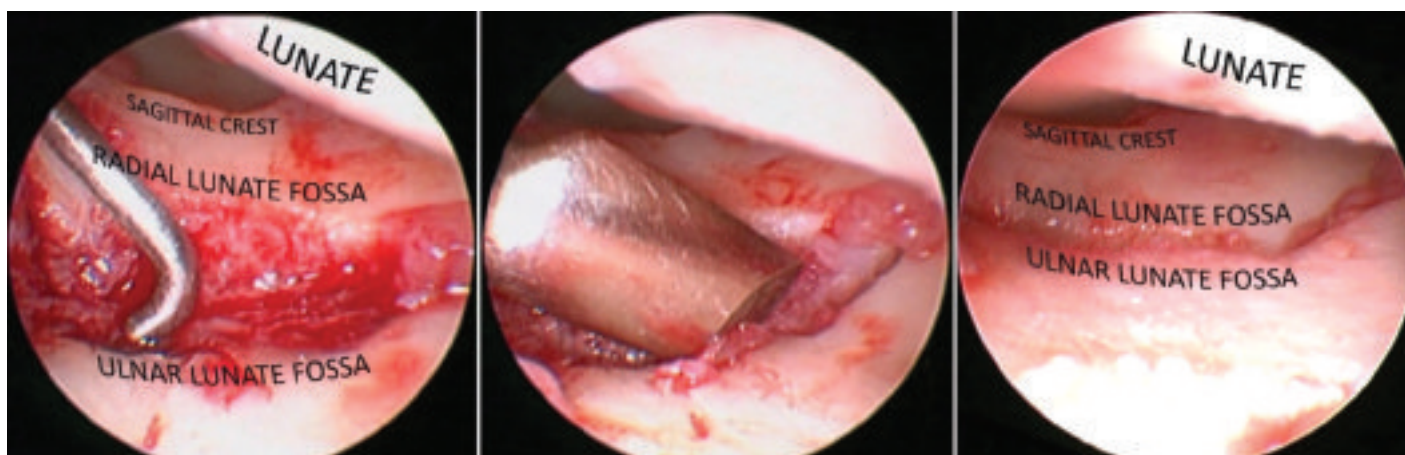

Fig. 7: *Left - Correction of a 4 mm step-off on the lunate fossa (right wrist scope in 6R).
Centre - The osteotome (entering the joint through a dorsal portal) is separating the malunited fragments.
Right - Corresponding view after reduction. (© Dr Piñal, 2010).*

pinning (ARIF) and external fixation vs. 48 fractures treated with open plate fixation (ORIF) or with pinning \pm external fixation. At an average follow-up of 31 months, the ARIF group had significantly better ranges of flexion-extension, radial-ulnar deviation and grip strength ($p < 0.05$). Radiographically, the ARIF group had better reduction of volar tilt, ulnar variance, and articular gap reduction. Ruch et al.¹³ compared the functional and radiologic outcomes of arthroscopically assisted (AA) percutaneous pinning and external fixation versus fluoroscopically assisted (FA) pinning and external fixation of 30 patients with comminuted intra-articular distal radius fractures. Patients who underwent AA surgery had significantly improved supination compared with those who underwent FA surgery (88° vs 73°) AA reduction also resulted in improved wrist extension (77° vs 69°) and wrist flexion (78° s. 59°). Varitidimis et al performed a randomised prospective study comparing 20 patients with

intra-articular fractures of the distal radius who underwent AA and FA reduction and external fixation plus percutaneous pinning vs 20 patients with the same fracture characteristics

"The entire intra-articular location of scaphoid nonunion allows an arthroscopic approach for both evaluation and therapeutic intervention with maximal preservation of blood supply and ligamentous architecture and hence favours union and functional restoration."

who underwent FA reduction alone and external fixation plus percutaneous pinning¹⁴. At 24 months the patients who underwent AA and FA treatment had significantly better supination, extension and flexion though the mean DASH scores were similar for both groups.

The AAOS clinical guidelines on Distal Radius Fractures considers the use of the arthroscope in distal radius fractures, as yet, has only weak evidence to support its use.

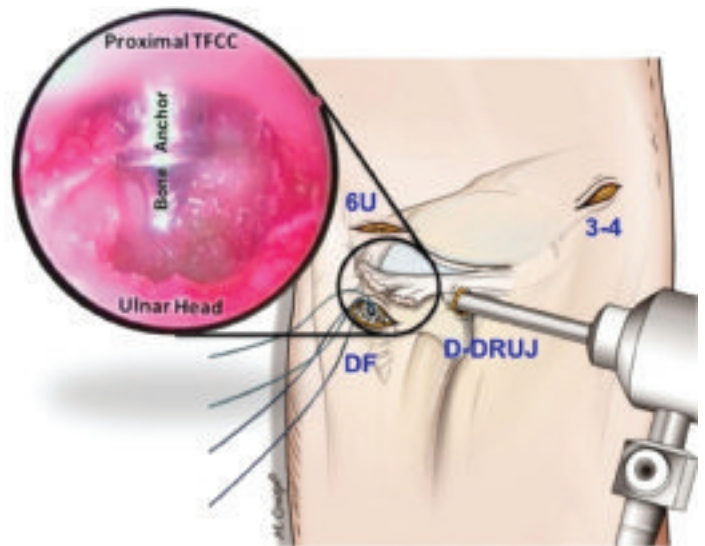
Malunion of the radius articular surface can be also approached under arthroscopic guidance. The main benefit is the feasibility of performing the cut through the original fracture line with minimal devascularisation and scarring (Fig. 7). Good results have been reported in a small cohort of patients (15). Under certain circumstances some patients may benefit from minimal intervention by smoothing out irregularities under arthroscopic guidance with promising results¹⁶

5. TFCC Reconstruction and Reinsertion (Andrea Atzei, MD)

Since the early 90's, wrist arthroscopy has been considered the gold standard for the diagnosis of TFCC peripheral tears and it has been proven to be beneficial to repair edges of the tear to the dorsoulnar wrist capsule or ECU tendon sheath. However, it was generally agreed that arthroscopic treatment was not appropriate when a TFCC peripheral tear was associated with DRUJ instability and/or when the TFCC was not repairable. Thus, these conditions were usually treated by open surgery. Refinements in arthroscopic diagnosis and surgical technique have permitted us to overcome these limitations and perform an "all-arthroscopic" treatment of the TFCC peripheral tear even when associated with DRUJ instability.

Diagnostic accuracy of TFCC tears has improved dramatically with the introduction of the Hook Test (or TFCC pulling test). The test consists of using the probe to pull the ulnar-most border of the TFCC towards the

Fig. 8. Foveal refixation of proximal TFCC avulsion. With the scope in D-DRUJ portal, the suture screw is inserted into the fovea through the DF portal.



centre of the radiocarpal joint, in order to confirm foveal disruption of the TFCC. The high reliability of the hook test has reduced the need for DRUJ arthroscopy for direct visualisation of the proximal TFCC rupture or avulsion. The combination of arthroscopic and clinical findings allows a more detailed classification of TFCC peripheral tears that serves also as a treatment-oriented algorithm¹⁷. Isolated distal TFCC tear (Class 1) is repaired by simple ligament-to-capsule suture,

since the foveal origins of the TFCC are intact. Complete, repairable TFCC tears (Class 2) and isolated foveal, repairable tears (Class 3) are associated with DRUJ instability and require reinsertion of the TFCC onto the ulnar head. Irreparable foveal disruption (Class 4) requires TFCC reconstruction by tendon graft. Presence of DRUJ arthritis defines Class 5 TFCC tears, which should be treated by DRUJ arthroplasty, and presence of the different types of styloid fractures allows further sub-classification¹⁸. Arthroscopic repair of foveal avulsions has become possible with technical refinements of DRUJ arthroscopy and the use of the DF (Direct Foveal) portal. Through the DF portal, eventually enlarged to a limited open approach, it is possible to debride the proximal TFCC, refresh and drill the fovea ulnaris in order to introduce a four-strand bone anchor/screw (Fig. 8). Arthroscopic view allows precise positioning of one suture (two strands) through the palmar DRUJ ligament and the other suture for the dorsal DRUJ ligament. In a series of 18

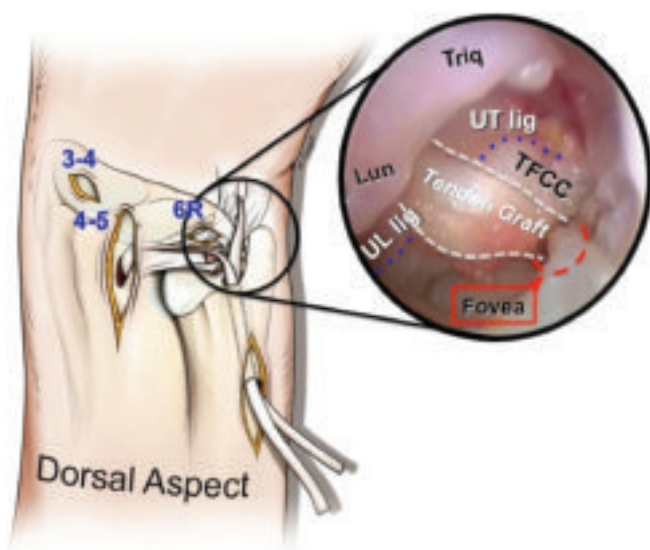


Fig. 9. Arthroscopic reconstruction of irreparable TFCC tear. The palmar limb of the tendon graft is to introduced between the ulnolunate and ulnotriquetral ligaments, just distal to the TFCC, then enters the foveal tunnel.

patients with a minimum follow-up of 1 year, the Modified Mayo Wrist score was excellent in 14 patients, good in 3 and fair in 1. The DASH score showed 94.4% excellent and good results ¹⁹.

Arthroscopic Reconstruction of DRUJ ligaments using a tendon graft has also achieved a widespread acceptance and use. The arthroscopic technique ²⁰ is a modification of the open procedure originally described by Michel Mansat and popularised by Bryan D Adams. The advantages of the new technique are not only related to the limited skin incisions (with consequent reduced pain and scar and faster postoperative rehabilitation), but also to the possibility of performing a more anatomic reconstruction of the TFCC, including retensioning of the ulnocarpal ligaments. Under arthroscopic guidance it is possible to introduce the graft through a small opening between the ulnocarpal ligaments, just distal to the palmar DRUJ ligament, to improve stability of the palmar side of the TFCC (Fig. 9). This technique was used in 11 patients and showed excellent to good results according to the Modified Mayo Wrist Score and DASH score in all patients ²⁰.

6. Arthroscopic Arthrodesis (F Del Piñal)

The feasibility of performing intercarpal or radiocarpal arthrodesis arthroscopically was presented by Ho in a pioneering work ²¹. It may be considered by the sceptical as just another arthroscopic filigree. However, the procedure is sound, not only because there will be a cosmetic benefit, but above all, in my view, because the degree of insult to the ligaments will be minimised. Ligament

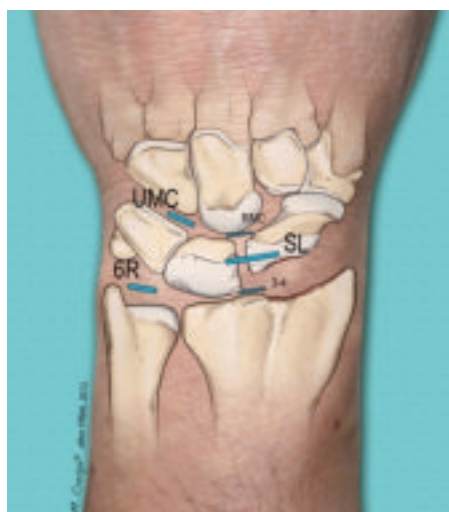

Figure 10: The SL portal is located midway between the 3-4 and radial midcarpal portals. (Key: SL: scapholunate portal, RMC: radial midcarpal; UMC: ulnar midcarpal) (ref 23).

preservation will keep the blood supply to the bones intact and with less scarring to the capsule. This, in turn, promotes bony healing and less stiffness respectively. Furthermore, the proprioception of the wrist will be undisturbed providing (in theory) some extra protection to the joint.

However, performing this procedure with classic “wet” arthroscopy has the disadvantages of a long operating time (more than 3 hours), massive swelling, and difficulty with bone graft placement ²¹. Implementation of the technique was difficult, yet the advantages were undisputed. We have endorsed the dry arthroscopy technique (arthroscopy without infusing saline) ²². It is particularly useful in complex operations such as distal radius fixations and in any semi-

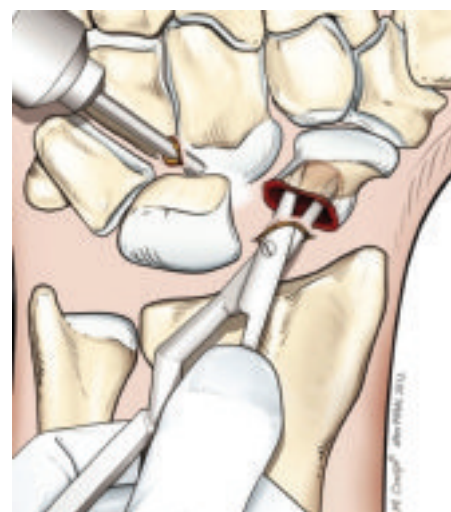


Fig. 11 (right): The process of scaphoid resection with a rongeur. With the scope in UMC the surgeon scoops out the middle third of the scaphoid with the rongeur. (ref 23).

open operation such as four corner arthrodesis. With this technique, most of the difficulties mentioned for the wet A-4CA as described by Ho ²¹ are circumvented, and the operation can be carried out in a competitive time: less than one tourniquet time ²³. The critical steps of the operation can be summarised as follows: 1) A larger SL portal (Fig. 10) allows for introduction of pituitary rongeurs to remove in an expeditious way the scaphoid (Fig. 11). Moreover, with the rongeur technique, the cancellous bone is preserved for bone graft. 2) When inserting cancellous bone graft, it is placed at the arthrodesis site and does not migrate with the infusion fluid throughout the rest of the wrist. Furthermore, the use of a large bore drill guide allows quick and easy placement of the bone graft in the

midcarpal space. 3) Fixation is by using a triangular construct with cannulated screws (Fig. 12). Without the infusion of fluid, distortion of bony landmarks does not occur and the surgeon can feel the bony landmarks, making this critical step of placement of the guidewires and cannulated screws, much easier. After the operation immobilisation for 3-4 weeks is recommended.

Our experience is limited to 16 cases of four corner arthrodesis and several others of different fusions (mainly radioscapholunate arthrodesis). We have been very satisfied with the early results, and only have had problems with union in one case where immediate range of motion was permitted.

Remarks and Conclusions

The aim of this report is not to claim that results are any better than with the open approach but that arthroscopy assisted procedures are conceptually appealing and feasible in a competitive time. Most of the procedures discussed in this report rank among the most difficult operations one can perform arthroscopically, and some of them have a steep learning curve even for

skilled arthroscopists. Nevertheless, the possibility of performing complex procedures through minimally invasive surgery represents the future of wrist surgery and the direction in which we should head.

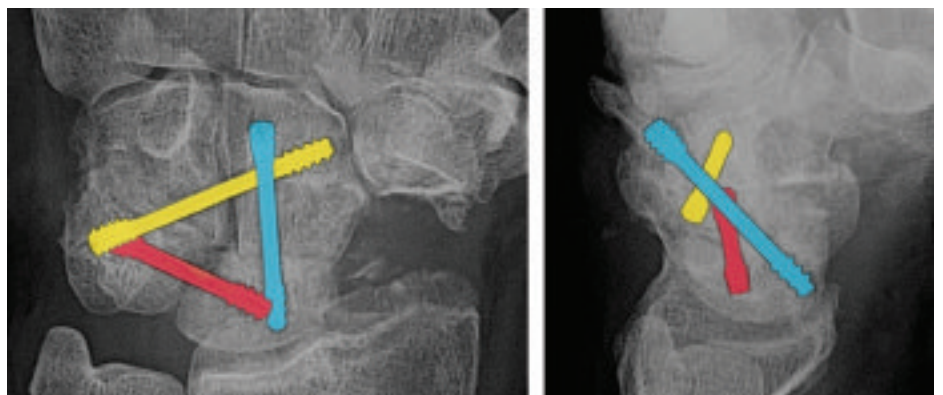
It is of justice to stress that there are many more surgeons doing stunning work that have been left out of this report due to space limitations, but whose quality would have deserved their presence here. I have to highlight some of the investigation lines that without a doubt will have an impact on the future: Park et al.^{24,25} are presenting outstanding results in the management of complex carpal injuries. Also a word is needed to emphasise the work of Badia^{26,27} in the development of techniques for the trapeziometacarpal joint, and Cobb and others²⁸ in the expansion to small joint arthroscopy. Finally, some groups are working now under local anaesthesia, minimising expenses and morbidity²⁹.

Although the future is already here in many respects, beyond doubt there will be much more to come. I foresee an enormous expansion by the combination of arthroscopy and mini-open approaches³⁰ benefiting from both the accuracy of direct vision

with magnification and the minimal scarring. To make this combination smooth and easy, in my view we should master the dry technique, as this avoids the problem of swelling and constant loss of vision due to water escaping through the large portals²². But no doubt each surgeon can master different ways of doing things and achieve similar results.

In conclusion, arthroscopy is allowing us to perform complicated surgery without the need to create scarring by our surgical approaches. The forefront techniques that have been discussed here are based on the work of others. We stand in the shoulders of giants: Whipple, Poehling, Geissler, Luchetti, Nakamura, all the contributors of this report and so many others surgeons that I have not mentioned. Without their dedication and hard work, wrist arthroscopy would not be where it is today. This report is dedicated to all of them.

Fig. 12: Ideal position of the screws to avoid collision and provide maximal purchase. (ref 23).



References

- Mathoulin CL. From scapholunate interosseus ligament to scapholunate ligament complex. *J Wrist Surg.* 2013 May;2(2):98.
- Osterman AL, Raphael J. Arthroscopic resection of dorsal ganglion of the wrist. *Hand Clin.* 1995 Feb;11(1):7-12.
- Kang L, Akelman E, Weiss AP. Arthroscopic versus open dorsal ganglion excision: a prospective, randomised comparison of rates of recurrence and of residual pain. *J Hand Surg Am.* 2008;33(4):471-5.
- Ho PC, Lo WN, Hung LK. Arthroscopic resection of volar ganglion of the wrist: A new technique. *Arthroscopy.* 2003;19(2):218-21.
- Rocchi L, Canal A, Fanfani F, Catalano F. Articular ganglia of the volar aspect of the wrist: arthroscopic resection compared with open excision. A prospective randomised study. *Scand J Plast Reconstr Surg Hand Surg.* 2008;42(5):253-9.
- Gallego S, Mathoulin C. Arthroscopic resection of dorsal wrist ganglia: 114 cases with minimum follow-up of 2 years. *Arthroscopy.* 2010 Dec;26(12):1675-82.
- Kim JP, Seo JB, Park HG, Park YH. Arthroscopic excision of dorsal wrist ganglion: factors related to recurrence and postoperative residual pain. *Arthroscopy.* 2013;29(6):1019-24.
- Cooper AR, Elfar JC. Extensor tendon lacerations from arthroscopic excision of dorsal wrist ganglion: case report. *J Hand Surg Am.* 2013;38(10):1957-9.
- Shih JT, Hung ST, Lee HM, Tan CM. Dorsal ganglion of the wrist: results of treatment by arthroscopic resection. *Hand Surg.* 2002 Jul;7(1):1-5.
- Edwards SG, Johansen JA. Prospective outcomes and associations of wrist ganglion cysts resected arthroscopically. *J Hand Surg Am.* 2009;34(3):395-400.
- Wong WY, Ho PC. Minimal invasive management of scaphoid fractures: from fresh to nonunion. *Hand Clin.* 2011;27(3):291-307.
- Doi K, Hattori Y, Otsuka K, Abe Y, Yamamoto H. Intra-articular fractures of the distal aspect of the radius: arthroscopically assisted reduction compared with open reduction and internal fixation. *J Bone Joint Surg Am* 1999; 81:1093-1110
- Ruch DS, Vallee J, Poehling GG, Smith BP, Kuzma GR. Arthroscopic reduction versus fluoroscopic reduction in the management of intra-articular distal radius fractures. *Arthroscopy* 2004; 20:225-230.
- Varitimidis SE, Basdekis GK, Dailiana ZH, Hantes ME, Bargiotas K, Malizos K. Treatment of intra-articular fractures of the distal radius: fluoroscopic or arthroscopic reduction?, *J Bone Joint Surg Br* 2008; 90:778-785
- del Piñal F, Cagigal L, García-Bernal FJ, Studer A, Regalado J, Thams C. Arthroscopically guided osteotomy for management of intra-articular distal radius malunions. *J Hand Surg Am.* 2010;35(3):392-7.
- del Piñal F, Klausmeyer M, Thams C, Moraleda E, Galindo C. Arthroscopic resection arthroplasty for malunited intra-articular distal radius fractures. *J Hand Surg Am.* 2012;37(12):2447-55.
- Atzei A. New trends in arthroscopic management of type 1-B TFCC injuries with DRUJ instability. *J Hand Surg [Eur]* 2009;34E: 5: 582-591
- Atzei A, Luchetti R. Foveal TFCC Tear Classification and Treatment. *Hand Clin* 2011; 263-272
- Atzei A, Rizzo A, Luchetti R, Fairplay T. Arthroscopic Foveal Repair of Triangular Fibrocartilage Complex Peripheral Lesion With Distal Radioulnar Joint Instability. *Tech Hand Upper Extrem Surg* 2008;12: 226-235.
- Atzei A. DRUJ Instability: Arthroscopic ligament reconstruction. In F del Piñal (Ed), Ch Mathoulin T Nakamura (CoEds): *Arthroscopic management of Ulnar pain.* Springer-Verlag Heidelberg. 147-160, 2012.
- Ho PC. Arthroscopic partial wrist fusion. *Tech Hand Up Extrem Surg.* 2008;12:242-65.
- del Piñal F. Dry arthroscopy and its applications. *Hand Clin.* 2011;27(3):335-45.
- del Piñal F, Klausmeyer M, Thams C, Moraleda E, Galindo C. Early experience with (dry) arthroscopic 4-corner arthrodesis: from a 4-hour operation to a tourniquet time. *J Hand Surg Am.* 2012;37(11):2389-99.
- Park MJ, Ahn JH. Arthroscopically assisted reduction and percutaneous fixation of dorsal perilunate dislocations and fracture-dislocations. *Arthroscopy.* 2005;21(9):1153.e1-e8.
- Kim JP, Lee JS, Park MJ. Arthroscopic reduction and percutaneous fixation of perilunate dislocations and fracture-dislocations. *Arthroscopy.* 2012;28(2):196-203.
- Badia A. Trapeziometacarpal arthroscopy: a classification and treatment algorithm. *Hand Clin.* 2006 May;22(2):153-63.
- Badia A. Arthroscopy of the trapeziometacarpal and metacarpophalangeal joints. *J Hand Surg Am.* 2007;32(5):707-24.
- Cobb TK, Berner SH, Badia A. New frontiers in hand arthroscopy. *Hand Clin.* 2011;27(3):383-94.
- Ong MT, Ho PC, Wong CW, Cheng SH, Tse WL. Wrist Arthroscopy under Portal Site Local Anesthesia (PSLA) without Tourniquet. *J Wrist Surg.* 2012 Nov;1(2):149-52.
- Corella F, Del Cerro M, Ocampos M, Larrainzar-Garijo R. Arthroscopic ligamentoplasty of the dorsal and volar portions of the scapholunate ligament. *J Hand Surg Am.* 2013;38(12):2466-77.

Active re-direction instead of passive motion for joint stiffness

Judy C. Colditz, OT/L, CHT, FAOTA

NOTE: *This article is being published simultaneously in the ASHT Times and the IFSSH E-zine by permission of the author.*

We use the word 'stiff' (which means 'difficult to bend; rigid') to describe hand joints which lack motion and provide resistance to movement. The soft tissue structures in the hand do not harden like concrete to become inherently stiff, but rather undergo a change in their physical properties preventing them from moving relative to one another.

Injury/Stress Deprivation

There are two ways joints become stiff. First, the healing process following trauma develops new collagen which is relatively disorganised and thus resistant to movement. Second, uninjured, immobilised joints undergo stress deprivation, triggering excessive collagen cross-linking. For example, the tissue layers in the dorsal apparatus of the normal finger glide laterally and distally during finger flexion and

extension¹ while the PIP joint capsular structures also move relative to one another (Figure 1). Following trauma to the PIP joint or lack of PIP joint movement, the absence of essential stress creates a lack of differential glide of these structures which is perceived as stiffness. The application of controlled stress (motion) across stiff joints both aligns new collagen fibres to decrease resistance and maintains lubrication within the collagen cell matrix to prevent abnormal cross-linking.

Therapists often apply a mobilisation orthosis to a stiff joint intermittently with the intention of applying "low-load prolonged stress" to alter tissue,²⁻⁴ but the intermittent application defies the definition of "prolonged." What is needed is deformation of the soft tissue by frequent repeated stress application instead of the short-lived visco-elastic response ("stretched" collagen returns to original length & shape). It is the visco-elastic behaviour of human tissue that dooms passive stretching to limited use in managing joint stiffness⁵ because change

results only from prolonged, repeated appropriate stress application.

Stiff Joints Create Brain Changes

During joint immobilisation and/or limited joint motion, the brain changes the motor representation in response to the altered movement. Multiple studies have shown that motor areas used enlarge and those unused lose cortical representation.⁶⁻⁹ An example is a patient who has sustained a distal radius fracture. During wrist immobilisation, finger flexion may be initiated with metacarpophalangeal (MP) joint flexion rather than interphalangeal joint flexion. When the wrist immobilisation is removed, the motor cortex has re-defined the beginning of finger flexion as starting with MP joint flexion (Figure 2). To alter this brain change resulting from muscle imbalance, the muscles unemployed while the wrist was immobilised must be activated repeatedly over time to reestablish their proportional cortical representation. This cannot be accomplished with passive motion.

Determining Appropriate Treatment Approach

Therapists often describe joint motion as having a “soft-end feel” or a “hard-end feel.” Joints with a soft-end feel describe collagen with minimal cross-linking and the presence of oedema (the softness at end range). A joint with a hard-end feel identifies tissue with significant collagen crosslinking, preventing differential tissue glide and providing a defined end point to passive motion.

A soft-end feel joint is responsive to gentle stress at this stage of early collagen cross-linking. Intermittent stress is usually effective if followed by active motion. Passive range of motion (PROM) is appropriate but must be defined as a gentle, slow, sustained stretch that never results in pain or increased inflammatory response. Balanced active motion can easily be restored because re-patterning of the motor cortex has not yet occurred; only encouragement is needed to change the tissue.

When a joint has a hard-end feel the intuitive response is to

“Passive range of motion is not necessary to mobilise stiff joints if cyclical active motion is repeated frequently and the patient cannot revert to the previous imbalanced pattern of motion.”

push the stiff joint to apply enough stress to re-create joint movement; traditional treatment assumes PROM is necessary to regain active range of motion. Ironically, the stiffer the joint, the less passive range of motion is effective because it is short-lived and

intermittent. Several studies suggest that short-term passive range of motion may initially have a positive effect but proof of a long-term positive effect is absent and there is suggestion of a negative response to intermittent PROM in the presence of joint stiffness.

10-12

There is no cortical input to change the pattern of active motion when wearing an orthosis. If active motion of the stiff joint is not part of the treatment, how can the patient re-learn the desired motion? An example is traditional treatment of a stiff proximal interphalangeal (PIP) joint. An orthosis provides a passive force for increased passive PIP joint extension but also imposes periods of relative immobilisation and constriction (Figure 3). Between sessions of orthotic use, the patient reverts to hyperflexion and/or hyperextension of the less stiff MP joint instead of full movement of the stiffer PIP joint (Figure 4). This explains why we are so frequently frustrated with the inability to actively maintain PIP joint extension gained passively.

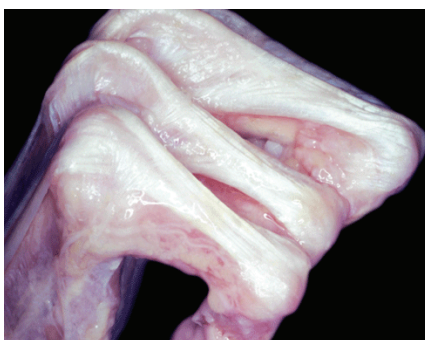

Figure 1. The various tissue layers of the dorsal apparatus of the finger move relative to one another to allow interphalangeal joint flexion.

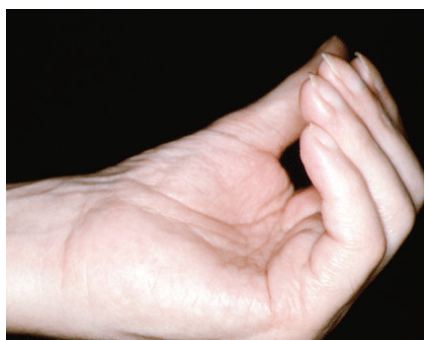

Figure 2. Following immobilisation for a distal radius fracture, this patient initiates finger flexion with the metacarpophalangeal joints rather than the interphalangeal joints.

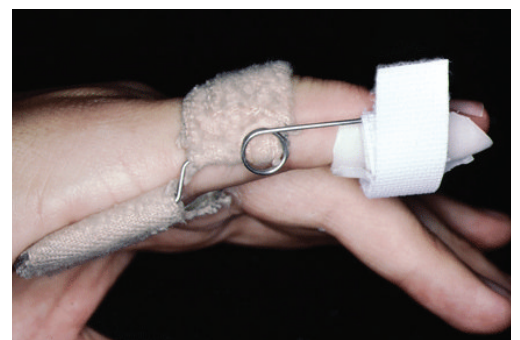
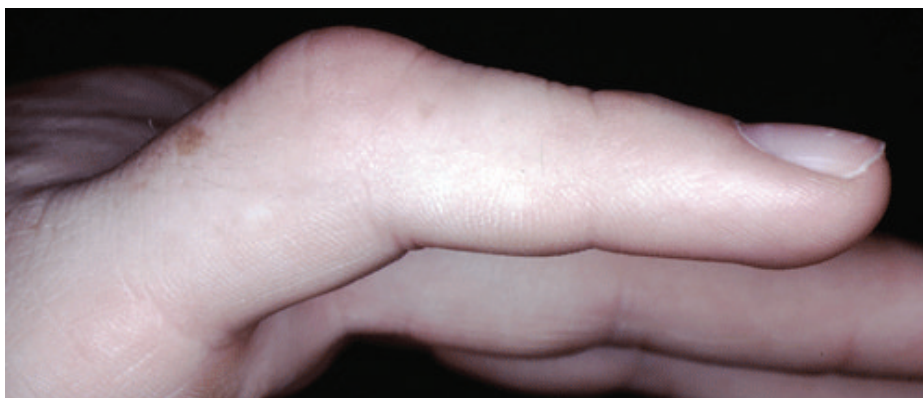

Figure 3. A dynamic PIP joint extension orthosis imposes immobilisation and constriction while passively extending the PIP joint.

Figure 4. Following removal of a dynamic PIP extension orthosis, the patient continues to hyperextend the MP joint instead of the PIP joint.



Active Redirection

I have created a term called "Active Redirection", describing the simple concept of blocking normal joints so stiff joints receive the muscle power needed to move them. Clinical observation proves that PIP joint contractures of the ring and little fingers resulting from ulnar palsy claw deformity regain full PIP joint extension when the MP joint is blocked from full extension. The difference between blocking exercises and active redirection is duration.

Active redirection is accomplished during waking hours when movement is volitional and replaces any and all passive range of motion. This can be applied as a blocking orthosis worn during waking hours (Figure 5.1-5.3) or, if the stiffness is severe, as a non-

removable cast worn full time until rebalance of motion is achieved^{13,14} (Figure 6). Passive range of motion is not necessary to mobilise stiff joints if cyclical active motion is repeated frequently and the patient cannot revert to the previous imbalanced pattern of motion. Active redirection when MP joint hypertension is blocked and the stiff PIP joint moves actively into full extension throughout the day simultaneously accomplishes differential glide of tissues planes, reduction of digital oedema, and motor cortex remapping.

The Future

In the future I envision new tools to assist us in mobilising stiff joints. Scientists have recently developed wearable, stretchable, multifunctional

"Regardless of the new tools we may use, I hope we will shift our focus from passive range of motion to redirected active motion, providing the ideal dosage of both mechanical and cortical stress."

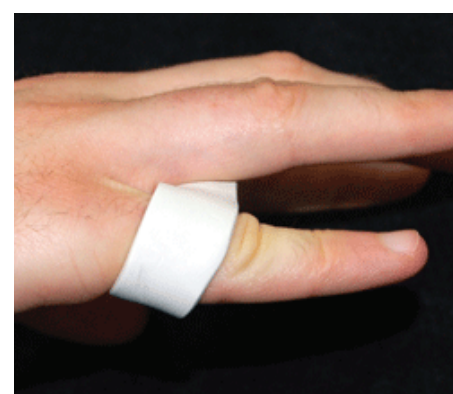
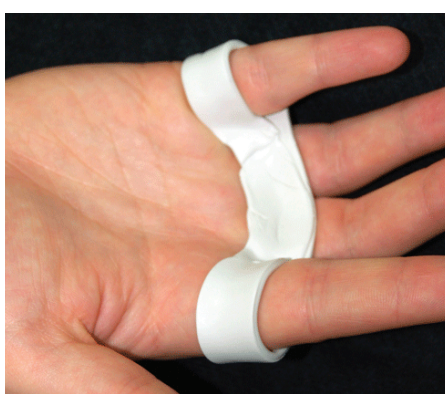
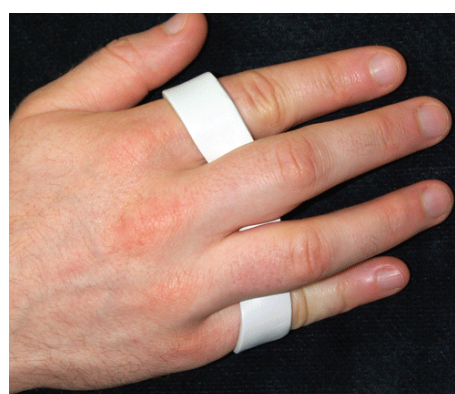Figure 5.1-5.3. A small custom moulded orthosis blocks MP joint extension to drive the extension force to the stiffer PIP joint.

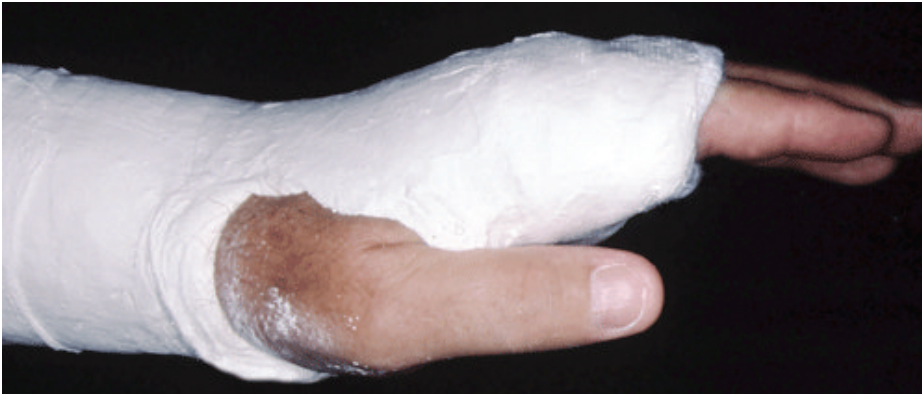

Figure 6. A non-removable cast focuses all active flexion and extension to the interphalangeal joints until motion in these joints is regained.

silver nanowire sensors which can be applied directly over joints to provide feedback about the pattern of active motion.¹⁵ Perhaps our focus will move toward prevention. Recent studies demonstrate that observation of hand action shows more cortical activity than viewing a landscape or imagining one's hand moving.¹⁶ Vibration applied to immobilised hands shows preserved sensorimotor networks in comparison to immobilised hands without vibration.¹⁷

Regardless of the new tools we may use, I hope we will shift our focus from passive range of motion to redirected active motion, providing the ideal dosage of both mechanical and cortical stress.

References

- Garcia-Elias M, An K-N, Berglund L, Linscheid R, Cooney WP, Chao EYS. Extensor mechanism of the fingers. I. A quantitative geometric study. *J Hand Surg [Am]* 1991;16A(No. 6):1130-1136.
- Donatelli R, Owens-Burkhart H. Effects of immobilization on the extensibility of periarticular connective tissue. *Jour of Ortho and Sports Physical Therapy* 1981;3(2):67-72.
- McClure PW, Blackburn LG, Dusold C. The use of splints in the treatment of joint stiffness: biologic rationale and an algorithm for making clinical decisions. *Phys Ther* 1994;74(12):1101-1107.
- Noyes FR. Functional properties of knee ligaments and alterations induced by immobilization. *Clinical Orthopaedics and Related Research* 1977;123:210-241.
- Flowers KR. Reflections on mobilizing the stiff hand. *J Hand Ther* 2010;23(4):402-403.
- Liepert J, Tegenthoff M, Malin J-P. Changes of cortical motor area size during immobilization. *Electroencephalogr Clin Neurophysiol* 1995;97:382-386.
- Kleim JA, Barbay S, Nudo RJ. Functional reorganization of the rat motor cortex following motor skill learning. *J Neurophysiol* 1998;80(6):3321-3325.
- Nudo RJ, Milliken GW, Jenkins WM, Merzenich MM. Use-dependent alterations of movement representations in primary motor cortex of adult squirrel monkeys. *J Neurosci* 1996;16(2):785-807.
- Elbert T, Rockstroh B. Reorganization of human cerebral cortex: The range of changes following use and injury. *Neuroscientist* 2004;10(2):129-141.
- Dehne E, Torp RP. Treatment of joint injuries by immediate mobilization. *Clinical Orthopaedics and Related Research* 1971;77:218-232.
- Grauer D, Kabo JM, Dorey FJ, Meals RA. The effects of intermittent passive exercise on joint stiffness following periarticular fracture in rabbits. *Clin Orthop* 1987;(220):259-265.
- Meals RA. Posttraumatic limb swelling and joint stiffness are not causally related experimental observations in rabbits. *Clin Orthop* 1993;287:292-303.
- Colditz JC. Therapist's Management of the Stiff Hand. In: Skirven TM, Osterman AL, Fedorczyk J, Amadio P, editors. *Rehabilitation of the hand and upper extremity*. 6th ed. Philadelphia: Elsevier Mosby; 2011:894-921. (PDF copy available on www.HandLab.com.)
- Colditz JC. Plaster of Paris: the forgotten splinting material. *Jour of Hand Ther* 2002;(15):144-157. (PDF copy available on www.HandLab.com.)
- Yao S, Zhu Y. Wearable multifunctional sensors using printed stretchable conductors made of silver nanowires. *Nanoscale*, 2014 www.rsc.org/nanoscale DOI: 10.1039/C3NR05496A.
- Bassolino M, Campanelli M, Bove M, Pozzo T, Fadiga L. Training the Motor Cortex by Observing the Actions of Others During Immobilization. *Cereb Cortex Advanced Access* 2013;1-9.
- Roil R, Kavounoudias A, Albert F et al. Cerebral preparation during immobilisation. *Neuroimage* 2012;62:510-519.

A review on the instability of the distal radioulnar joint

USA

Professor Jesse Jupiter from the Hand and Upper Extremity Service at Massachusetts General Hospital recently co-wrote a review on the instability of the distal radioulnar joint in the *Journal of Hand Surgery* (European Volume).

"With increased dependence upon computers, the return of forearm rotation especially pronation after trauma has become increasingly recognised," Professor Jupiter explained as the main motivation to review distal radioulnar joint instability and its management.

The distal radioulnar joint is a complex structure necessary for forearm motion and force transmission across the wrist. Anatomic and biomechanical advances have revealed broad contributions to distal radioulnar joint stability and refined our understanding of the forces acting across it. Instability often co-occurs with other modes of pathology, such as arthrosis or malunion; and appropriate diagnosis and treatment require a comprehensive understanding of all contributing factors.

For Jupiter, it is important for hand surgeons to understand that the distal radioulnar joint is the juncture and keystone of both the forearm and

wrist articulations and may be subject to injuries of one or the other. Distal radioulnar joint instability can be broadly categorised as primary, post-traumatic or post-surgical. Treatment strategies include percutaneous, arthroscopic, soft-tissue, osteotomy and arthroplasty techniques.

"Instability alone reflects the loss of the normal soft tissue constraints, but when associated with arthrosis or malunion of the distal radius, alternative options for reconstruction are required," he explained. When asked what aspects of the management of distal radioulnar joint instability require further development in hand surgery, Jupiter highlighted the need for further evaluation. "Better imaging of the bony and soft tissue components of the distal radioulnar joint will be useful as well as more predictable treatment of soft tissue injuries involving the Triangular Fibrocartilage and ligaments are needed," he concluded.

"With increased dependence upon computers, the return of forearm rotation especially pronation after trauma has become increasingly recognised"

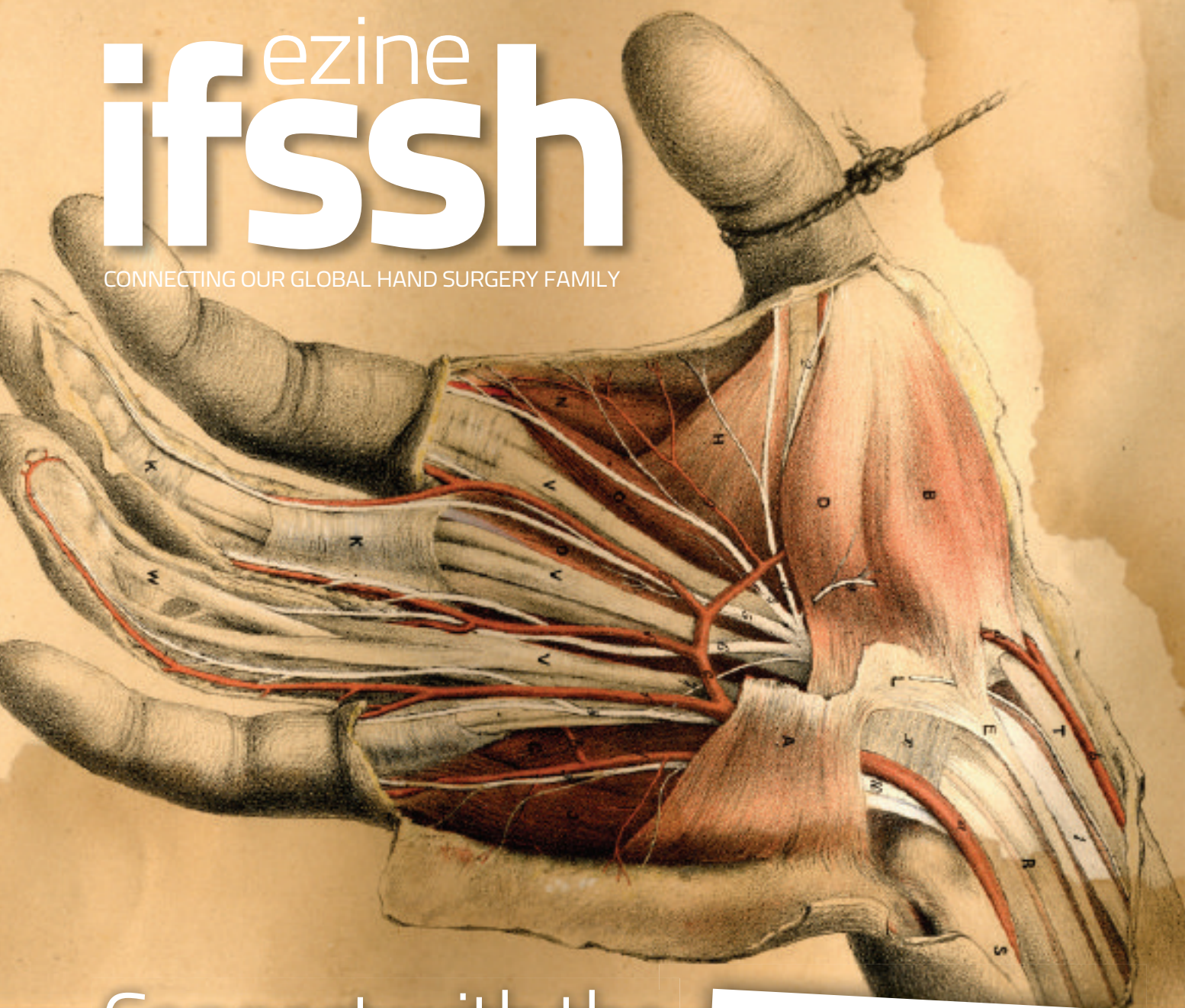JOURNAL REFERENCE

Instability of the distal radioulnar joint
J Hand Surg Eur Vol. 2014
Sep;39(7):727-38. doi:
10.1177/1753193414527052. Epub
2014 Mar 11.

[<http://jhs.sagepub.com/content/39/7/727.short?rss=1&ssource=mfr>]

ezine ifssh

CONNECTING OUR GLOBAL HAND SURGERY FAMILY



Connect with the global profession

The IFSSH ezine is created with the intention of engaging the global hand surgery community and to promote the profession through the sharing of knowledge. In order for the IFSSH ezine to remain relevant and topical, we rely on you, our readers, to:

- Subscribe to receive the ezine
FREE OF CHARGE 4 times per year
- Submit letters to the editor
- Provide us with feedback about the ezine



Sowing the seeds of hand surgery and rehabilitation in Rwanda

Ch. Gatsinzi*, Ph. Pieret** & O. Delaere***

* Centre de Rééducation et de Réadaptation Fonctionnelle Orkidé, Kigali, Rwanda

** Hand Rehabilitation Department, Centre Hospitalier Tubize-Nivelles, Nivelles, Belgium

*** Hand and Microsurgery Department, Centre Hospitalier Tubize-Nivelles, Nivelles, Belgium

The Republic of Rwanda is a small country of 10,169 square miles in the heart of the western Rift Valley in central-east Africa. Its population density is among the highest of the continent (435 people per square km). The country ended 2012 with a population of 11,457,801 people.

The population of Kigali, Rwanda's capital city is expected to double by 2020 to 2 million inhabitants (Figure 1). Such growth goes with increasing demand for basic health services and brings unrelenting pressure to bear on the environment in general ¹.

To be able to answer these needs, the Ministry of Health in Rwanda allocated funds and partnered with a consortium of top US institutions of medicine, nursing, health management and dentistry which are committed to sending faculty students to schools of medicine and nursing, as well as hospitals throughout Rwanda. The Human Resources for Health (HRH) programme, launched in July 2012, is expected to "build the health care

education infrastructure and workforce necessary to create a high quality, sustainable health care system in Rwanda, by addressing the country's most challenging health care obstacles, i.e. the critical shortage of skilled health workers or the inadequate infrastructure, equipment and management of health facilities"².

The current statistical data from the Rwanda Medical Council show that the majority of Rwandan physicians are General Practitioners. They now number 692, versus 207 specialists of whom only 31 are surgeons.

According to the HRH ³, the number of undergraduate candidates has steadily increased since the reopening of the National University of Rwanda in Butare, after the 1994 genocide. Post-graduate degrees with a residency component allow doctors to practise as specialists. In 1997, post-graduate training programmes in medicine were launched with Belgian collaboration and students were required to spend one year in Belgium

or France during their training. Thanks to this programme 17 specialists were able to graduate by 2004. In 2005, an in-country training programme was launched. Currently, seven post-graduate training programmes are available to physicians in Rwanda: internal medicine, paediatrics, obstetrics-gynaecology, surgery, anaesthesia, family and community medicine, as well as ear-nose-throat. Other specialists and sub-specialists are extremely rare in Rwanda and typically are trained abroad ³.

Hand surgery unfortunately falls into this category and at the present time is at an embryonic stage. Hand pathologies in developing countries differ considerably than in the industrialised ones. Most of them relate to trauma, congenital abnormalities or infectious diseases. But they might be even more disabling than in the so-called developed countries, since most of the population is rural and their hands are amongst their most vital tools ⁴. Delayed diagnoses and

treatments are most common which is all the more detrimental as early surgery and rehabilitation are essential for optimal recovery in most of hand pathologies.

The best way to develop hand surgery and rehabilitation is to build a partnership between local health workers and surgeons and therapists from abroad. This partnership includes annual educational missions, providing adequate equipment and techniques or sponsored fellowships in Hand Surgery centres ³.

In March 2013, a hand rehabilitation seminar was held at the Hotel des Mille Collines in Kigali. A Hand Therapist from Belgium, Philippe Pieret (Figure 2), was invited to speak about sensory re-education of the Hand. Attendance was high and the initiative met with great enthusiasm, especially by Charles Gatsinzi, a Rwandan physiotherapist working at the Orkidé private centre in Kigali.

Charles and Philippe got along instantly and agreed on a cooperation project in the field of hand care and rehabilitation.

Another hand seminar was organised by Charles in March 2014 and this time, Dr Olivier Delaere, a Belgian hand surgeon took part in the trip. A whole morning session was dedicated to the basics of hand trauma, the concept of total hand care and the mandatory partnership between surgeon, physiotherapist and patient (Figure 3).

Once again, the audience showed strong signs of interest and never hesitated to ask relevant questions about the subject. Thanks to this meaningful interaction, the hand

surgeon and therapists were able to identify the primary needs in the field. In particular, congenital and post-traumatic brachial plexus palsies seemed to be considered as a real issue in terms of diagnosis, prognosis or treatment.

The Belgian delegation also took the opportunity to visit a local hospital in Kigali, named Hôpital La Croix du Sud (Figure 4) in the company of Dr Tugilimana, Head of the Department of Surgery and better known as Musa (Figure 5). Musa was rather proud to show how the infrastructure of his hospital was growing fast and compared very favourably with the western world. Electronic medical records for example are based on the same software as that used in Belgium. Obviously these kinds of hospitals are ready to accommodate most hand surgery procedures.

While showing his workplace, Musa suddenly realised that his visiting colleague was the son of his former professor in general and orthopaedic surgery in Belgium, of which they were both totally unaware. It was an opportunity to exchange some excellent memories, in particular Musa's teacher aid mission to the Gatagara centre for the disabled in Rwanda more than 20 years ago. Needless to say, the Belgian delegation left the country with even more enthusiasm. Further visits are already planned for the end of 2014 and even for 2015. They should include workshops on hand splints and specific lectures about hand and upper limb palsies.

Given the growing population, the interest showed by local surgeons

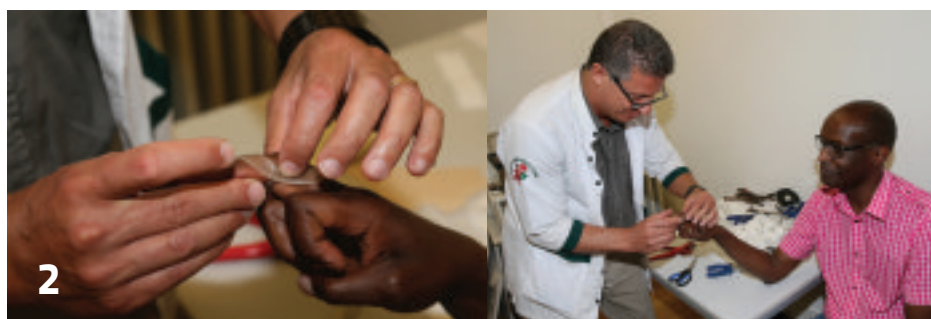and physiotherapists, the impressive economic growth of the country and the improvement of hospital facilities, conditions are undoubtedly in place to develop hand surgery and rehabilitation in Rwanda. Neither is there any doubt that everything will be done in the near future to optimise the partnership between local health workers and foreign teachers to reach this goal.

REFERENCES

1. <http://www.btcctb.org/en/casestudy/massive-population-growth-kigali-asks-efficient-urban-health-and-environment-services>
2. <https://globalhealth.duke.edu/education-and-training/trainees-fellows/hrh-rwanda>
3. <http://www.hrhconsortium.moh.gov.rw/about-rwanda/health-education/>
4. La Chirurgie de la Main dans les pays en voie de développement. Valenti Ph. Cahier d'enseignement de la Société Française de Chirurgie de la Main. N°7, 15-28, 1995.



1



2



3



4



5

1. The fast-growing city of Kigali.
2. Philippe PIERET, showing how to do a digital splint on a patient.
3. Dr Olivier DELAERE during his lecture about the "total Hand care".
4. Hôpital "La Croix du Sud" in Kigali.
5. Charles GATSINZI, Dr Olivier DELAERE & Dr Musa TUGILIMANA.

Pioneer profiles

Kauko A. Solonen, MD

Dr Solonen graduated from the Helsinki University Medical School in 1948 where he completed his specialty training in general and orthopaedic surgery. He also did two years of training in Paediatric Surgery. In 1955 and 1956, he was a UN Fellow in Amputation Surgery and Prosthetics, and studied at several centers in the United States and the United Kingdom. He planned the rehabilitation and prosthetic services for the amputated war veterans in Finland and helped establish the Rehabilitation Center in Kaskisaari, Helsinki in 1957 where he remained Chief until 1980. Dr Solonen was Lecturer and Assistant Professor (1959), and Associate Professor (1960 to 1968) at the Helsinki University Clinic for Orthopaedics and Traumatology.

In 1964, Dr Solonen was a Fulbright Fellow in Hand Surgery with Dr Leonard Goldner at Duke University in Durham, North Carolina, USA. He further studied hand surgery at the New York Hospital for Joint Diseases, under the tutelage of Emanuel B. Kaplan. He studied with a number of hand surgeons around the world including Hanno Milesi in Austria and Alfred B. Swanson in Grand Rapids, Michigan.

Dr Solonen is the father of modern Hand Surgery in Finland. In 1963, he established the first Department of Hand Surgery in Finland at the Helsinki University Clinic for Orthopaedics and Traumatology and was Head of the Department until 1968. He introduced the use of microsurgical techniques for orthopaedic surgery,



traumatology and hand surgery in 1968. He founded the Department of Hand Surgery at the Orthopaedic Hospital of the Invalid Foundation in Helsinki in 1970 and remained Chief of Department until 1984; he was also appointed Head and Surgeon-in-Chief from 1979 to 1984.

He is a Founder Member and first President of the Finnish Society for Surgery of the Hand which was established in 1977. He remained President of the Society until 1984. Dr Solonen's efforts resulted in the recognition of Hand Surgery as a specialty in Finland in 1978. He has helped introduce modern shoulder surgery in Finland and became Honorary Member of the European Society for Surgery of the Shoulder and Elbow in 1987. During his energetic career he trained most of

the Hand Surgeons in Finland.

Dr Solonen was the Finnish delegate to SICOT from 1980 to 1985, and is Honourary Member of the Finnish and Scandinavian Societies for Surgery of the Hand and of the Finnish Orthopaedic Association. He served as a member of the editorial board of Finnish hand surgery and orthopaedic journals. Dr Solonen, a dedicated teacher and lecturer, has published more than 200 scientific articles in various journals and textbooks.

Dr Kauko Solonen was honoured as "Pioneer of Hand Surgery" by the IFSSH at its Fifth Congress in Paris, France, in 1992

Paul Woodrow Brown, MD

Born in New York City , USA , 28 December 1919, Dr. Brown had his formal education disrupted – and his practical education enhanced – by World War II. Exchanging a machine gun for a medical kit on the invasion beaches of Sicily in 1943, he served as an enlisted medic through the Italian campaign and there developed a determination to become a physician. After attaining his degree in medicine at the University of Michigan in 1950 he returned to the Army for another twenty years to serve in various overseas posts in the Far East and Europe and in the wars of Korea and Vietnam. During his orthopaedic training in San Francisco he developed an interest in hand surgery under Drs Sterling Bunnell and Lot Howard and later took a hand surgery fellowship under Raymond Curtis at Walter Reed and Johns Hopkins Hospitals.

In the Sixties, Dr Brown developed a hand surgery center in Frankfurt, Germany for the US Armed Forces and State Department personnel in Europe, the Middle East and Africa. During the Vietnam War, at Fitzsimons Army Hospital in Denver, he established a hand surgery, amputation and orthopaedic center for the US Army. There he developed extensive rehabilitation programmes for amputees and other wounded soldiers, teaching them to ski, ride and swim, and for which he was awarded the Legion of Merit. These programs have since been emulated throughout the United States and Europe.

After retirement from the Army, Dr Brown established hand surgery centers at the Universities of Colorado and



Miami. He became Chief of Surgery at St. Vincent's Medical Center in Bridgeport, Connecticut where he chaired a general surgery residency program and also entered the private practice of surgery of the hand.

After retirement from the operating room, Dr Brown continued with medical consultation, teaching and writing. His professional interests included wound management, the role of patient motivation in rehabilitation, patient-physician communication and military medical history. He was a Clinical Professor of Orthopaedics and Rehabilitation and a Clinical Professor of Plastic and Reconstructive surgery at Yale University School of Medicine and a Medical Consultant to the Armed

Forces of the United States.

At the Sixth International Congress of the IFSSH in Helsinki, Finland, 3 July 1995, he was honoured as "Pioneer of Hand Surgery"

Dr Paul W Brown passed away on 4 May 2014 at the age of 94.

Journal Highlights

Below is a selection of contents pages from the latest issues of the following leading hand surgery journals. Hover your mouse over each article heading and click to go to the original abstract page of the article.

Journal of Wrist Surgery **Issue 03 Volume 03 • August 2014**

- Arthroscopic Thermal Capsular Shrinkage for Palmar Midcarpal Instability
- Carpal Malalignment in Malunion of the Distal Radius and the Effect of Corrective Osteotomy
- Surgical Techniques for the Management of Midcarpal Instability
- Distal Metaphyseal Ulnar Shortening Osteotomy: Technique, Pearls, and Outcomes
- Ulnar Shortening Osteotomy for Distal Radius Malunion
- The Effect of Supination and Pronation on Wrist Range of Motion
- Cadaveric Scapholunate Reconstruction Using the Ligament Augmentation and Reconstruction System
- Simulation of Altered Excursion of the Pronator Quadratus
- Primary Combined Replacements for Treatment of Distal Radius Physeal Arrest
- Resurfacing the Distal Radioulnar Joint with Rib Perichondrium—A Novel Method
- Conversion of Total Wrist Arthroplasty to Arthrodesis with a Custom-Made Peg

Journal of Hand Therapy **Volume 27, Issue 4, October-December 2014**

- Rigid versus semi-rigid orthotic use following TMC arthroplasty: A randomized controlled trial
- Sensorimotor interventions and assessments for the hand and wrist: A scoping review
- Relationships between pain misconceptions, disability, patients' goals and interpretation of information from hand therapists
- Clinical Commentary in response to: Relationships between pain misconceptions, disability, patients' goals and interpretations of information from hand therapists
- Response letter regarding the Clinical Commentary
- Hand therapist use of patient report outcome (PRO) in practice: A survey study
- Swing traction versus no-traction for complex intra-articular proximal inter-phalangeal fractures
- Ultrasonographic median nerve changes under tendon gliding exercise in patients with carpal tunnel syndrome and healthy controls
- A novel way of treating mallet finger injuries
- Dynamic hinged orthosis following a surgical reattachment and therapy protocol of a distal triceps tendon avulsion
- Sup-ER orthosis: An innovative treatment for infants with birth related brachial plexus injury

Hand **Volume 9 – Issue 3, September 2014**

- Reconstruction of malunited diaphyseal fractures of the forearm
- Ring injuries of the finger: long-term follow-up
- Secondary healing of fingertip amputations: a review
- Madelung's Deformity
- Morphometric analysis of the association of primary shoulder reconstruction procedures with scapular growth in obstetric brachial plexus paralysis patients
- Morphometric analysis of the effect of scapula stabilization on obstetric brachial plexus paralysis patients
- Four-corner arthrodesis with a radiolucent locking dorsal circular plate: technique and outcomes
- Outcomes after repair of subacute-to-chronic grade III metacarpophalangeal joint collateral ligament injuries in fingers are suboptimal
- Radiographic indicators of a shared epiphysis in radial polydactyly
- Long-term follow-up of osteochondral autologous transplantation in the metacarpophalangeal joints
- A prospective randomized trial comparing the effectiveness of one versus two (staged) corticosteroid injections for the treatment of stenosing tenosynovitis
- First carpometacarpal arthroplasty with ligamentous reconstruction: a long-term follow-up
- Excisional biopsy of suspected benign soft tissue tumors of the upper extremity: correlation between preoperative diagnosis and actual pathology
- Setting expectations following endoscopic cubital tunnel release
- Outcomes assessment of lunate replacement arthroplasty with intrinsic carpal ligament reconstruction in Kienböck's disease
- Translation and cultural adaptation of the Brief Michigan Hand Questionnaire to Brazilian Portuguese language
- Digital radiographic evaluation of hand-wrist bone maturation and prediction of age in South Indian adolescents
- Long-term outcomes following single-portal endoscopic carpal tunnel release
- Multicentric giant cell tumor of the fourth and fifth metacarpals with lung metastases

Journal of Hand Surgery (European Volume)

November 2014 J Hand Surg Eur Vol 39, Issue 9

- The Liebenberg syndrome: in depth analysis of the original family
- Embryology of familial (non-syndromic) brachydactyly of the hand
- Factors affecting surgical results of Wassel type IV thumb duplications
- Commentary on Patel, AUC. Tonkin, MA, Smith, BJ, Alshehri, AH, and Lawson. RD. Factors affecting surgical results of Wassel type IV duplications
- On the classification of congenital thumb hypoplasia
- Commentary on Tonkin. On the classification of congenital thumb hypoplasia
- Concurrent dorsal dimelia in 160 consecutive patients with congenital anomalies of the hands and feet
- Long-term effects of toe transfers on the donor feet
- Severity grading in radial dysplasia
- Results of syndactyly release using a modification of the Flatt technique
- Limb regeneration in salamanders and digital tip regeneration in experimental mice: implications for the hand surgeon
- Hyaluronic acid scaffold for skin defects in congenital syndactyly release surgery: a novel technique based on the regenerative model
- Bilateral terminal absence of the thumbs
- Tendon sheath washout using a Buchanan cholangiogram cannula
- Isolated second toe transfer after total amputation of the left fifth finger in a professional guitar player
- Minimizing trauma over 'no man's land' with flexor tendon retrieval
- How repeatable is two-finger tightness when used to tighten bone screws?
- Use of the DePuySynthes® Ulna Osteotomy System for large ulnar shortenings
- Enchondroma of the distal phalanx causing rupture of flexor digitorum profundus: Successful fixation avoiding a pull-out suture

Hand Surgery: Asia Pacific

Volume 19, Number 3

- Primary Flexor Tendon Repair And Early Mobilisation
- Associations Between Ulnar Nerve Strain And Accompanying Conditions In Patients With Cubital Tunnel Syndrome
- Objective Evaluation Of Elbow Flexion Strength And Fatigability After Nerve Transfer In Adult Traumatic Upper Brachial Plexus Injuries
- Wrist Rhythm During Wrist Joint Motion Evaluated By Dynamic Radiography
- Modified Brunelli Pull-Out Suture Technique In Zone I Flexor Tendon Rupture: A Fresh Human Cadaver Study
- Comparison Of Radiological And Clinical Outcomes Of Internal Fixation Using Two Different Volar Plates For Distal Radius Fractures
- Intra-Operative Correction Of Volar Tilt Of Distal Radius Fractures Using Volar Locking Plate As Reduction Tool: Review Of 24 Cases
- Lytic Lesions Of Distal Radius In Children: A Rare Tubercular Presentation
- Carpal Tunnel Release Using The Radial Sided Approach Compared With The Two-Incision Approach
- New Technique For Reducing Fibrosis In Recurrent Cases Of Carpal Tunnel Syndrome
- What Is The Better Treatment For Single Digit Dupuytren's Contracture: Surgical Release Or Collagenase Clostridium Histolyticum (Xiapex) Injection?
- Prospective Study On The Management Of Trigger Finger
- Treatment Of Chronic Mallet Fractures Using Extension-Block Kirschner Wire
- Tardy Posterior Interosseous Nerve Palsy Following Total Elbow Arthroplasty: Report Of A Case, Literature Review And A Classification System
- Unusual Case Of An Elbow Mass Caused By Candida Arthritis In A Patient With Systemic Lupus Erythematosus
- A Rare Combination: Locked Volar Distal Radio-Ulnar Joint Dislocation With Isolated Volar Capsule Rupture
- Volar Perilunate Trans-Scaphoid Dislocation: A Case
- Coronal Fracture Of The Scaphoid — A Case Report And Literature Review
- Bilateral Bipartite Carpal Scaphoid: A Case Report And Literature Review
- Treatment Of Hook Of The Hamate Fractures In Adults Using Low-Intensity Pulsed Ultrasound
- Locking Finger Due To A Partial Laceration Of The Flexor Digitorum Superficialis Tendon: A Case Report
- Irreducible Metacarpal Neck Fracture Caused By Interposition Of Junctiona Tendinum
- Is Masson's Tumour Only A Slow-Growing Benign Neoplasm? A Case Report
- Treatment Of Atrophic Nonunion Of Middle Phalanx In A Nine-Year-Old Boy With External Distraction And Bone Grafting
- An Adjustable Kirchner Wire Frame Traction Method For The Treatment Of Dorsal Fracture-Dislocation Of The Distal Interphalangeal Joint
- Crescent Flap For Fingertip Reconstruction
- Minimally Invasive Surgery For Radial Neck Fractures Using Bone Paste
- The Holevich Flap Revisited: A Comparison With The Foucher Flap, Case Series
- A Systematic Review Of Complications And Recurrence Rate Of Arthroscopic Resection Of Volar Wrist Ganglion
- Dupuytren's Contracture: Emerging Insight Into A Viking Disease

Journal of Hand Surgery: American volume

Volume 39, Issue 11, (November 2014)

- Outcomes of Revision Surgery for Cubital Tunnel Syndrome
- Pyrocarbon Interposition (PyroDisk) Implant for Trapeziometacarpal Osteoarthritis: Minimum 5-Year Follow-Up
- Effect of Carpometacarpal Joint Osteoarthritis, Sex, and Handedness on Thumb In Vivo Kinematics
- Reduction and Association of the Scaphoid and Lunate Procedure: Short-Term Clinical and Radiographic Outcomes
- An Outcomes Protocol for Carpal Tunnel Release: A Comparison of Outcomes in Patients With and Without Medical Comorbidities
- Carpal Tunnel Syndrome Diagnosis and Treatment: A Survey of Members of the American Society for Surgery of the Hand
- Electrophysiological Assessment of Carpal Tunnel Syndrome in Elderly Patients: One-Year Follow-Up Study
- Percutaneous First Annular Pulley Release for Trigger Digits: A Systematic Review and Meta-Analysis of Current Evidence
- The Efficacy of 95-Hz Topical Vibration in Pain Reduction for Trigger Finger Injection: A Placebo-Controlled, Prospective, Randomized Trial
- Trigger Finger: Assessment of Surgeon and Patient Preferences and Priorities for Decision Making
- Reattachment of Flexor Digitorum Profundus Avulsion: Biomechanical Performance of 3 Techniques
- Commentary on "Reattachment of Flexor Digitorum Profundus Avulsion: Biomechanical Performance of 3 Techniques". Zone I Flexor Tendon Repairs: More Strength Not Worth Altered Joint Kinematics
- Flexor Tendon-to-Volar Plate Repair: An Experimental Study and 3 Case Reports
- Use of Integra Artificial Dermis to Reduce Donor Site Morbidity After Pedicle Flaps in Hand Surgery
- Use of a Distal Ulnar Artery Perforator-Based Bilobed Free Flap for Repairing Complex Digital Defects
- Arcus Venosus Dorsalis Pedis: Morphological Considerations for Use in Superficial Palmar Arch Reconstruction
- The Effect of Brachioradialis Release During Distal Radius Fracture Fixation on Elbow Flexion Strength and Wrist Function
- Testing the Validity of Preventing Chronic Regional Pain Syndrome With Vitamin C After Distal Radius Fracture
- Effect of Anxiety and Catastrophic Pain Ideation on Early Recovery After Surgery for Distal Radius Fractures
- Treatment Strategy for Distal Radius Fractures With Ipsilateral Arteriovenous Shunts
- Force Recovery Assessment of Functioning Free Muscle Transfers Using Ultrasonography
- Comparison of Grip Strength Among 6 Grip Methods
- Factors Used by Program Directors to Select Hand Surgery Fellows
- Trapeziometacarpal Dislocation Without Fracture
- Persistent Fracture Line After Scaphoid Fracture Fixation
- Wide-Awake Extensor Indicis Proprius to Extensor Pollicis Longus Tendon Transfer
- Release of the A4 Pulley to Facilitate Zone II Flexor Tendon Repair

Upcoming events

Inaugural combined scientific meeting of the Singapore Society for Hand Surgery and American Society for Surgery of the Hand

25-28 February 2015

Singapore

www.sghand2015.org

The 24th Annual Hand Review Course and the Inaugural Joint Scientific Meeting of the SSHS, SRMS, and ASSH will bring together over 150 clinicians, nurses, medical students, residents and industry representatives from Asia Pacific, USA and UK to share and exchange knowledge, experiences and

expertise in the field of Hand Surgery and Reconstructive Microsurgery. Expect maximum amount of interaction and discussion through an exciting range of plenary sessions, informative lectures and lively workshops.

Please join us from 26 to 28 February 2015, at the Academia, Singapore General Hospital for the Annual meeting of the Singapore Society for Hand Surgery.



**INAUGURAL COMBINED SCIENTIFIC MEETING OF SINGAPORE SOCIETY FOR
HAND SURGERY AND AMERICAN SOCIETY FOR SURGERY OF THE HAND**

FEB 25 – 28 2015

SINGAPORE

This inaugural meeting of Singapore and American Societies for Hand Surgery is the culmination of the long standing relationship established through fellowship and cross cultural sharing of surgical ideas and philosophies. We welcome you to join us to share some quality time discussing issues on different aspects of hand surgery amidst the warmth and hospitality of Asia's cultural melting pot.

 **Singapore Society
for Hand Surgery**

 **ASSH** | American Society
for Surgery of the Hand

For more information, visit our website: www.sgshs.org.sg or contact our secretariat: sandra_ewyong@nuhs.edu.sg

8th International Poznań Course In Upper Extremity Surgery



Poznań, Poland
13-14 March 2015
www.termedia.pl

This year's edition of the course will focus on hand conditions, particularly tendon injuries and fractures, wrist arthroscopy, endoprosthesis and chronic lesions associated with rheumatic disease. The programme will feature scientific sessions, a symposium with a poster session, workshops and a joint session with physiotherapists. On the day before, there will be a cadaver course for which a separate registration is required. Additional sessions prepared by exhibitors will be available during lunch breaks. Participants will receive a certificate and credits for the course. In the evening, after the sessions, we will meet in the cosy atmosphere of the Old Town district to continue the exchange of expertise and strengthen our professional relationships. We are convinced that this year's course will be our shared success and that you will be encouraged to attend the event every year.

8th World Congress: World Society for Reconstructive Microsurgery

Mumbai, India
19-22 March 2015
www.wsr2015mumbai.com

We are embarking on the next half century of reconstructive microsurgery. Tissue engineering, allo-transplantation, genetic modulation, drug discovery and new methods of delivery will no doubt rely on the use of microsurgical techniques. We must continue to build on our foundation and look into the future. Attracting the next generation of microsurgeons is our mission and responsibility. Our goal is to be inclusive-encouraging all that have interest to come to Mumbai, and depart as a valued member of our microsurgical family. Please plan now to set aside March 19-22, 2015 for what I know will be a spectacular celebration of reconstructive microsurgery.

The 6th Combined Meeting of ASSH and JSSH: Unsolved Problems in Hand Surgery

Maui, Hawaii, USA
March 29 - April 1, 2015
<http://www.assh.org/Courses/ASSH-Courses/2015-ASSH-and-JSSH-Combined-Meeting>

The American Society for Surgery of the Hand (ASSH) and the Japanese Society for Surgery of the Hand (JSSH) invite you to submit an abstract for consideration at our 2015 Combined Meeting. The 6th Combined Meeting will bring hand care professionals from around the world together to share, discuss and learn about breakthrough techniques and procedures advancing the care and treatment of the hand and upper extremity. Mark your calendar for and join us in beautiful Hawaii!

Techniques in brachial plexus

Paris, France
17-18 April 2015
www.institutdelamain.com

As a Brachial Plexus surgeon, we realise that information is varied, sometimes crucial but very dependent on the precise technique described. It is very difficult to interpret the techniques described in the literature. This is the reason that has led us to organise the Symposium where the most inventive and experienced surgeons will present their technique in video and comment it. It will be interactive and the floor may discuss with these surgeons.

10th World Symposium on Congenital Malformations of the Hand and Upper Limb

7-9 May 2015

Rotterdam, The Netherlands

www.worldcongenitalhand2015.com

The 10th World Symposium on Congenital Malformations of the Hand and Upper Limb will be held on the 7th-9th May 2015, in Rotterdam, The Netherlands. A broad variation of congenital hand anomalies, genetics, embryology and classification will be presented, discussed and shared. Invited lectures, discussion, free paper sessions and panel sessions will inform you of the latest on congenital hand anomalies. Some of the keynote speakers are Michael Tonkin, Caroline Leclercq and Ann van Heest. The symposium will be preceded by a cerebral palsy pre course on Wednesday the 6th of May. For more information on the program and registration go to: www.worldcongenitalhand2015.com

2015 International Conference on Dupuytren Disease and Related Conditions

22-23 May 2015

Groningen, The Netherlands

www.Dup2015.com

This is a unique opportunity to present your Dupuytren related research to an international audience of experts.

This conference will showcase progress made since the 2010 Miami International Dupuytren Symposium and the work of the international community of patients and physicians on the cause, course, treatment and future of Dupuytren disease.

We invite you to submit your research for this meeting. We encourage presentation of all aspects of Dupuytren disease: genomics, cell biology, pathogenesis, surgery,

pharmacotherapy, radiotherapy, biomechanics, hand therapy and related conditions of Ledderhose, Peyronie and frozen shoulder. Abstract submission instructions are on the meeting website Dup2015.com. All abstracts must be submitted online. Abstracts must be in English and not exceed 500 words. Abstracts will be peer reviewed by an international panel. Accepted abstracts will be published on our website and will

*On behalf of the organizing committee
Steven Hovius and Christianne van Nieuwenhoven
would like to invite you for the*



10th World Symposium on Congenital Malformations of the Hand and Upper Limb

May 7-9 2015 Rotterdam, The Netherlands

Pre-Symposium on Cerebral Palsy on May 6 2015

A large international faculty will present on the following topics:
Cerebral Palsy / Introduction to Embryology, Genetics and Classification / Longitudinal radial ray deficiencies / Distraction / Syndactyly / Constriction ring syndrome/ Apert / Finger conditions / Radial polydactyly / Hypoplastic thumb / Pollicization / Vascular malformations and hypertrophic conditions / Microsurgery in the congenital upper limb / Arthrogryposis / Outcome measurements in congenital differences / Operating abroad / Rare forearm and hand conditions

[Info and registration @ www.worldcongenitalhand2015.com](http://www.worldcongenitalhand2015.com)

be available at the conference. Presentations will be videotaped and published online. Authors will be invited to submit a full paper of their presentation for book publication. Abstract submission deadline is 1 December 2014.

Hand and Wrist Biomechanics International (HWBI) Symposium

16-17 June 2015

Milan, Italy

www.hwbi.org/2015.html

In conjunction with 20th Congress of Federation of European Societies for Surgery of the Hand (FESSH 2015) and the 2nd International Thumb Osteoarthritis Workshop (ITOW 2015), the Symposium Chairs are Marc Garcia-Elias, MD, Insitut Kaplan, Spain and Frederick W. Werner, MME, SUNY Upstate Medical University, USA. The main topics are wrist, carpal tunnel, thumb, finger mechanics, DRUJ, distal radius, ligaments, tendons and biomaterials.

XX FESSH Congress

17-20 June 2015

Milan, Italy

fessh2015.org

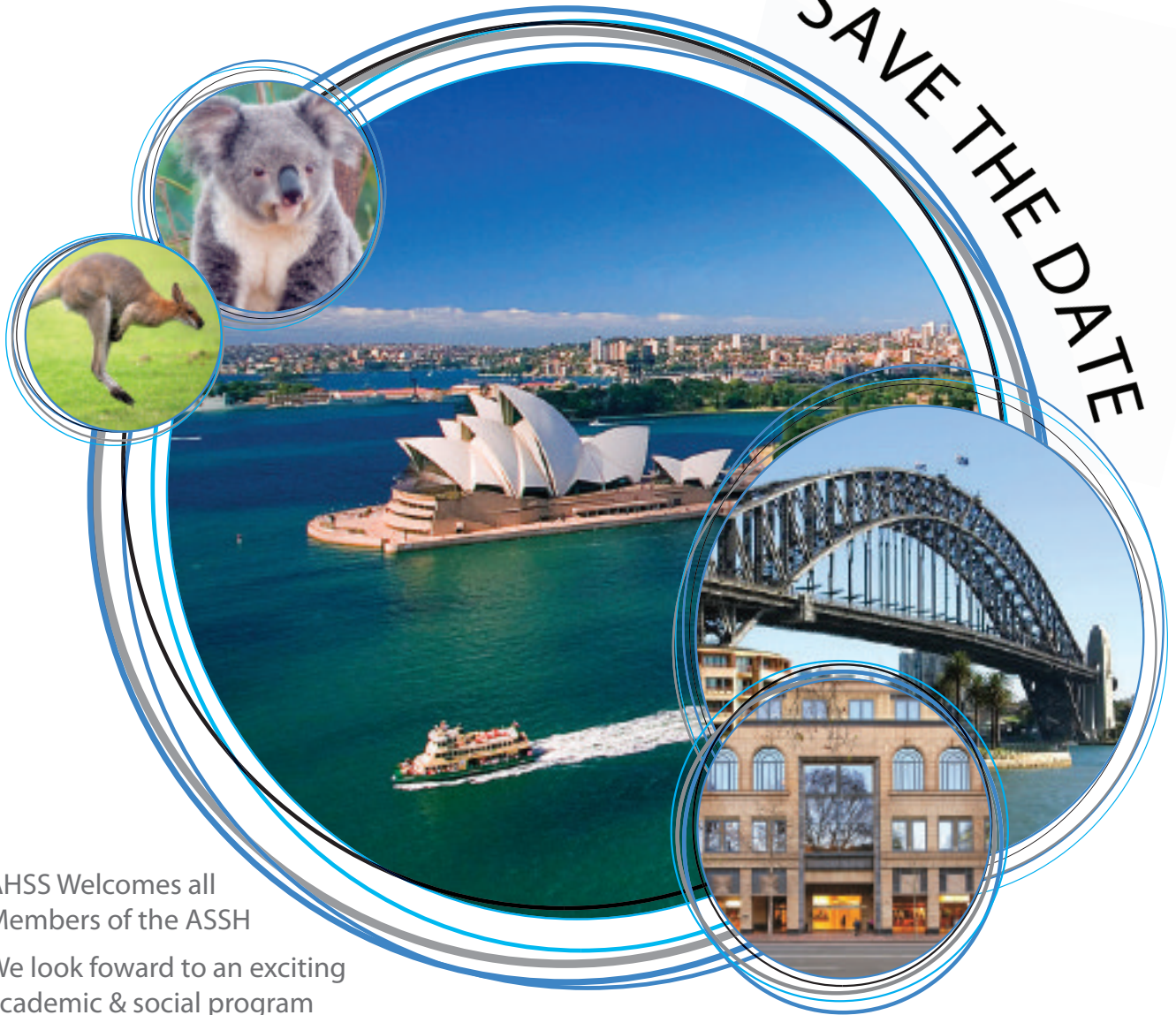In 2015, Federation of European Societies for Surgery of the Hand (FESSH) is organising the Annual FESSH Congress in the beautiful city of Milan in Italy. The congress will explore all aspects of hand surgery and its impacts. Surgical technology development, biomechanical tools, ethical, legal, social and financial topics, individualised medical aspects, diagnostic and therapeutic issues, advanced technologies, and many other related topics will be presented and discussed by professionals in their fields. We encourage delegates to use this congress as a meeting place to assemble their clinical and academic interest-groups. FESSH 2015 will be an intellectually broad and exciting event at which ideas and researchers from Europe and around the world interact.



Australian Hand Surgery Society & American Society for Surgery of the Hand 2016 Combined Meeting

Wednesday 30 March - Saturday 02 April 2016

SAVE THE DATE








AHSS Welcomes all
Members of the ASSH

We look forward to an exciting
academic & social program

DOLTONE HOUSE, SYDNEY, NSW AUSTRALIA



Conference Secretariat

 2016ahss@tayloredimages.com.au
 + 61 7 3366 2205 /  +61 7 3366 5170
 PO Box 247, ASHGROVE, QLD 4060
 332 Waterworks Road, ASHGROVE, QLD 4060

NEXT IFSSH & IFSHT

NEW DATES
**24-28
October
2016**

October 09 - 13, 2016

Argentina
Buenos Aires

**Make your plan for attending
to the first Congress in South America!**

**Hilton Buenos Aires
& Convention Center**



Scientific Program: Symposia on the most controversial topics, updates by world renowned experts and best selected free papers.

Special Social Events and Tango Shows.
High quality meat and exquisite Malbec Wines.

High ranked Tourism: Patagonia and its glaciers, Iguazú Falls, Mendoza's Wine Routes and the incredible views of Purmamarca (Salta and Jujuy).

www.ifssh-ifsht2016.com



Buenos Aires 2016
**IFSSH & IFSHT
Congress**

