

## MEMBERS NEWS

- The birth and development of FESSH
- Japan: A personal account from IFFSH Past-President
- Hand surgery Worldwide book launch

COLOMBIA-CZECH REPUBLIC-DOMINICAN REPUBLIC-EGYPT-FINLAND-FRANCE-GERMANY  
MALAYSIA-MEXICO-NEW ZEALAND-NORWAY-PHILIPPINES-POLAND-PORTUGAL-PUERTO RICO  
-THE NETHERLANDS-TURKEY-UNITED KINGDOM-UNITED STATES-URUGUAY-VENEZUELA

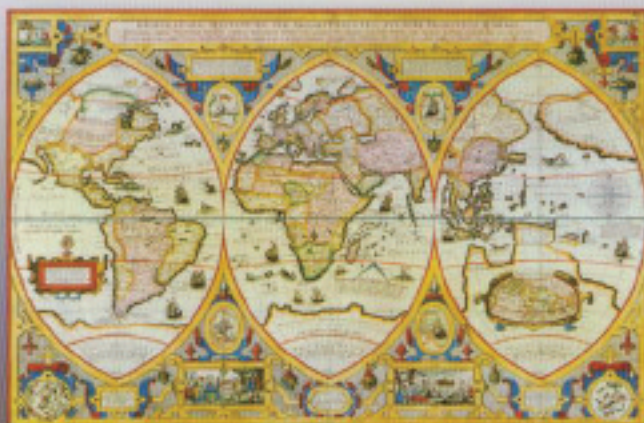

# HAND SURGERY WORLDWIDE

---

International Reconstruction of a "Beautiful  
and Ready Instrument of the Mind"

---



Editor

**James R. Urbaniak**

**COMMITTEE REPORT:** NEW CLASSIFICATION  
OF CONGENITAL ANOMALIES OF THE HAND  
AND UPPER LIMB

**RESEARCH ROUNDUP:** ENDOSCOPIC  
JOURNEY INTO THE FUNCTIONING OF  
CONNECTIVE TISSUE SLIDING



# Sustain Compression. Eliminate Migration.

THE SOLUTION FOR SIMPLE FRACTURES.



## Introducing the Acumed® Dual-Trak Clavicle Screw System

Increased patient acceptance and reduced surgery time set the Acumed® Dual-Trak Clavicle Screw System apart. A innovative solution for acute fractures, malunions and nonunions of the clavicle, the Dual-Trak Clavicle Screw offers a completely intramedullary clavicle fracture option that sustains superior compression, eliminates hardware irritation and offers a minimally invasive surgical technique.



View Surgical  
Technique



Download  
Brochure



Visit Our  
Website



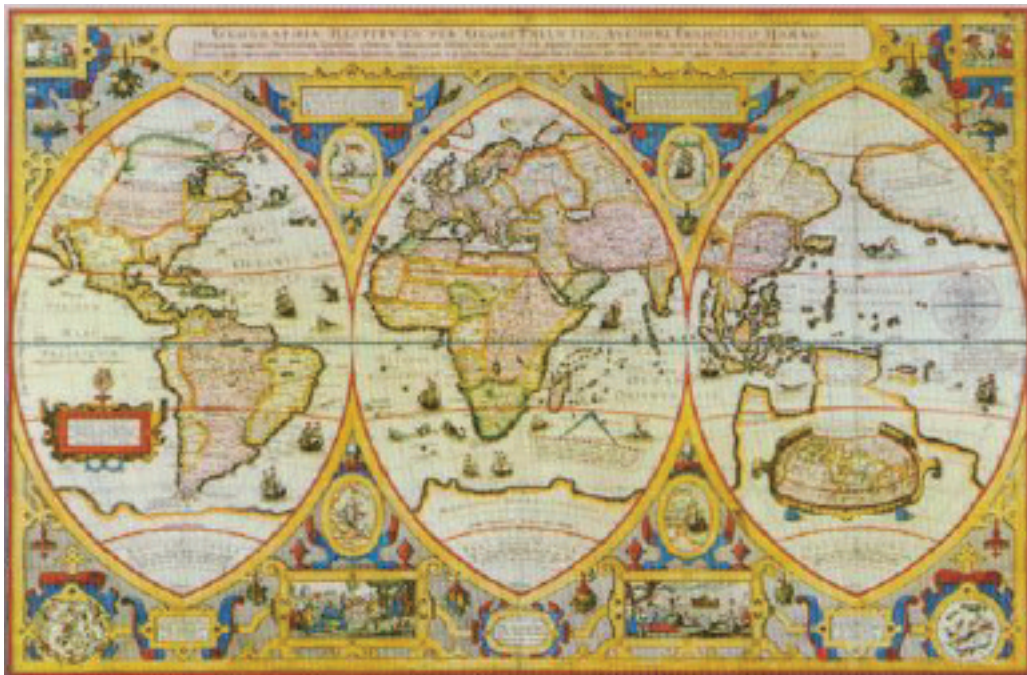
Contact Us

For more in depth product information including interactive 3D models visit  
[www.acumed.net/ifssh](http://www.acumed.net/ifssh) • (888) 627-9957

**ACUMED®**  
Innovative Solutions



# Contents



## 4 Editorial

By Professor Ulrich Mennen, editor of the IFSSH ezine

## 6 Letters

Questions for the Editor

## 8 Members News

The birth and development of the FESSH  
Book launch: Hand Surgery Worldwide

## 12 Pulse

Congenital Committee Report:  
A new classification of congenital anomalies

## 16 Research Roundup

An endoscopic journey into the functioning of  
connective tissue sliding

## 20 Product News

Arthrex: Mini TightRope® CMC Fixation  
Synthes: LCP Distal Ulna Plate

## 22 Journal Highlights

Tables of Contents from leading journals such as  
The American Journal of Hand Surgery, Journal  
of Hand Surgery Asian Volume, Journal of Hand  
Surgery European Volume and the Journal of Hand  
Therapy.

## 24 Upcoming Events

List of global learning events and conferences for  
hand surgeons.

# Editorial



The International Federation of Societies for Surgery of the Hand (IFSSH) is an umbrella organization to co-ordinate and promotes the optimal management of hand conditions. This Organization is run by volunteers and the smooth running is dependent on the keen co-operation of its members.

My request to you is to forward this IFSSHazine to those colleagues who may not yet have subscribed to the ezine. The first ezine was sent mainly to those who attended the 11th IFSSH Congress in Seoul. It is our intention to send this free electronic information magazine to all our members.



From the responses received, the IFSSH ezine fulfils a much anticipated need to communicate relevant information amongst hand surgery and hand therapy colleagues internationally. I also urge the Delegates of the National Societies to send the email addresses of all their members to [ezine@ifssh.info](mailto:ezine@ifssh.info). (If for some reason a member does not want to receive the ezine, he/she can simply unsubscribe)

I hope you enjoy this edition!

Do not hesitate: send your contributions! It is your magazine!

With sincere regards

ULRICH MENNEN

President: IFSSH

Editor: IFSSHazine, May 2011

## IFSSH disclaimer

The IFSSH ezine is the official mouthpiece of the International Society for Surgery of the Hand. The IFSSH does not endorse the commercial advertising in this publication, nor the content or views of the contributors to the publication. Subscription to the IFSSH ezine is free of charge and the ezine is distributed on a quarterly basis. To subscribe, please [click here](#). Should you wish to support this publication through advertising, please [click here](#).

## IFSSH ezine editorial team

**Editor:** Professor Ulrich Mennen (*President of the IFSSH*)

**Deputy Editor:** Professor Michael Tonkin (*President-elect of the IFSSH*)

**Publication coordinator:** Marita Kritzing (*Apex ezines*)

**Graphic Designer:** Andy Garside

SUBSCRIBE TO THE  
ezine  
**ifssh**  
FOR FREE

On behalf of the International Federation of Societies for Surgery of the Hand (IFSSH), I sadly would like to add our most sincere condolences to the many messages of sympathy that have been offered to the Manske family.

Paul Manske unexpectedly passed away on 21 April 2011.

He was an extraordinary man in many respects, and will always be honoured and remembered by the Hand Surgery fraternity for his example as role model, his original academic insights, his lasting literary contributions, his profound wisdom, and also as a gentle and humble human being.

Paul Manske was the longest serving Editor-in-Chief of the American Volume of the Journal of Hand Surgery when he retired at the end of 2010.

Paul, we will all miss you.

### **Some of his notable achievements:**

- 1960 President's Award, Valparaiso University
- 1983–95 Chairman and Fred C. Reynolds Professor, Orthopaedic Surgery, Washington University School of Medicine
- 1985 Alpha Omega Alpha, Washington University School of Medicine
- 1985 Doctor of Science (Honoris Causa), Valparaiso University
- 1985 Elizabeth Winston Lanier Award, Kappa Delta Paper — American Academy of Orthopedic Surgeons/Orthopedic Research Society
- 1991 Nicholas Andry Award for Orthopaedic Research, Association of Bone and Joint Surgeons
- 1993–2003 Board of Directors, Valparaiso University
- 1996–2011 Editor-in-Chief, American Journal of Hand Surgery
- 2006 Palma Chironis Resident Teaching Award, Department of Orthopaedic Surgery, Washington University School of Medicine



***Paul R. Manske, MD 1938-2011***

**Source:** *Washington University Orthopedics Department, St Louis, USA*

# To the Editor,

I have a ten year old female patient who appears to have developed **de Quervain's tenosynovitis** following a minor injury. Has anyone else seen de Quervain's in children?

Yours Sincerely

*Ian Edmunds*

HORNSBY, Australia

Email: [ianed@bigpond.com](mailto:ianed@bigpond.com)

**Dear Ian,**

Thank you for your email.

I have certainly not seen such a young De Quervain patient.

So far we have not received any response from any of our colleagues. The reason may be that nobody has had your experience, or that most people would not regard a direct injury as an etiology for de Quervains.

Let's hope other colleagues would share their views.

**Editor**







## A personal report from IFSSH Past- President, Yasuo Yamauchi, who lives in Tokyo, Japan.

### **Dear President Mennen and members of the IFSSH,**

Everything has changed in Japan after March 11 when the enormous earthquake hit the eastern part of Japan. I was in my house in Tokyo at the time, and felt an unusually large 'horizontal land-shake' that lasted for a long time. I could hardly stay standing. The houses outside seemed to be all right and inside my house, only five fine French wine glasses were found scattered on the floor, but watching the real-time TV news shocked me. Large tsunamis were just about to strike the cities on the Pacific coast. Most of the foreign reporters who visited the terribly damaged areas afterwards described how amazing it was to see that the people who had lost their homes and family members, were calmly enduring the tragedy without yelling, crying, quarrelling, stealing or rioting. Even with a smile on their face, they were helping each other. I am very proud of the people and glad to be one of them. Some of my former residents were affected by the tsunami, but fortunately they all survived. One of them is an orthopaedic surgeon practicing in Iwaki, only 20 miles south of the nuclear plant. Being a vice-president of the local medical society, he is still maintaining medical dispensaries for the city where he was born and raised, having sent his family back to a safer area. This man is not alone. Many of the emergency rescue medical taskforces

have volunteered their help in various places where medical and surgical care is desperately needed.

Almost all of the annual medical meetings and congresses were either postponed or cancelled, including the American-Japanese Hand Meeting in Hawaii. JSSH in Aomori and JOS (Japan Orthopaedic Society) in Yokohama are among them. As a consolation, I am sure the young surgeons who helped in the disaster area would have obtained invaluable experience, rather than merely attending the academic meetings.

Deep worries about the nuclear plant still exist, but this 79 year old orthopaedic and hand surgeon will not escape, and will continue to live in Japan with his beloved people.

I thank you very much for your help and sympathy to the disaster, from which, I am sure, we will survive, recover and stand tall again someday. I sincerely hope that the Japanese hand surgeons will meet you again in the near future, hands to hands, with a big smile on the face.

**Yasuo Yamauchi, MD**

3-30-14, Todoroki, Setagaya-ku,

Tokyo, JAPAN 158-0082

email: y-yama@xa2.so-net.ne.jp

# The birth and development of the Federation of European Societies for Surgery of the Hand

In 1989 Professor Alessandro Carolli of Modena convened a meeting involving delegates from 15 European National Hand Societies in Taranto. He presented delegates at the meeting with a proposal to form a European Federation of Hand Societies and offered for discussion a draft constitution. Discussions among delegates gave rise to a simpler draft constitution, which at the outset barely filled a single sheet of A4. It was agreed there would be a minimal amount of bureaucracy with the Federation led by a Secretary General rather than a President, supported by a Treasurer. There would be annual meetings with instructional courses.

Right from the outset there was wide-ranging support for Dr Alain Gilbert to become Secretary General. He was considered an obvious choice for this important post – enthusiastic about the concept with well recognised organisational skills and fluent in several languages.

The simpler draft constitution for a Federation of Hand Societies was agreed by the delegates, creating a European link between national societies rather than an additional organisation, which Hand Surgeons would join as individuals, that could potentially rival

their national societies. Professor Carolli was thanked by the delegates for convening the meeting and catalysing the discussions. He was presented with a silver bowl by the delegates in recognition of his contribution to the development of the European Federation.

Dr Alain Gilbert was asked to convene a meeting in Paris several months later and Nicholas Barton (Editor of the Journal of Hand Surgery) was asked to re-draft the constitution to remove ambiguities and ensure clarity of meaning. The revised document was submitted to the Councils of the National Societies for their approval.

Subsequently, 15 representatives of nations met in Paris on the 11th February 1990 to advance the development of the Federation. Thirteen councils had agreed the draft constitution with Norway and Sweden as observers pending ratification of the document. The first issue related to language. The working language of the council was agreed to be English with minutes provided by the United Kingdom representative. Alain Gilbert had organised a comprehensive agenda dealing with all the issues of principle where agreement was needed.

I think all delegates found the meeting exciting – planning a new project that would strengthen links between countries in Europe. There was a strong desire to bring together the best teachers in Europe for the benefit of trainee Hand Surgeons. Right from the start of discussions in Taranto, the annual instructional courses were considered pivotal to the development of the Federation. The training and specialisation committee was set up at the inaugural meeting to start to assess the variations in training between countries and to look to ways of strengthening and harmonising training within Europe.

The agenda in Paris inevitably dealt with a host of procedural matters, voting rights, funding strategy and composition of council. Plans were also made for the first congress which was to be held in Brussels in 1993 and the scientific committee was nominated. By the end of the day the general character of the new Federation was established with plans to meet again in Paris in December to develop matters further.

It has been interesting to note how differences of language, so important a concern at the outset, have gradually become a less important issue.





**ABOVE:** Professor Carolli is thanked for convening the meeting and catalysing the development of the European Federation.

**RIGHT:** Delegates in Taranto agreeing the draft constitution establishing the Federation of European Societies for Surgery of the Hand in 1989.



Simultaneous translation of instructional courses into a variety of languages was considered very important at the outset but the cost and complexity of translation obliged council and national societies to review the need for such facilities with each successive congress. Simultaneous translation for the benefit of the country hosting a congress still occasionally occurs, but even this service is considered to be rarely required. The need for a European Journal was also felt important at the inaugural meeting in Paris. After assessing the options, council subsequently elected not to create a new journal but to collaborate with the British Journal of Hand Surgery, more recently renamed the European Journal of Hand Surgery.

It is gratifying to see the current Council of FESSH continuing faithfully to promote the primary original aim of the Taranto delegates to

promote, rationalise and unify training throughout Europe and to define qualifications, organise courses and meetings and promote exchange programmes for surgeons in training. In recent years the Federation has welcomed several new societies from eastern European countries, where the status and provision of a hand surgery service is perhaps less well developed than some other countries in Europe. I know Massimo Ceruso and Zsolt Zsabo and the Council of FESSH are particularly keen to foster the development of hand surgeons and hand surgery in these countries by organising economical courses on relevant subjects, in keeping with the founding principles of the Federation.

If one spends all ones time focusing

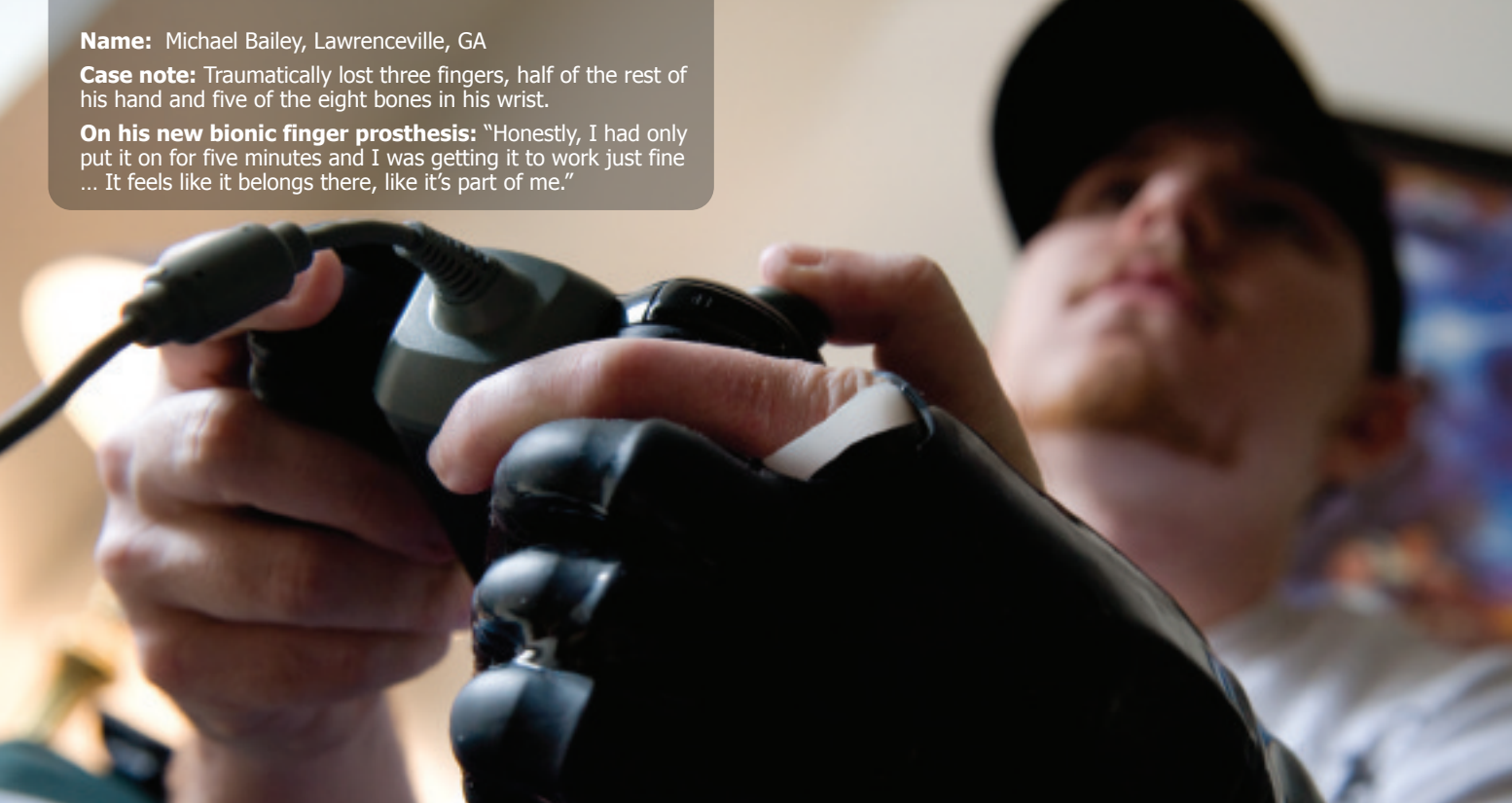on your personal practice of hand surgery, it is easy to doubt the benefit of supra national hand organisations. I have had the real pleasure of watching the European Federation of Hand Societies from its birth and I think it has and is making a major contribution to the development of hand care in Europe. This has occurred because those who founded the organisation chose the right aims and sought the help of able and active people to promote and develop those aims. The Council has a lot of worthwhile challenges ahead and it is gratifying to see that influence within the Federation remains with active people with progressive ideas and a keen sense of service. Long may it remain so.

**Frank Burke** Archivist IFSSH

**Name:** Michael Bailey, Lawrenceville, GA

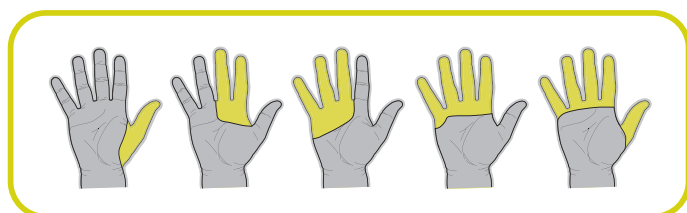
**Case note:** Traumatologically lost three fingers, half of the rest of his hand and five of the eight bones in his wrist.

**On his new bionic finger prosthesis:** "Honestly, I had only put it on for five minutes and I was getting it to work just fine ... It feels like it belongs there, like it's part of me."



## ProDigits: the world's first powered prosthetic fingers

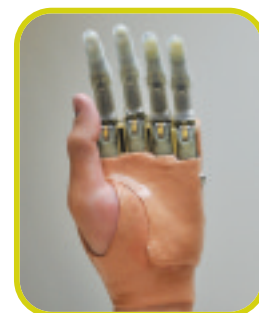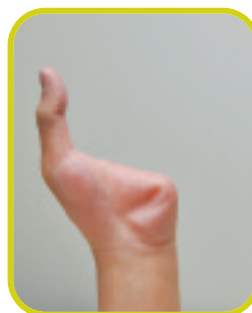- Fully customized to accommodate each patient's level of absence
- Suitable for patients missing between one and five fingers



- Provides partial hand patients with a return to function never previously available with prosthetics

### ProDigits in Practice

The photos below show a system built for a four digit amputee. This example shows an uncovered ProDigits prosthesis.



For more images and patient stories, visit [www.touchbionics.com](http://www.touchbionics.com)

Interested to know more about ProDigits? Working with a patient who may be a candidate? [Click here](#) to contact us today





# Hand Surgery Worldwide:

## International Reconstruction of a "Beautiful and Ready Instrument of the Mind"

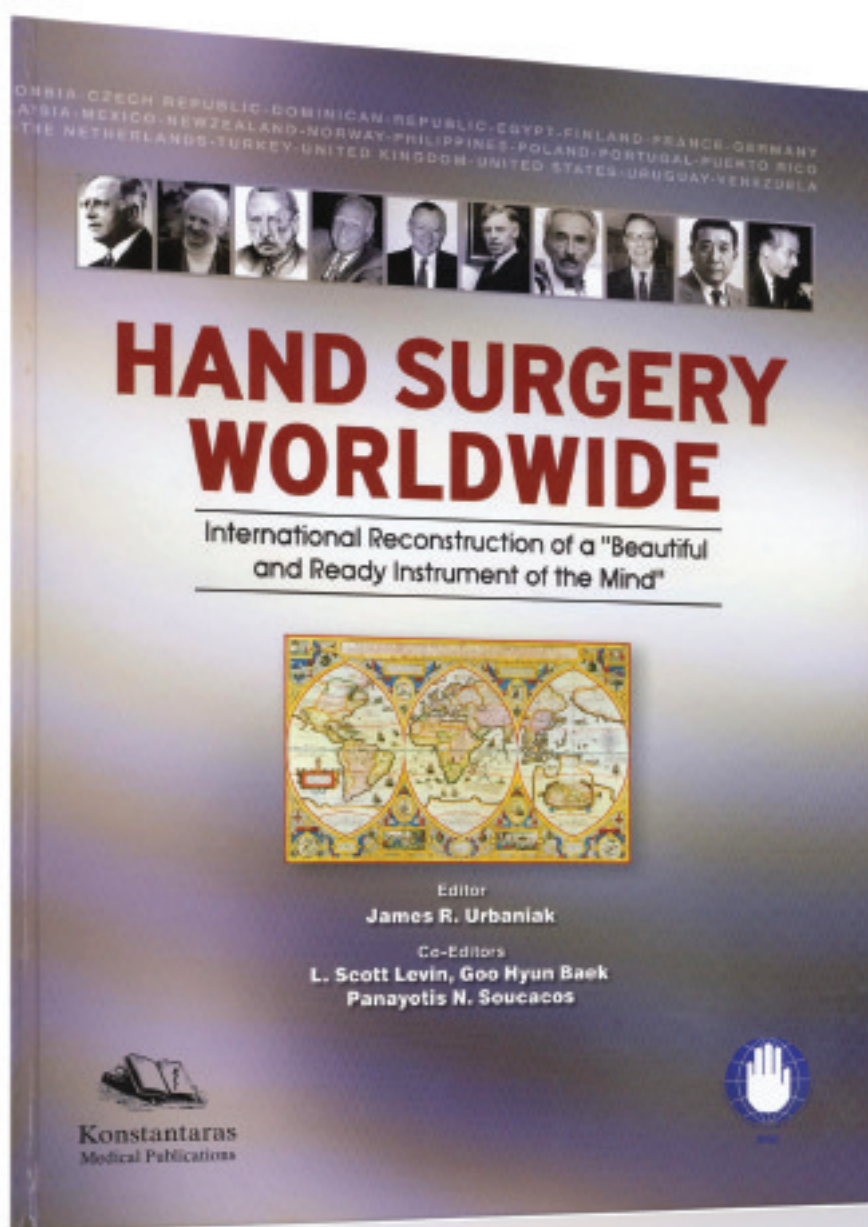
The International Federation of Societies for Surgery of the Hand (IFSSH) is pleased to announce that the book, *Hand Surgery Worldwide: International Reconstruction of a "Beautiful and Ready Instrument of the Mind"*, edited by James R. Urbaniak, L. Scott Levin, Goo Hyun Baek, and Panayotis N. Soucacos may be purchased for 60€. This book is unique for to our knowledge it is the sole publication that describes hand surgery in 50 different countries – all member societies in the International Federation of Societies for Surgery of the Hand (IFSSH). No other medical or surgical specialty has produced a similar publication on their specialty.

The book is comprised of two sections: One on the history, training, certification, contributions, pioneers, and culture as related to hand surgery in each country and written by leading hand surgeons from the 50 countries; the second on specific clinical topics in hand surgery authored by experts on the subject from 20 different countries. The book is written in a style for individuals interested in hand surgery at any level. It also describes the history of the IFSSH.

*Total pages: 431 and many beautiful color illustrations and pictures*

### ***It may be purchased in the following ways:***

1. *Amazon.com*
2. *medbooks@hol.gr (email to the publisher Konstantaras Medbooks)*
3. *Fax orders to the publisher +30 210 3628173*
4. *In Europe only, it can be purchased through Minerva Distributors and bookstores*



# A New Classification of Congenital Anomalies of the Hand and Upper Limb

## Report from the IFSSH Congenital Committee

Compiled by KC Oberg, JM Feenstra, PR Manske, and MA Tonkin

The current classification of congenital anomalies of the hand and upper limb is based on the work of Swanson and dates from 1964. Subsequently this classification was accepted by the International Federation of Societies for Surgery of the Hand (IFSSH) in 1974 as the optimal means of producing a consistent terminology which allows discussion of complex clinical entities, indications for treatment and comparisons of results.

Although Groups 1 and 2 suggest some relation to causation, this classification is largely based on appearance of the limb anomaly (Table 1). Regrettably, it is unable to cater for changes based on aetiology or on our increased understanding of developmental biology.

### The classification of the cleft hand complex

The controversy relating to classification of the cleft hand complex is illustrative. The IFSSH (Swanson) classification describes this as a central longitudinal deficiency, within Group 1: Failure of Formation. Miura, Ogino and others have described

the association of clefting, syndactyly and polydactyly in humans and have created this association of anomalies in experimental animal models. As a consequence of their elegant work, they and the Japanese Society for Surgery of the Hand (JSSH) suggested the addition of a further group to the IFSSH classification, this being an "Abnormal Induction of Rays".

**"Our increasing knowledge of limb embryology has defined the axes of growth and patterning of limb development, the signal centres which control these, and many of the morphogens which are expressed in specific regions."**

Unfortunately, although this suggestion is based on sound observation and impressive experimental work, the modification of a system which relies mainly on appearance results in contradictions which undermine the credibility of the classification. Radial and ulnar polydactyly remain within the group "Duplication", but a central polydactyly, although morphologically similar, becomes an "Abnormal Induction of Rays". The syndactyly of symbrachydactyly may be included in any of the following groups: "Failure of Formation", "Failure of Differentiation", "Abnormal Induction of Rays" and "Undergrowth".

Perhaps the distinction between "Failure of Formation", "Failure of Differentiation" and "Abnormal Induction of Rays" is an outdated concept. Formation and differentiation occur together. "Induction" simply means the effect of one tissue (an effector) on another. Rather than attempt to modify the IFSSH classification, we should aim for a system which indicates the site of insult in the limb bud, the timing of insult during development



and the causation at a molecular level. Our increasing knowledge of limb embryology has defined the axes of growth and patterning of limb development, the signal centres which control these, and many of the morphogens which are expressed in specific regions. Proximal-distal outgrowth is largely controlled by specialised cells within the tip of the limb bud, the apical ectodermal ridge (AER). Fibroblastic growth factors (FGFs) are the dominant morphogens. These interact with Sonic Hedgehog (SHH) protein which is expressed in mesodermal cells in the posterior (ulnar) portion of the limb bud, the zone of polarising activity (ZPA). The ZPA controls development and differentiation along the antero-posterior (radio-ulnar) axis. The secretion of Wnt-7a protein in the dorsal ectoderm regulates development and differentiation along the dorso-ventral axis through interaction with Lmx-1b transcription factor. This process of dorsalisation is blocked by Engrailed-1 (En-1) in the ventral ectoderm.

It is beyond the scope of this article to describe in detail the current understanding of the complex interactions between the above morphogens and many others, such as BMPs, HOX transcription factors, and other Wnt family proteins. However, many anomalies are related to one of these three axes and to abnormal expression of specific morphogens. Moreover, many anomalies predominately affect a specific part of the limb. Therefore, for instance, symbrachydactyly and transverse absences involve the proximal-distal axis and affect the whole limb. Radial

**TABLE 1: IFSSH (Swanson) Classification**

<b>Group I</b>	Failure of Formation
<b>Group II</b>	Failure of Differentiation
<b>Group III</b>	Abnormal Induction of Rays
<b>Group IV</b>	Duplication
<b>Group V</b>	Overgrowth
<b>Group VI</b>	Undergrowth
<b>Group VII</b>	Constriction Ring Syndrome
<b>Group VIII</b>	Generalised Skeletal Abnormalities
<b>Group IX</b>	Others

**TABLE 2: GROUP I – MALFORMATIONS**

<b>A. Failure of Axis Formation/ Differentiation – Entire Upper Limb</b>
1. Proximal-distal outgrowth
2. Radial-ulnar (A-P) axis
3. Dorsal-ventral axis
<b>B. Failure of Axis Formation/ Differentiation – Hand plate</b>
1. Radial-ulnar (A-P) axis
2. Dorsal-ventral axis
<b>C. Failure of Hand Plate Formation/ Differentiation – Unspecified Axis</b>
1. Soft tissue
2. Skeletal deficiency
3. Complex

longitudinal deficiency involves the radio-ulnar axis and may affect the whole limb. Ulnar dimelia (a “Duplication” in the IFSSH classification) involves the radio-ulnar axis and affects the whole limb. Thumb duplication involves the radio-ulnar axis but predominately affects the hand plate only. Dorsal dimelia involves the dorso-ventral axis and predominately affects the hand plate only.

Some anomalies do not appear to be related to one of the three axes of growth and differentiation, but predominately affect a specific part

**TABLE 3: MALFORMATIONS**

<b>A. Failure of Axis Formation</b>
<b>Differentiation – Entire Upper Limb</b>
<b>1. Proximal-distal outgrowth</b>
Brachymelia with brachydactyly
Symbrachydactyly
Transverse deficiency
Intersegmental deficiency
<b>2. Radial-ulnar (A-P) axis</b>
Radial longitudinal deficiency
Ulnar longitudinal deficiency
Ulnar dimelia
Radio-ulnar synostosis
Humero-radial synostosis
<b>3. Dorsal-ventral axis</b>
Nail-Patella syndrome
<b>B. Failure of Axis Formation</b>
<b>Differentiation – Hand plate</b>
<b>1. Radial-ulnar (A-P) axis</b>
Radial polydactyly
Triphalangeal thumb
Ulnar polydactyly
<b>2. Dorsal-ventral axis</b>
Dorsal dimelia (Palmar nail)
Hypoplastic/aplastic nail
<b>C. Failure of Hand Plate Formation</b>
<b>Differentiation – Unspecified Axis</b>
<b>1. Soft tissue</b>
Syndactyly
Camptodactyly
<b>2. Skeletal deficiency</b>
Brachydactyly
Clinodactyly
Kirner's deformity
Metacarpal and carpal synostoses
<b>3. Complex</b>
Cleft hand
Synpolydactyly
Apert hand

CONGENITAL

of the limb. Examples are syndactyly, camptodactyly, clinodactyly and cleft hand complex which mainly affect the hand plate.

Some anomalies do not appear to be related to one of the three axes of growth and differentiation, and do not consistently affect one specific part of the limb. Constriction ring syndrome is an example and would appear to be an insult to tissue that has already formed.

Some anomalies defy classification based upon the preceding criteria, that is an alignment with one of the three axes, involvement of a specific part of the limb, and/or an insult to tissue that has already formed. Macrodactyly, hemi-hypertrophy and congenital tumorous conditions remain difficult to classify.

If we apply the above principles it is possible to develop a new classification of congenital anomalies of the hand and upper limb as proposed by Oberg, Manske and Tonkin (the "OMT Classification"). It would appear that separation into three groups according to the terminology of dysmorphology offers a logical framework for conveying the aetiology of congenital anomalies:

- Group I – Malformations: an abnormal formation/differentiation of a body part or complex tissue
- Group II – Deformations: a change to tissue already formed
- Group III – Dysplasias: an abnormality in the size, shape and

organisation of cells within a tissue

The majority of anomalies which we surgeons confront are "Malformations". These may be sub-grouped according to the axis of formation/differentiation which is involved and the part of the limb which has been predominately affected (Table 2). Each anomaly retains its common surgical name as detailed in Table 3. Tables 4 and 5 list those conditions which are considered to be "Deformations" and "Dysplasias". The OMT classification is a combination of Tables 3, 4 and 5.

There may be dissent as to whether those conditions listed under "Dysplasias" are in fact "Deformations" or "Malformations". Further insights

**"It would appear that separation into three groups according to the terminology of dysmorphology offers a logical framework fo conveying the aetiology of congenital anomalies"**

TABLE 4: GROUP II – DEFORMATIONS

Constriction Ring Sequence
Arthrogryposis
Trigger Digits
Not Otherwise Specified

TABLE 5: GROUP III – DYSPLASIAS

<b>A. Hypertrophy</b>
1. Macrodactyly
2. Upper limb
3. Upper limb and macrodactyly
<b>B. Tumorous Conditions</b>

from developmental biology may prompt a transfer of a specific entity to either Group I or Group II. Furthermore, other aspects of this classification may demand modification. However, this approach to the classification of congenital anomalies of the hand and upper limb maintains common surgical terminology within a framework which indicates the site of insult and dysmorphological aetiology of the disorder, avoids descriptive terms for the main groups and allows modification as our knowledge increases.

**Footnote:** A more detailed description of this classification and its basis, along with full references for information included above, can be found in Oberg KC, Feenstra JM, Manske PR, Tonkin MA. Developmental Biology and Classification of Congenital Anomalies of the Hand and Upper Extremity. J Hand Surg 2010;35A:2066-2076.



*A TRADITION OF QUALITY AND INNOVATION*



\* Patented Subcondylar Plate



hand plating system

versatile **SOLUTION**  
for **COMPLEX** fractures

- low profile, variable angled locking plates
- dual compression hole configurations
- 5 different screw options
- enhanced instrumentation



A COLSON ASSOCIATE

visit us at [www.osteomed.com/hps](http://www.osteomed.com/hps)

3985 Arapaho Road, Addison, Texas 75001 • Customer Service: 800.456.7779 • Fax: 800.390.2620 • [www.osteomed.com](http://www.osteomed.com)

# An endoscopic journey into the functioning of connective tissue sliding

A recent study conducted by Jean-Claude Guimberteau, from the Aquitaine Hand Institute, France, describes the sliding tissue of the hand or the 'microvacuolar system' and demonstrates how movement of tissues can occur with minimal distortion of the overlying skin while maintaining tissue continuity.

"Understanding its structure and dynamic anatomy of all the fasciae in the hand may help improve outcomes after hand injury and disease. I was seeking a technical procedure to reconstruct flexor tendons, when I came upon the sliding system that I termed the MVCAS (multimicrovacuolar collagenic absorbing system)," Guimberteau explained.

Guimberteau first used a microscope to take a closer look at the subcutaneous tissue, according to him, which deftly ensures the efficiency of gliding structures and their independence, and is composed of a seemingly disorganised network of collagen fibrils. Known as areolar or connective tissue, its only function is to connect. "This disorganized pattern impressed me because my Cartesian mind could not come to terms with the idea of chaos and efficiency co-

existing perfectly. This was the starting point for an intellectual voyage that took me off the beaten track into the largely unknown world of fractals and the chaotic," he continued.

In his investigation he observed that all the tissues were developed within the framework of multifibrillar architectures and resulting from the intertwining of fibrils, microvacuoles are formed, which are intrafibrillar micro volumes. These form a polyhedral fibrillar frame enclosing multiple micro vacuolar spaces of varying sizes between 10  $\mu\text{m}$  and 100  $\mu\text{m}$ , with a gel inside. He noted these micro-fibrils to have a diameter of about ten to twenty microns and are made up predominantly of collagen type I and III.

According to Guimberteau, by intertwining in an irregular fractal manner, they determine the volume of the microvacuole, which is filled with a glycosaminoglycan gel. These fibrils frame the blood vessels and nerves. By accumulation and superposition, these multimicrovacuolar polyhedral patterns create an elaborate form. The microvacuolar concept can be used to explain the essential requirements for connective tissue, which are to ensure that the following functions all

take place simultaneously: movement, slippage, no effect on surrounding tissues, return to resting position, input of nervous or vascular energy and the constant maintenance of shape.

"The essential implications of these endoscopic observations are fibrillar continuity. There is no break in the tissue continuity, be it within muscle, tendons, or around the arterial, venous, nervous etc structures. All these structures are formed in the same manner and are continuous. The concept of the organisation of living matter into stratified layers, hierarchical layers of sheaths, lamellae and strata cannot satisfy an anatomist who studies precise, endoscopic, functional anatomy. Even though they may be of different colours, textures and shapes, they are all linked to each other. This is a global tissue concept," he added.

For Guimberteau, the most interesting outcome of the study is that the sliding system around the tendons was observed. "For many decades, terms such as elasticity, mobility, hierarchical tissue distribution, stratification and virtual space between organs have been taken for granted, yet the real basis for them needed to be investigated. Their scientific underpinnings were limited to the



*Click on the videos to play*



notion of virtual space or the existence of loose connective tissue, but the bio-mechanical foundations for these theories were more than vague. In the last 50 years, research has focused on the microscopic level while the global concept of mesosphericity has been abandoned. Furthermore, no physiological or microanatomical explanations have been proposed," he explained.

As time has passed and as researchers have examined these tissues more closely, new hypotheses have emerged concerning the organization of subcutaneous tissues and led to a new concept, the creation of a model and new surgical procedures. Not only is a better knowledge of the intimate physiology of the tendon vital, but the conditions favouring optimum function must be understood.

Guimberteau believes this approach to tendon physiology also supposes a completely different way of perceiving the problem of reconstruction. These observations demonstrating the real histological continuity between the paratenon, the common carpal sheath and the flexor tendons illustrate the perfect vascularization of this functional ensemble. They are



innovative in that they introduce a new concept of the sliding unit, which is composed of the tendon and its surrounding sheaths.

"From now on, Potenza's principle involving tendon adhesions and reconstruction of the digital sheath using a silicon rod, should be set aside in favour of other principles," he added, providing the list below:

- A tendon only has optimal functional value when it is surrounded by its original sliding sheath and its vascular heritage.
- A tendon is adherent only when it is artificially separated from its own sliding sheath, or when the harmony between the tendon and the sheath has been interrupted.
- A tendon is only one of the elements involved in the transmission of force through the sliding unit.

For zones III, IV, and V, the authors set out to define a different role for the tendon in the production and transmission of a force. "The tendon is not a transmission belt acting in the carpal sheath surrounded by a virtual space; nor is it an organ that is avascular or only very slightly vascularized. The tendon is not nourished by the synovial fluid, but by its own vascular system like every organ. It subtends the tendon-sheath couple and the major role of tendon vascularization with peripheral collagen organization. The strategy for secondary reconstruction is therefore totally changed. The idea is to transfer en bloc a reverse island vascularized digital flexion unit composed of the

**"This disorganized pattern impressed me because my Cartesian mind could not come to terms with the idea of chaos and efficiency co-existing perfectly."**

flexor tendon with the sliding sheaths from zones 3, 4 and 5 to zones 1 and 2 with or without a combined reverse Ulnar island skin flap in a single step. This new technique is now used for the reconstruction of finger flexor systems in Boyes grade III and IV salvage situations," he continued.

Guimberteau and his team will continue such explorative investigations using HD technology and they are currently preparing a film about the anatomy and physiology of tendons. "I am sure that in the future the intrabody exploration will be one of the new frontiers of medico-scientific discoveries and new technology will be the key point of this development," he concluded.

## Take home points:

- The connective tissue around the tendon consists of a framework of multifibrillar architectures
- These intertwining fibrils form microvacuoles which are intrafibrillar micro volumes that form a polyhedral fibrillar frame enclosing multiple microvacuolar spaces of varying sizes between 10 µm and 100 µm, with a gel inside
- These micro-fibrils to have a diameter of about ten to twenty microns and are made up predominantly of collagen type I and III
- An important observation is that of fibrillar continuity: There is no break in the tissue continuity, be it within muscle, tendons, or around the arterial, venous, nervous etc structures
- The sliding unit is composed of the tendon and its surrounding sheaths
- The tendon is not nourished by the synovial fluid, but by its own vascular system like every organ. It subtends the tendon-sheath couple and the major role of tendon vascularization with peripheral collagen organization

## JOURNAL REFERENCE

The microvacuolar system: how connective tissue sliding works  
J. C. Guimberteau, J. P. Delage, D. A. McGrouther, J. K. F. Wong  
J Hand Surg Eur Vol October 2010 vol. 35 no. 8 614-622  
<http://jhs.sagepub.com/content/35/8/614.abstract>

# ifssh<sup>e</sup>zine

CONNECTING OUR GLOBAL HAND SURGERY FAMILY

IFSSH 2010 SEOUL  
10th Triennial Congress of the International Federation of  
Societies for Surgery of the Hand  
October ~ 4 November 2010 | Sheraton Grand Walkerhill Hotel, Seoul, Korea



## For the members by the members...

The **IFSSH ezine** is created with the intention of engaging the global hand surgery community and to promote the profession through the sharing of knowledge.

In order for the IFSSH ezine to remain relevant and topical, we rely on you, our readers, to:

- Subscribe to receive the ezine  
FREE OF CHARGE 4 times per year
- Submit letters to the editor
- Provide us with feedback about the ezine

**CLICK HERE**

TO COMPLETE A  
5 MINUTE SURVEY  
ABOUT THE  
IFSSH EZINE

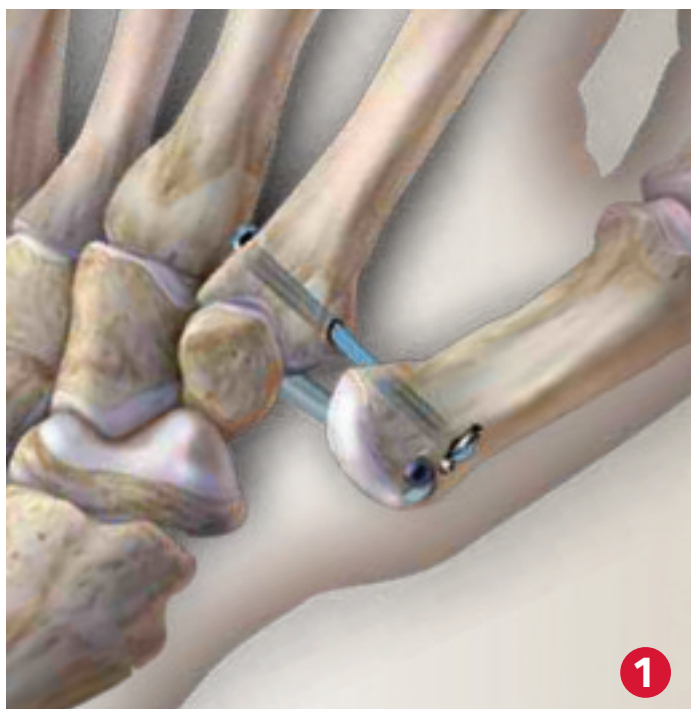


# Product News

## 1: Arthrex Mini TightRope® CMC Fixation

The Mini TightRope, in conjunction with a biologic repair, provides a unique means to stabilize the thumb metacarpal after a trapezial resection or removal for treatment of CMC arthritis. The Mini TightRope can also be used as an adjunct and stabilizer in CMC instability and in the case of revision with proximal migration after tendon reconstruction.

The Mini TightRope uses a pulley principle to help reduce the thumb and index metacarpals into proper



relationship that is maintained through healing. This construct consists of four passes of #2 FiberWire through two stainless steel buttons – one oblong for passage through bone tunnels and one round for cortical fixation. The trapezial space may be left empty, or filled with an allograft anchovy spacer.


### Advantages:

- Stabilizes and protects biologic repair
- May allow earlier rehabilitation
- Maintains trapezial space
- Solid and stable suspensionplasty
- FiberWire has little stretch
- Promotes scarring with micromotion
- Flexible suture based fixation

Since 1984, Arthrex has been a privately held corporation committed to one thing: providing the finest quality products and educational services to meet the special needs of surgeons and their patients. New product innovation in less invasive surgery is the heart and soul of Arthrex, which has resulted in the development of over 5,000 products for arthroscopic and minimally invasive orthopaedic surgical procedures.

[www.arthrex.com](http://www.arthrex.com)





## 2: Synthes – LCP Distal Ulna Plate

The distal ulna is an essential component of the distal radioulnar joint, which provides rotation to the forearm. The distal ulnar surface is also an important platform for stability of the carpus and, beyond it, the hand. Unstable fractures of the distal ulna therefore threaten both movement and stability of the wrist.

The size and shape of the distal ulna combined with the overlying mobile soft tissues, make application of standard implants difficult. The LCP Distal Ulna Plate has been specifically designed for use in fractures of the distal ulna. Its components include:

- Pointed hooks and locking screw in the head  
Pointed hooks to grip the styloid process and to act as reference point for plate application. Intercrossing locking screws securely hold the ulnar head. The shaft contains LCP combi-holes.
- Angular stability

The head accepts 2.0 mm locking screws. The shaft accepts either 2.0 mm locking or cortical screws.

- Oblong hole  
The oblong hole accepts 2.0 cortex screws for ulnar length adjustment.
- Anatomically precontoured  
The slim plate design, low screw/plate profile, rounded edges and polished surface limit the irritation of overlying soft tissues

[www.synthes.com](http://www.synthes.com)

FOR  
ADVERTISING  
OPPORTUNITIES  
**CLICK HERE**

Below is a selection of contents pages from the latest issues of the following leading hand surgery journals. Hover your mouse over each article heading and click to go to the original abstract page of the article

## Journal of Hand Surgery American Volume

**Issue: Vol 36 | No. 4 | April 2011 | Pages 577-774**

■ Commentary on "Biomechanical Properties of Volar Hybrid and Locked Plate Fixation in Distal Radius Fractures". E. Bruce Tony.

■ Arthroscopic Proximal Row Carpectomy. Noah D. Weiss MD, Ricardo A. Molina MD, Stephanie Gwin BS.

■ Avascular Necrosis of the Scaphoid After Three-Ligament Tenodesis for Scapholunate Dissociation: Case Report.

Luc De Smet MD PhD, Raf Sciort MD PhD, Ilse Degreef MD PhD.

■ Biomechanical Properties of Volar Hybrid and Locked Plate Fixation in Distal Radius

Fractures. Shima C. Sokol MD, Derek F. Amantullah MD PhD, Shane Curtiss AS, Robert M Szabo MD, PhD.

■ Quantitative 3-Dimensional Computed Tomography Measurement of Volar Shearing Fractures of the Distal Radius.

J Sebastian Suoer MD, Jimmie Wiggers MSc, David Ring MD PhD.

■ Analysis of Wrist Motion Following Vascularized Bone Graft to the Proximal Scaphoid. Christopher L. Hankins MD, Jeffery Evan Budoff, MD.

■ Cleft Hand in Kabuki Make-Up Syndrome:

Case Report. Jung Kyu Huh MD, Moon Sang Chung MD PhD, Goo Hyun Baik MD PhD, Joo Han Oh MD PhD, Young Ho Lee MD PhD, Hyun Sik Gong MD PhD.

■ Lengthening of a Thumb Distal Phalanx Replanted to Its Metacarpus Because of Loss of the Proximal Phalanx: Case Report. Mehmet Bekir Unal MD, Eren Casnu MD, Fatih Parmaksizoglu MD.

■ Congenital Hand Surgery Research and Education: Observations of the 2009–2010 Bunnell Traveling Fellow. Charles A. Goldfarb MD.

## Journal of Hand Surgery Asian Volume

**Volume: 16, Issue: 1 (2011)**

■ Is haptic feedback necessary to microsurgical suturing? Comparative study of 9/0 and 10/0 knot tying operated by 24 surgeons. Irakli Panchulidze, Stacey Berner, Gustavo Mantovani and Philippe Liverneaux.

■ Is velband still a safe and cost effective skin protection beneath the tourniquet in hand surgery? Shigong Guo.

■ Study of vascular supply of lunate and consideration applied to kienböck disease. P. P. Dubey, Navneet Kumar Chauhan, M. S. Siddiqui and Anoop K. Verma .

■ Reliability of Lichtman's classification for kienböck's disease in 99 subjects. Masaki Shin, Masahiro Tatebe, Hitoshi Hirata, Shukuki Koh and Takaaki Shinohara.

■ Tubercular osteomyelitis of metacarpals and phalanges in children. Anil Agarwal, Nadeem Akhtar Qureshi, Pawan Kumar and Shariq Khan.

■ Use of the volar fixed angle plate for comminuted distal radius fractures and augmentation with a hydroxyapatite bone graft substitute. Akira Goto, Tsuyoshi Murase, Kunihiro Oka and Hideki Yoshikawa.

■ Predicting the result of nerve conduction tests in carpal tunnel syndrome using a questionnaire. M. J. Bridges, D. C. Robertson and A. J. Chuck.

■ Morphometric and biomechanical comparison of tendons used for interposition arthroplasty in carpometacarpal arthritis of the thumb. T. J. Colegate-Stone, S. Garg, A. Subramanian and G. V. Mani.

■ Thumb metacarpophalangeal arthrodesis with local bone grafting. Rebel Huffman and Ghazi M. Rayan.

■ Reconstruction of the first web in congenital thumb anomalies. Yasushi Morisawa, Shinichiro Takayama, Atsuhito Seki, Toshiyasu Nakamura and Hiroyasu Ikegami.

### Case reports:

■ Attritional rupture of extensor pollicis longus: a rare complication following elastic stable intramedullary nailing of a paediatric radial fracture. James A. Sproule, Simon J. Roche and Eswara G. Murthy.

■ Non-union of an undisplaced radial styloid fracture in a heavy smoker: revisiting the

association of smoking and bone healing. Khaled M. Sarraf, Aniket Tavare, Naresh Somashekar and Ronald J. Langstaff.

■ Bilateral congenital hypoplasia of the extensor tendons of the hand: a case report. Samuch Tungshusakul, Somsak Leechavengvongs and Chairaj Uerpairojkit.

■ Painful heterotopic pacinian corpuscle in the hand: a report of three cases. Hiroki Irie, Teiji Kato, Toshitake Yakushiji, Jun Hirose and Hiroshi Mizuta.

■ Intravenous pyogenic granuloma of the hand — a case report. J. Joethy, I. Al Jajeh and S. C. Tay.

■ Duplicated thumb with enormous soft-tissue oedema — pacifier type of thumb duplication. Kensuke Ochi, Yukio Horiuchi, Shinichiro Takayama and Harukazu Saito.

■ Neuroma of the radial digital nerve of the middle finger following trigger release. S. Sreedharan, L. C. Teoh and W. Y. C. Chew.

■ Negative pressure therapy with irrigation for an infected digit: a preliminary report. Masao Fujiwara, Yuki Matsushita and Hidekazu Fukamizu.

## Journal of Hand Surgery European Volume

### J Hand Surg Eur Vol March 2011 36: 251-252

- Unipedicled laterodigital transposition flap for covering dorsal longitudinal skin defects in multi-digit injuries. T. Toros, K. Özaksar, T. Sadik Sügün, M. Kayalar, E. Bal, Y. Ademoğlu.
- Management of severe hand wounds with Integra® dermal regeneration template. R. Weigert, H. Choughri, V. Casoli.
- Long-term functional results of microvascular toe-to-thumb reconstruction. T. Kotkansalo, S. Vilkkii, P. Elo, T. Luukkaala.
- Zone 2 lacerations of both flexor tendons of all fingers in the same patient. M. M. Al-Qattan.
- Optimal configuration of the spiral linking technique for tendon repair. Biomechanical evaluation. Y. I. Kulikov, Y. Vinogradova, A. W. Miles, G. Giddins.
- Pain and paraesthesia produced by silicone ring and pneumatic tourniquets. A. Mohan, A. Baskaradas, M. Solan, P. Magnussen.
- Patient controlled regional analgesia after

- carpal tunnel release: a double-blind study using distal perineural catheters. Anil Gupta, Narinder Rawal, Anders Magnuson, Håkan Alnehill, Kurt Pettersson.
- Incidence of community-acquired methicillin resistant *Staphylococcus aureus* hand infections in Tayside, Scotland: a guide to appropriate antimicrobial prescribing. S. Hassan, W. Gashau, L. Balchin, G. Orange, A. Wilmschurst.
- Assessing angulation on digital images of radiographs of fractures of the distal radius: visual estimation versus computer software measurement. G. A. J. Robertson, B. F. M. Robertson, B. Thomas, J. McEachan, D. M. Davidson.
- Effects of topical corticosteroids on the sciatic nerve: an experimental study to adduce the safety in treating carpal tunnel syndrome. P.-H. Wang, C.-L. Tsai, J.-S. Lee, K.-C. Wu, K.-I. Cheng, I.-M. Jou.
- Readaptation of DRUJ by ulna lengthening

- for isolated epiphyseal arrest at distal ulna. Eiko Yamabe, Toshiyasu Nakamura, Yoshiaki Toyama.
- Diffuse infiltrative epithelioid sarcoma presenting as carpal tunnel syndrome. Yang-Ki Minn, Se-Hoon Kim, Il-Nam Sunwoo.
- Flexor tendon fibroma as a cause of wrist triggering and carpal tunnel syndrome. Sang Jin Cheon, Jong Min Lim, Seung Han Cha.
- Treatment of bony mallet finger using a modified pull-out wire suture technique. Sang Jin Cheon, Jong Min Lim, Seung Han Cha.
- Granular cell tumour arising in a digital nerve. Sang Yun Ha, Yeon-Lim Suh, Chang Ohk Sung.
- Intravenous pyogenic granuloma of the finger. N. A. Johnson, J. Haeney, N. W. Yui.

## Journal of Hand Therapy

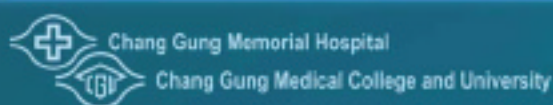
### Volume 24, Issue 1, Pages 1-78 (January-March 2011)

- Clinical Commentary in Response to: Severity of Contracture and Self-reported Disability in Patients with Dupuytren's Contracture Referred for Surgery. Tara Packham.
- The QuickDASH Score: A Patient-reported Outcome Measure for Dupuytren's Surgery. Henry R. Budd MRCS, Debbie Larson BScOT, Adrian Chojnowski FRCS(Orth), Lee Shepstone PhD.
- Using the Force-Time Curve to Determine Sincerity of Effort in People with Upper Extremity Injuries. Bhagwant Singh Sindhu PhD OTR, Orit Shectman PhD OTR/L.
- Upper Extremity Performance Test for the

- Elderly (TEMPA): Normative Data for Young Adults. Bernadette Nedelec BSc OT(c) PhD, Karyne Dion BSc, Jose A. Correa PhD, Joanne Desrosiers BSc OT(c) PhD.
- Association of Disturbances in the Thoracic Outlet in Subjects with Carpal Tunnel Syndrome: A Case-Control Study. Megan S. Vaught ScD PT, Jean-Michel Brismee ScD PT, Gregory S. Dedrick ScD PT, Phillip S. Sizer PhD PT, Steven F. Sawyer PhD PT.
- Identification of Shoulder-specific Patient Acceptable Symptom State in Patients with Rheumatic Diseases Undergoing Shoulder Surgery. Anne Christie MSc, Hanne Dagfinrud PhD, Andrew M. Garratt PhD, Hanne Ringen

- Osnes MD PhD, Kare Birger Hagen PhD.
- Early and Temporary Use of Finger Prosthetics to Aid Rehabilitation. Barbra Samph Almond MEd OTR CHT.
- Composite Flexion Splint for the Stiff Hand. Jun Wang MD, Gard Erlandsson MS OTR/L CHT, Yong jun Rul MD PhD, Xiang hong Xiu OT.
- Severity of Contracture and Self-reported Disability in Patients with Dupuytren's Contracture Referred for Surgery. Christina Jerosch-Herold DipCOT MSc PhD, Lee Shepstone BSc MSc PhD, Adrian Chojnowski MA MB BChir FRCS, Debbie Larson BSc MSc.





# 2011 CHANG GUNG MAYO CLINIC SYMPOSIUM IN RECONSTRUCTIVE SURGERY

**October 27 ~ 30, 2011**

The W Hotel and Chang Gung Linkou Medical Center, Taipei, Taiwan

## Course Directors:

*Yu-Ray Chen, M.D. Samir Mardini, M.D.*  
*Steven L. Moran, M.D. Fu-Chan Wei, M.D.*

## Highlights of the Symposium

- ☆ Live Surgery with extensive coverage of reconstructive microsurgery and craniomaxillofacial surgery for the treatment of traumatic defects, oncological defects, and congenital deformities.
- ☆ Round Table Didactic Lectures by international expert panels
- ☆ Grand Round in a unique Microsurgical Intensive Care Unit
- ☆ Medical Art Exhibition



**A Collaboration of Chang Gung University Medical College and Mayo Clinic**



## REGISTER ONLINE

Website: [www.2011cgmcsrcs.org](http://www.2011cgmcsrcs.org) E-mail: [2011cgmcsrcs@gmail.com](mailto:2011cgmcsrcs@gmail.com)



Organized by:  
Department of Plastic Surgery  
Chang Gung Memorial Hospital  
Chang Gung Medical College and University



## Welcome Message

Welcome to the 3rd symposium in reconstructive surgery co-hosted by Chang Gung Memorial Hospital and Mayo Clinic. The past 2 symposiums were both held at Mayo Clinic in Rochester, Minnesota with great success. This year, it will be held at Chang Gung Memorial Hospital in Taipei, Taiwan and aims to achieve the same level of excellence.

This year, there will be several major modifications to the format of the symposium. First, in addition to reconstructive microsurgery, the course syllabus will also cover topics in craniofacial and maxillofacial surgery. Secondly, the previous 2-day cadaver dissection course will be replaced with the 2-day interactive live surgery forum, during which a full spectrum of surgical procedures will be demonstrated. Surgeries will include reconstruction of the head and neck region, breast, upper extremity, and lower extremity, as well as facial bone fracture, cleft lip and palate, and orthognathic surgery. Thirdly, there will be microsurgical ICU grand rounds, during which the participants will be divided into groups and have the opportunity to be involved in bedside case discussion with the supervising faculty members.

The first half of the symposium will be held at Chang Gung Memorial Hospital for the interactive live surgery forum. The second half of the symposium will be based at the brand new W Hotel in the heart of Taipei city, near Taipei 101 and many other local attractions. Those who have an interest in medical illustration, the famed medical illustrator Li-min Lee will also be holding an exhibition of her work at Chang Gung Memorial Hospital for the duration of the symposium.

Please take this opportunity to visit Taiwan and participate in the 2011 Symposium in Reconstructive Surgery. I look forward to meeting you here!

Organizing Committee of 2011 CGMCSRS

# Welcome to India !

## 12<sup>th</sup> IFSSH & 9<sup>th</sup> IFSHT

4 - 8 MARCH 2013 | NEW DELHI



[www.ifssh-ifsht2013.com](http://www.ifssh-ifsht2013.com)



FOR DETAILS CONTACT

Congress Chairman **Dr. S. Raja Sabapathy**  
[rajahand@vsnl.com](mailto:rajahand@vsnl.com)

Congress Managers

**plan it!**  
by CREATIVE  
[rajigomber@travel2india.com](mailto:rajigomber@travel2india.com)

