

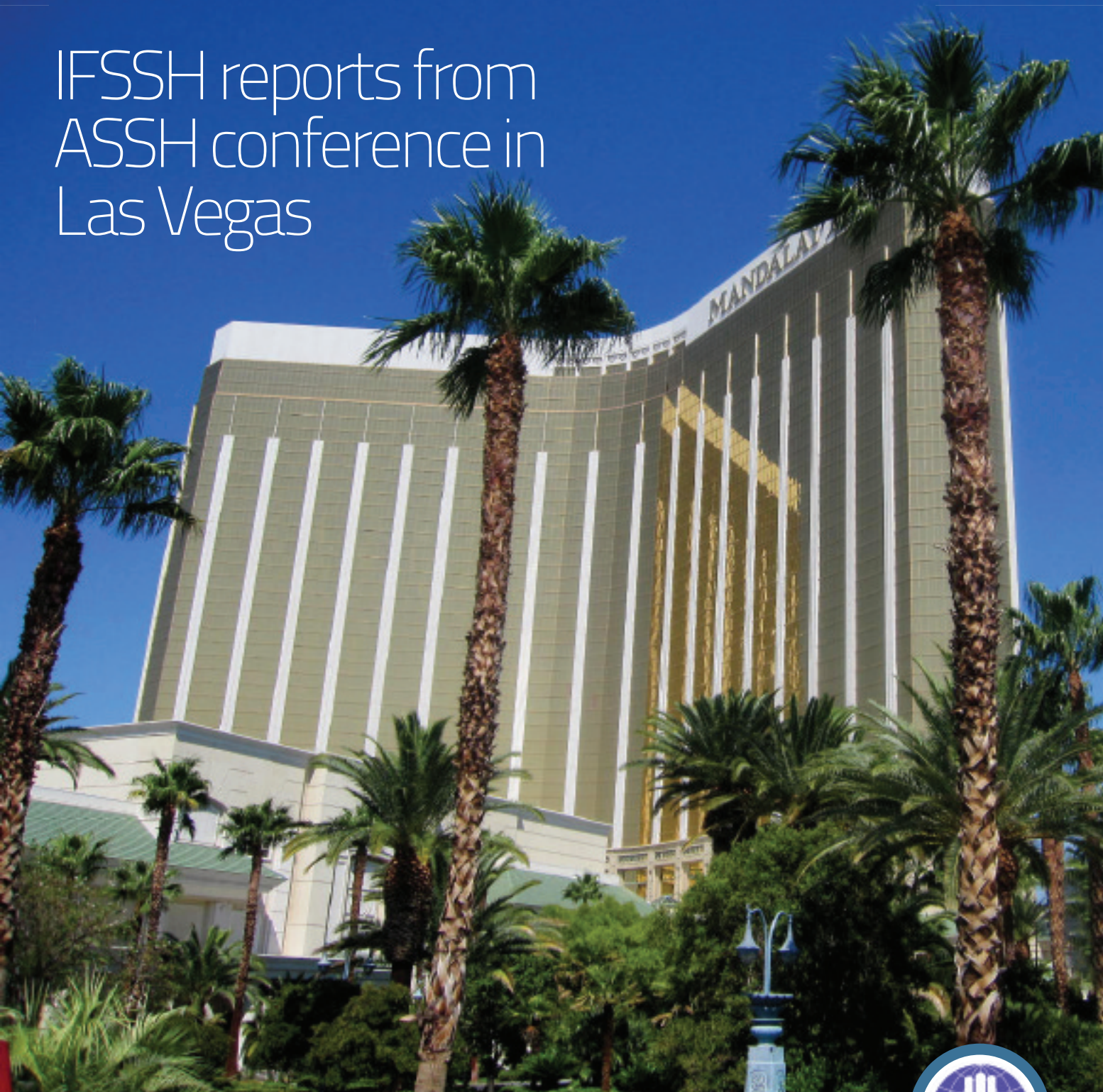ezine ifssh

CONNECTING OUR GLOBAL HAND SURGERY FAMILY

MEMBERS NEWS

- IFSSH President's report
- IFSSH Secretary-General's report
- History of the APFSSH

IFSSH reports from ASSH conference in Las Vegas



CARPAL INSTABILITY FOLLOWING
SCAPHOID FRACTURE

NEW STUDY HIGHLIGHTS
TRIARTICULAR FOREARM COMPLEX





*Because every
little thing matters*

The comprehensive hps system includes highly polished, low profile plates combined with variable angle locking, non-locking, and lag screws. In addition to a cannulated module with headless and lag screws, this system allows you to make treatment decisions based on the personality of the fracture.

800-456-7779 | osteomed.com



Rethinking Possibilities, Reshaping Lives



Contents

4 Editorial

By Professor Ulrich Mennen, editor of the IFSSH ezine

6 Members news

President's Report
Secretary General's Report
History of the APFSSH

14 Pulse

Committee report on wrist biomechanics and instability: Carpal instability following scaphoid fracture

20 IFSHT

Flexor Tendon Rehabilitation: Using the Literature to make informed decisions concerning Rehabilitation

24 Pioneer profiles

Martin Entin and William Littler

27 Case study

Scaphoid fracture conundrum

28 Research roundup

Methotrexate therapy proves to be effective in treating keloid formation
New study highlights triarticular forearm complex

31 Journal highlights

Tables of Contents from leading journals such as The American Journal of Hand Surgery, Journal of Hand Surgery Asian Volume, Journal of Hand Surgery European Volume and the Journal of Hand Therapy.

34 Upcoming events

List of global learning events and conferences for hand surgeons

Editorial

The IFSSH: its aim and relevance

When the IFSSH was formed in 1966 by the founding members, the aim and role of the IFSSH was clearly reflected in the Charter, to promote the understanding and management of hand conditions internationally by the best possible communication available.

Over the years some amendments were made to keep track with development. The Charter can be read on the IFSSH website: www.ifssh.org

A notable development has been the formation of regional Federations (European, Asian Pacific, South American and North and Central American), as well as the International Federation of Societies for Hand Therapy (IFSHT).

The IFSHT (which functions independently) and the IFSSH have a close working relationship and endeavor to hold the triennial Congresses concurrently in order to foster a closer integration of professions.

A further development is the formation of Special Interest Groups (e.g. Congenital Dysplasias, Brachial Plexus Injuries, Peripheral Nerve, Trauma, Reconstruction and Burns).

These are natural developments and are to be encouraged. The founding members would be

very pleased to see the initial vision of the IFSSH being enthusiastically fulfilled!

Although we have unique regional issues and concerns, the world has become 'smaller' due to the ease of communication, travel and desire to reach international standards.

The IFSSH plays a vital role in bringing the Hand Surgery Family together through:

1. Triennial Congress (held in various parts of the world)
2. The Scientific Committees (about 30, which produce on occasion official reports on various aspects of the Hand)
3. IFSSH ezine (electronic magazine which is sent to all who are interested in the Hand, and in doing so, distributing, amongst other information, the following worldwide:
 - Committee reports
 - Trade product announcements
 - Promoting Hand meetings
 - Anecdotes and letters
 - Case reports and problem cases
 - Indexes of published articles in major Hand Journals

IFSSH disclaimer

The IFSSH ezine is the official mouthpiece of the International Society for Surgery of the Hand. The IFSSH does not endorse the commercial advertising in this publication, nor the content or views of the contributors to the publication. Subscription to the IFSSH ezine is free of charge and the ezine is distributed on a quarterly basis. To subscribe, please [click here](#). Should you wish to support this publication through advertising, please [click here](#).



- Hand Therapy information- practical applications
- In-depth discussion with researchers
- Pioneers of Hand Surgery profiles
- 4. Educational Grants - substantial funds are available for worthy educational projects through the National Societies
- 5. IFSSH website – contains information such as committee reports, terminology of Hand Surgery, contact information, photo galleries
- 6. Interaction with Hand Therapy (IFSHT)
- 7. Standardised terms, concepts and classifications

Feel free to write to us and please send your contributions to: **ezine@ifssh.info**

The IFSSH should be run by the Members of the National Member Societies through their delegates. We want it to be truly international and representative. Your input is most important: the IFSSH belongs to its members!

Enjoy your Hand Surgery!

With sincere regards,
Ulrich



Prof. Ulrich Mennen
President: IFSSH
Editor: IFSSHazine
www.ulrichmennen.co.za

IFSSH ezine editorial team

Editor: Professor Ulrich Mennen (*President of the IFSSH*)

Deputy Editor: Professor Michael Tonkin (*President-elect of the IFSSH*)

Publication coordinator: Marita Kritzing (*Apex ezines*)

Graphic Designer: Andy Garside



IFSSH Secretary General's report

September 2011, Las Vegas, USA

I cannot start my report without recapping the wonderful year of 2010. The work of the last three-year term, led by IFSSH President Jim Urbaniak and Secretary-General Michael Tonkin, was perfectly completed by an outstanding 11th IFSSH triennial Congress in November 2010 in Seoul, South Korea. This was superbly organised by Congress President Moon Sang Chung and a high scientific standard was ensured by Goo Hyun Baek, the Scientific Chairman. These programmes made for an unforgettable event and, along with the financial outcome of the congress, will be difficult for future congresses to equal.

1501 participants, including more than 1300 surgeons from 61 countries met in Seoul to take part in the Congress. 1429 oral and poster abstracts were presented, covering a wide range of topics. Dr Jesse Jupiter delivered the Swanson Lecture: "Fracture of the distal radius: an historical perspective".

Executive Committee

During the Seoul Congress new IFSSH officers were elected:

President: Ulrich Mennen

President-Elect: Michael Tonkin

Past-President: James Urbaniak

Secretary General: Zsolt Szabo

Secretary General Elect: Marc Garcia-Elias

Historian: Frank Burke

Member-at-Large (Nominating

Committee): Goo Hyun Baek

We thank Arlindo Pardini and Bill Cooney for their contribution to the IFSSH Executive over the past terms.

IFSSH Member Nations

The IFSSH family welcomed a new member, the Georgian Hand Surgery Branch of Medical Foundation "Mkurnali". We look forward to having Georgian representatives join us at future Congresses. Interest in membership has been forthcoming from many other societies, including Estonia, Latvia, Ireland, Guatemala and

Myanmar and we hope to welcome these societies to IFSSH membership at future meetings. Important steps are in place in order to strengthen our relations with our Russian colleagues. The President and Secretary General of the IFSSH participated in a scientific cadaver course in St Petersburg during September 2011, at the invitation of the Russian Society.

Hand Surgery Worldwide

A remarkable outcome of the Congress was the presentation of the book *Hand Surgery Worldwide: International Reconstruction of a "Beautiful and Ready Instrument of the Mind"*, edited by outgoing IFSSH President Jim Urbaniak.

Ezine

Thanks to its President, Ulrich Mennen, in February 2011 the IFSSH started a new era in information and communication. This electronic

magazine, called 'ezine', developed and edited by Ulrich Mennen, plans to improve communication between IFSSH members and co-workers. The outstanding quality and content of the first three issues assure us that it will be an important tool in our aim to build a stronger hand surgery community. If you wish to receive this, or have contributions or suggestions, please email ezine@ifssh.info.

Pioneers of Hand Surgery

During the 2010 Seoul IFSSH Congress opening ceremony, 28 "Pioneers in Hand Surgery" were honoured. This is a long standing custom which dates back to the 3rd Congress in Tokyo held in 1986. The IFSSH, on behalf its members, congratulates the following Pioneers on their award:

Alessandro Caroli (Italian Society for Surgery of the Hand)
 André Chamay (Swiss Society for Surgery of the Hand)
 John Cobbett (British Society for Surgery of the Hand)
 Fernando Enriquez de Salamanca Lorente (Spanish Society for Surgery of the Hand)
 José Cantero Martínez (Spanish Society for Surgery of the Hand)
 Antonio De Santolo Ricciardelli (Venezuela Society for Surgery of the Hand)

Richard G. Eaton (American Society for Surgery of the Hand)
 Joel Engel (Israeli Society for Surgery of the Hand)
 David P. Green (American Society for Surgery of the Hand)
 Basil Helal (British Society for Surgery of the Hand)
 Yoshikazu Ikuta (Japanese Society for Surgery of the Hand)
 Seiichi Ishii (Japanese Society for Surgery of the Hand)
 Eung-Shick Kang (Korean Society for Surgery of the Hand)
 Ik-Dong Kim (Korean Society for Surgery of the Hand)
 Young Ho Lee (Korean Society for Surgery of the Hand)
 Ralph Manktelow (MANUS Canada)
 Renzo Mantero (Italian Society for Surgery of the Hand)
 Viktor E. Meyer (Swiss Society for Surgery of the Hand)
 Edward A. Nalebuff (American Society for Surgery of the Hand)
 Santos Palazzi Coll (Spanish Society for Surgery of the Hand)
 Alfredo Quintana Montero (Spanish Society for Surgery of the Hand)
 Morton Spinner (American Society for Surgery of the Hand)
 James W. Strickland (American Society for Surgery of the Hand)
 Philip Sykes (British Society for Surgery of the Hand)

"Their vast offerings assist the hand surgeons of today and ultimately benefit innumerable patients"

Julio Taleisnik (American Society for Surgery of the Hand)
 E.F. Shaw Wilgis (American Society for Surgery of the Hand)
 Virchel E. Wood (American Society for Surgery of the Hand)
 Elvin G. Zook (American Association for Hand Surgery)

These Pioneers have contributed to our knowledge and understanding of Hand Surgery, both within their own countries and internationally. Their vast offerings assist the hand surgeons of today and ultimately benefit innumerable patients. We thank the Pioneers for their dedication to enriching the field of hand surgery.

Finances

A detailed Treasurer's report will follow, but we should state that the financial standing of the IFSSH is increasing. This is first of all due to the fantastic financial success of the Seoul Congress. We have to thank the Korean organisers for the impressive amount of US\$100,000 transferred to our account. Improved diligence of our member nations to pay annual dues, along with a good control of expenses, have contributed to this successful growth.

Bursaries and Grants

The IFSSH Executive and Delegates' Council Meeting have provided a further bursary to support the Baragwanath Hand Fellowship, under the guidance of Prof John Fleming in South Africa. Reports of previous Fellows of the Baragwanath Hospital are available on the IFSSH website (www.ifssh.info).

Bursaries and grants are available for worthy projects that fulfil the criteria for the use of IFSSH funds. All member societies are welcome to submit proposals to apply for a bursary or congress assistance grant. The guidelines and criteria can be found on the website. Applications should be submitted to the Secretary-General (secretary@ifssh.info) for consideration by the Executive Committee.

IFSSH website

The IFSSH website is continually updated with society details. We must thank our Indian friends, Raja Sabapathy and Santhosh Rajan, who are the providers and webmasters of our website. If your society wishes to place details of its annual meeting on this website, please also inform the secretariat (administration@ifssh.info) and include details of the dates, location and website/email for enquiries.

IFSSH Congresses

At the Delegates' Council meeting held in Seoul, the hosting rights for the 2016 IFSSH Congress were awarded to Argentina. The regional rotation system of host societies will now take effect, commencing with the bids for the 2019 Congress to come from the European region.

XIIth IFSSH - IXth IFSHT Congress - New

Delhi, India - 4th-8th March, 2013

XIIIth IFSSH - Xth IFSHT Congress -

Buenos Aires, Argentina - 2016

2012 Delegates' Council Meeting

The 2012 IFSSH Delegates' Council meeting is planned to be held in conjunction with the annual congress of the Federation of Societies for Surgery of the Hand (FESSH) in Antwerp, Belgium on 21-23 June.

Further details will be provided in due time for travel and accommodation arrangements.

Finally I would like to thank our permanent administrative secretary, Ms Belinda Smith, for the impressive amount of work and its high professional standard, and with whom I have a perfect collaboration and she has facilitated a lot of my activity. Also I wish to express my thanks for the support and collaboration of our President, Ulrich Mennen.



Zsolt Szabo

*Secretary General,
IFSSH*

IFSSH President's report

Delegates' Council Meeting, September 2011, Las Vegas, USA

Since our last Congress in November 2010 in Seoul, Korea, a number of significant changes have taken place in the running of the IFSSH. Firstly, Dr Zsolt Szabo has taken over as Secretary-General. I am very privileged to work with Dr Szabo, an enthusiastic and energetic organizer who keeps this organization in ship shape.

Secondly, the IFSSH has acquired the experienced and able services of Ms Belinda Smith as the permanent Administrator. This enables the IFSSH to have a 'central' office, ensures continuity with an ever changing ExCo and Delegates Council, makes the task of each officer so much easier and serves to keep records and ongoing administration updated.

Thirdly, the IFSSH ezine, the IFSSH electronic turning-page magazine, has been launched in February 2011, and will be sent out every 3 months, free of charge, to all subscribers and National Delegates. The third issue was dispatched in August to some 4500 individuals directly, and about 2-3000 more indirectly through the Delegates. We encourage the Delegates to please send us the individual members email addresses. This will help us to dispatch

the ezine directly to all Members of the IFSSH community. Those who wish not to receive the ezine can unsubscribe. Santhosh Rajan, the IFSSH Webmaster, has added a link on the IFSSH Website, which gives access to all previous ezines. We urge you to send your comments, letters, contributions, photographs and interesting case studies for publication. The IFSSH ezine is a publication for the IFSSH and IFSHT and should be 'fueled' by the Members. The aim of the ezine is to bring the Hand Surgery and Hand Therapy family closer together and optimize communication.

Fourthly, the Committee system and their reports. In the past, most of the 30 Committees of the IFSSH

have not been very functional and the number of reports presented at the triennial Congresses were only in single figures and poorly attended. Also, the work which went into some of these reports was seldom acknowledged or available to the Membership.

The President has the responsibility to solicit these reports from the appointed Committees. Again, in the past the response was mostly unsatisfactory and often very frustrating. In an attempt to overcome this tardy response, Past-President James Urbaniak managed to solicit reports from Members who represented all the IFSSH National Societies. These reports were published in the magnificent book entitled: "Hand Surgery Worldwide" President-Elect Michael Tonkin and I have decided to review the IFSSH Committee system and submit proposals to the ExCo for discussion. The new guidelines will be published in the next IFSSHezine.

Submitted with sincere regards

Ulrich Mennen

President: IFSSH

Editor: IFSSHezine



"Since our last Congress in November 2010 in Seoul, Korea, a number of significant changes have taken place in the running of the IFSSH"

History of the Asian-Pacific Federation of Societies for Surgery of the Hand

by **Michael Tonkin** and **Moroe Beppu**

The discussions which finally led to the formation of the Asian-Pacific Federation of Societies for Surgery of the Hand (APFSSH) were conducted in Hong Kong on 30 April and 1 May 1994. Representatives of the founding societies, except India, were present at these meetings during which the name of the Federation and its objectives were established. A tentative structure was established with the Delegates' Council, consisting of representatives from each prospective member society, and an acting Executive Committee, with appointments to be confirmed at a the next official Council meeting when individual member societies had accepted a formal invitation to join the Federation.

The decision to establish the Federation and the recommendations of the discussion group in Hong Kong were born of a prolonged gestational period, and as early as 1979, Dr BB Joshi from India organised an "Afro-Asian Hand Meeting" and advocated the development of a regional hand surgery group. He may not have been the first to suggest this. Regrettably, APFSSH archives do not provide a detailed and precise history of all those who contributed to the development of a regional Federation.

The Western Pacific Orthopaedic Association was established in 1962, changing its name to the Asia-Pacific Orthopaedic Association in 2000. Within this association was a hand surgery group. This could be considered as the forerunner of the current Federation. In late 1990, Michael Tonkin from Australia wrote to Asian-Pacific member societies of the International Federation of Societies for Surgery of the Hand (IFSSH), advocating the formation of a regional Federation. By this time the European Federation of Societies for Surgery of the Hand (FESSH) had been established, following preliminary meetings in 1989 when a draft constitution was agreed upon and subsequently adopted in Paris on 11 February, 1990.

The largest of the IFSSH member societies was the American Society for Surgery of the Hand (ASSH), which was closely aligned geographically with Canada and the South American countries. It appeared appropriate for the Asian-Pacific countries to align as they formed a natural geographic region. Some considered that the effective function of such a Federation would be very difficult because of budgetary, geographical and cultural differences amongst the probable

constituent societies. These were also problems which confronted the European societies when establishing the European Federation.

Robert Pho from Singapore and Tatsuya Tajima from Japan communicated regarding the structure of a regional group, its name and its probable membership. Discussions continued at the IFSSH Paris meeting in 1992 and subsequently the 1994 Hong Kong discussion was organised at a Western Pacific regional education hand surgery programme, conducted by the Hong Kong Society for Surgery of the Hand with the encouragement of the IFSSH, who had appointed Tatsuya Tajima as the Chairman of the Western Pacific Regional Education Programme.

The APFSSH acting Executive Committee formed at that meeting consisted of President Tatsuya Tajima (Japan), Vice-President (President-Elect) Wayne Morrison (Australia), Treasurer Timothy So (Hong Kong) and Secretary Lam-Chuan Teoh (Singapore). Lam-Chuan Teoh, with the other members of the Executive Committee drafted an invitation to societies of the region. They established a Charter for consideration of adoption at a Council meeting to be held in Singapore on 19 and 20 January, 1995. At this meeting

APFSSH

Asian Pacific Federation of Societies for Surgery of the Hand



an amended Charter was adopted by the foundation society members and the members of the acting executive council were confirmed in their positions.

The founding APFSSH societies were those from Australia, Hong Kong, India, Indonesia, Japan, Korea (two societies), Malaysia, New Zealand, Philippines, Singapore, Taiwan and Thailand. The objective of the Federation as defined in the Charter:

Article II – Objective

This organization is formed for the purpose of promoting the practice of hand surgery and coordinating the activities of the various societies for surgery of the hand in the Asia-Pacific region. Its main purposes shall be:

- (1) to maintain liaison and communication between the various societies,
- (2) to promote the free exchange of knowledge amongst constituent societies,
- (3) to enhance the opportunity of hand surgery training through friendly exchange programs,
- (4) to disseminate knowledge through publications,
- (5) to enhance teaching by organizing scientific meetings and regional instructional courses.

Amendments to the Charter, adopted in 1995, were accepted in August 2000 at the 4th Council Meeting in Chennai, India.

The first APFSSH Congress was conducted in Perth, Australia, in March 1997 with Mark Allison and Michael Tonkin as convenors, Bruce Conolly as the President of the Australian Hand Surgery Society and Tatsuya Tajima as the inaugural APFSSH President. Subsequent congresses have been conducted in Singapore, Chennai, Seoul, Osaka, Bangkok, Hong Kong and Kaoshiung, with the next congress to be hosted by the Indonesian Society in Bali in October 2012 with Drs Suroto

and Ramawan as convenors and Bruce Conolly as APFSSH President.

The Tajima Lecture was established in 2004 to recognise the contribution to hand surgery of the inaugural APFSSH President, Tatsuya Tajima from Japan. The current APFSSH President has the responsibility of nominating the Tajima Lecturer for each Congress. Those who have been honoured by this invitation are SP Chow (Osaka, 2004), Michael Tonkin (Bangkok, 2006), Yu-Dong Gu (Hong Kong, 2008) and Yoshikazu Ikuta (Kaoshiung, 2009).

Hand Surgery, the official journal of the APFSSH has developed in parallel

Date	Location	President
March 1997	Perth, Australia	Tatsuya Tajima
February 1999	Singapore	Wayne Morrison
August 2000	Chennai, India	Susumu Tamai
March 2002	Seoul, South Korea	Lam-Chuan Teoh
November 2005	Osaka, Japan	Michael Tonkin
November 2006	Bangkok, Thailand	Kwan-Chul Tark
February 2008	Hong Kong	SP Chow
November 2009	Kaoshiung, Taiwan	Panupan Songcharoen

with the Federation. The first volume was published in January 1996 under the guidance of Editor-in-Chief SP Chow from Hong Kong, who could be considered as the 'father' of the journal. SP Chow attracted funding from a colleague in the business world and negotiated with World Scientific Publishing in Singapore to produce Hand Surgery under financial arrangements which were feasible for a fledgling Federation.

The Editorial office moved from Hong Kong to Japan, under the direction of Yoshikazu Ikuta (2003-2009) and subsequently with Akio Minami as the Editor-in-Chief. Michael Tonkin (Australia) and Moroe Beppu

(Japan) have assisted the editorial office as co-Editors. Three issues of the journal are now published yearly, with the intention of moving to four. Subscription numbers in 2011 are over 1200. The development of this journal has been a significant task, the brunt of which was borne by the Hong Kong Society initially and now by the Japanese Society. Well established, it is a forum for the publication of the work emanating from the Asian-Pacific region, not yet matching the standards of the European and American journals of Hand Surgery but rapidly improving in quality and sophistication.

In November 2009, at the Kaoshiung APFSSH Congress, an

APFSSH Travelling Fellowship Scheme Management Committee was appointed with a view to establishing an APFSSH Visiting Professorship and APFSSH Travelling Fellowships. These developments, and others, are a part of the next chapter of the history of hand surgery in the Asian-Pacific region, which includes increasing the number of member societies in the Federation.

*Current President: **W. Bruce Conolly***

President-Elect: Moroe Beppu

Next congress: October 2012, Bali

apfssh2012.org

www.apfssh.org

St. Petersburg opens its arms to hand surgery training event

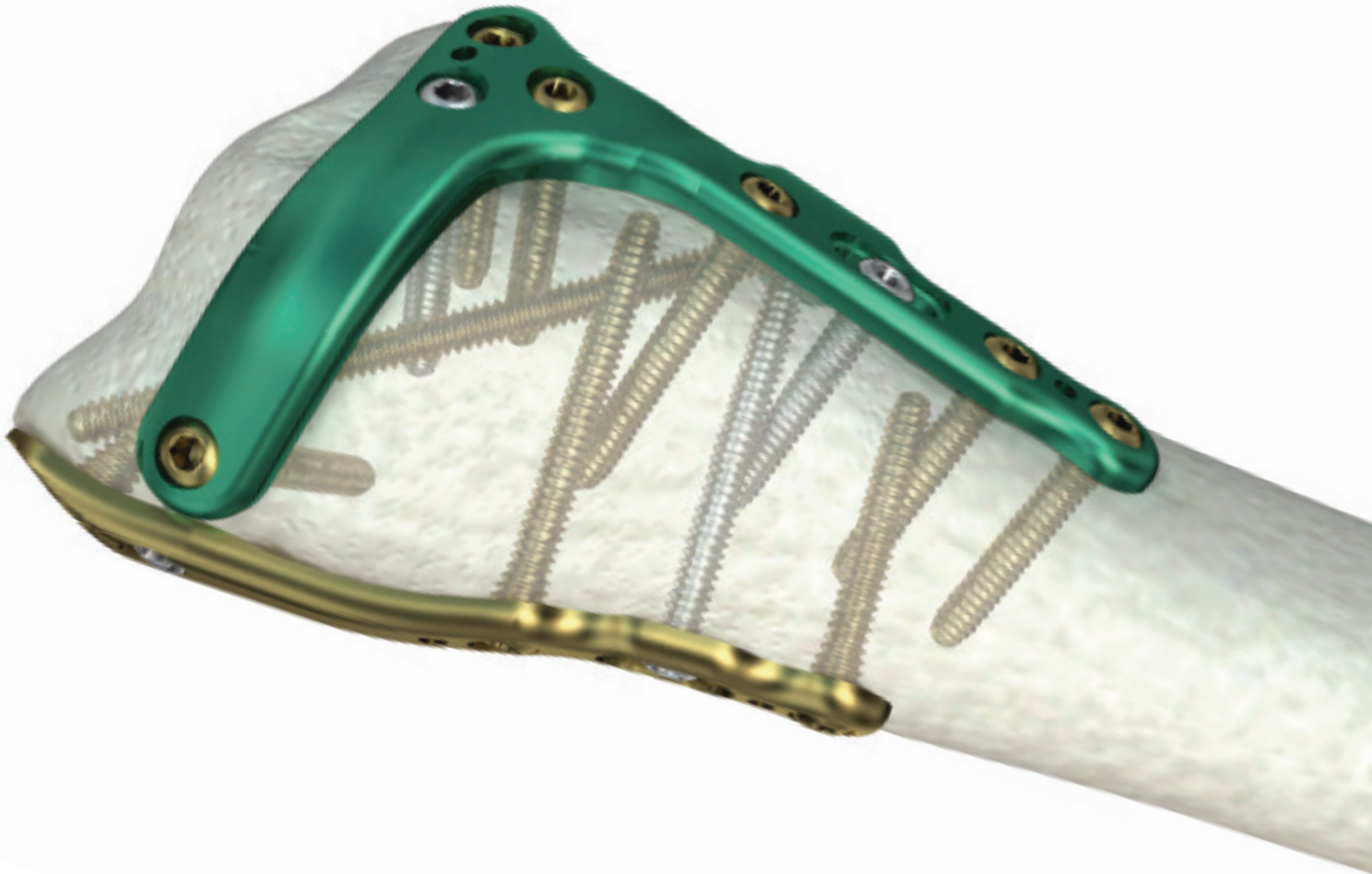


On 14-16 September 2011 an Instructional Course was held entitled "Topical issues of Hand Surgery" at the St. Petersburg Orthopaedic Institute (1200 beds) under the Directorship of Professor J Kocsis.

Professor Igor Golobev, President of the Russian Society for Surgery of the Hand, was responsible for organising the

course and the IFSSH was invited to participate in this event. President Ulrich Mennen and Secretary-General Zsolt Szabo presented some of the lectures and demonstrated surgical procedures in the very well-equipped Department of Anatomy. A group of 150 hand surgeons from around Russia attended this course.

Customizable Approach, Streamlined Surgery. The latest in fragment specific plating technology.



The Acumed® Distal Radius Fragment Specific Plating System.

Fragment specific plating is based on the three column theory that separates the ulnar and radial sides of the distal radius from the distal ulna.

The placement of two distal radius plates increases stability and addresses challenging complex fractures where a single plate may not be adequate. Additionally, the modular nature of the plates allows fixation of fracture fragments from multiple directions to create a rigid construct.



[View Acu-Loc 2
Technique](#)



[Download
Brochure](#)



[Visit Our
Website](#)



[Contact Us](#)

For more in depth product information including interactive 3D models visit
www.acumed.net • (888) 627-9957

ACUMED®

Committee report on wrist biomechanics and instability

Carpal instability following scaphoid fracture

Hisao Moritomo (Chairman)

Members : Emmanuel Apergis ; Guillaume Herzberg ; Scott Wolfe ; Jose Maria Rotella ; Marc Garcia-Elias

Scaphoid fractures generally progress to a certain type of carpal instability, i.e. DISI, if the fracture was not appropriately treated and turned to nonunion. Usually such instability produces incongruity between carpal bones followed by synovitis, becomes painful within a few years, and often requires surgical treatment in due course. However, it is also true that some types of scaphoid fractures are less symptomatic and often

left untreated. Long after fracture around more than ten years, fracture nonunion becomes symptomatic and radiographic examination reveals massive osteophytes formation around the scaphoid. Moreover, despite the long duration after injury, we often encounter cases without severe DISI deformity.

Recent 3-dimensional analysis of scaphoid nonunion has revealed that carpal instability following scaphoid

nonunion is closely related to whether the fracture line passes distal or proximal to the scaphoid apex. The scaphoid apex, which is the most dorsal and ulnar nonarticulating part of the scaphoid¹, where the dorsal scapholunate interosseous ligament and the proximal fiber of the dorsal intercarpal ligament attach. In their article, there were two clear patterns of the interfragmentary motions of the scaphoid based on the fracture location. In the unstable (mobile) type scaphoid nonunion, the fracture was located distal to the scaphoid apex, and the distal scaphoid was unstable relative to the proximal scaphoid. In the stable type scaphoid nonunion, the fracture was located proximal to the scaphoid apex, and the interfragmentary motion was considerably less than with the distal type.

Through several researches investigating scaphoid nonunions 3-dimensionally^{1, 3-5}, I have noticed that for ordinary clinician, judgments of fracture locations using 2-dimensional and conventional x-rays were often inaccurate when compared to judgments using 3-dimensional CT images. For example, figure 1 shows two

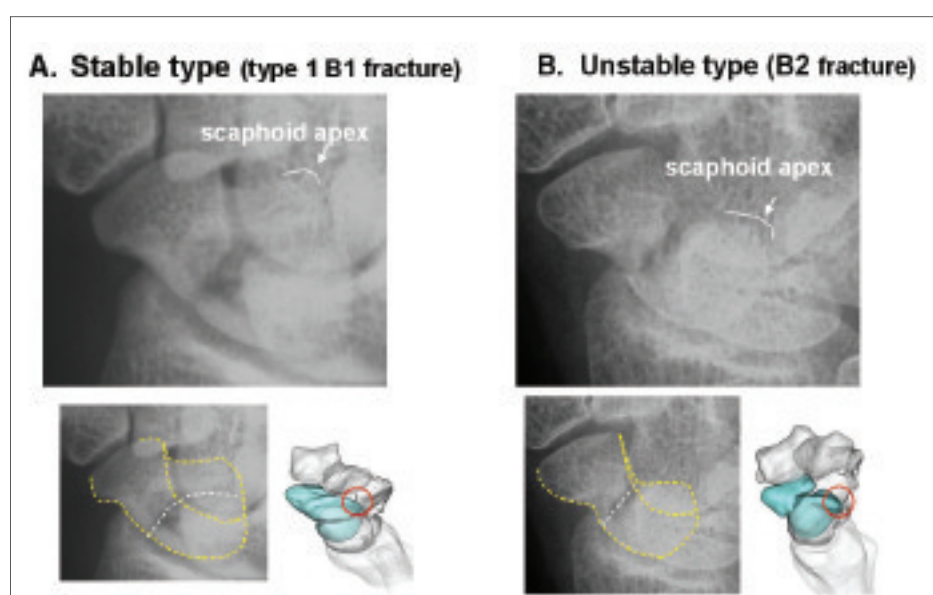


Figure 1: Oblique view X-ray and 3-D images of two patients with A) type 1 B1 and B) B2 scaphoid nonunion. Despite relationships between fracture line and the scaphoid apex are completely different, fracture lines on the scaphoid body on the x-ray look similar.

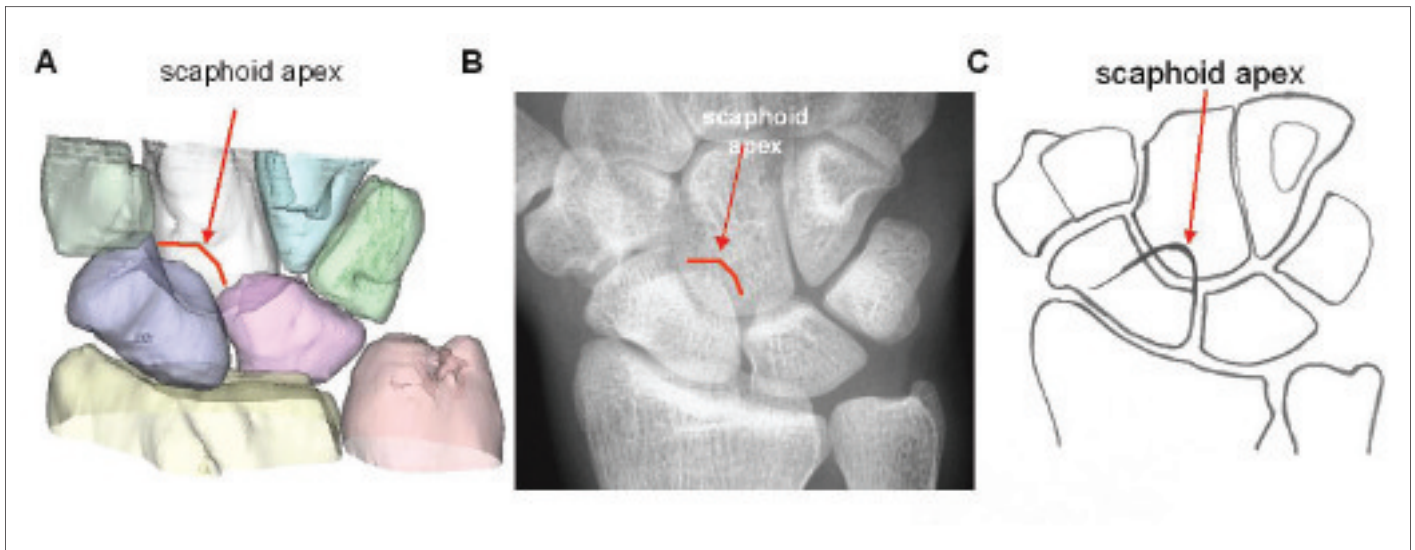


Figure 2: Contour of the scaphoid apex. Note the scaphoid apex superimposes on the capitate.

types scaphoid nonunions; On the left, 3-D image shows that stable fracture (type 1 B1 fracture) has its fracture line proximal to the scaphoid apex. On the right, unstable fracture (B2 fracture) has its fracture line distal to the scaphoid apex. Despite relationships between fracture line and the scaphoid apex are totally deferent from each other, fracture lines on the scaphoid waist on the x-ray look very similar. I believe that many people would easily misdiagnose fracture type unless they focus on the scaphoid apex. One of the reasons is super-imposition of the scaphoid apex on the capitate (Fig. 2). It seems that most people do not see the contour of the scaphoid apex on x-rays; that's why it is difficult to recognise the fracture location 3-dimensionally. I believe that recognising the scaphoid apex on x-ray is very important clinically for people to judge fracture type, to predict its natural history, and to choose proper treatment.

What we want to clarify is that there are two types of a mid-third fracture, which are 1. Type 1 B1 (distal oblique

"Recent 3-dimenssional analysis of scaphoid nonunion has revealed that carpal instability following scaphoid nonunion is closely related to whether the fracture line passes distal or proximal to the scaphoid apex"

fracture) and 2. B2 (complete waist fracture). Both fractures have a similar fracture location at the palmar side but a different fracture location at the dorsal side. Type 1 B1 fracture is not a proximal third fracture but a fracture that could be categorised as a mid-third fracture because its fracture line passes through the palmar waist of the scaphoid. In the current committee report, I would like suggest mainly 2 points; 1. how to diagnose fracture type using x-rays whether stable or unstable, and 2. recommended treatment option for each type.

1. How to diagnose fracture types using x-rays

There are at least two radiographic tips to judge if fracture is stable or mobile. First, on the semi-pronated oblique view x-ray (Fig. 1), after recognising the outline of the scaphoid apex, which is seen around the capitate head, stable or unstable fracture can be judged as present when the fracture line passes distal or proximal to the scaphoid apex,

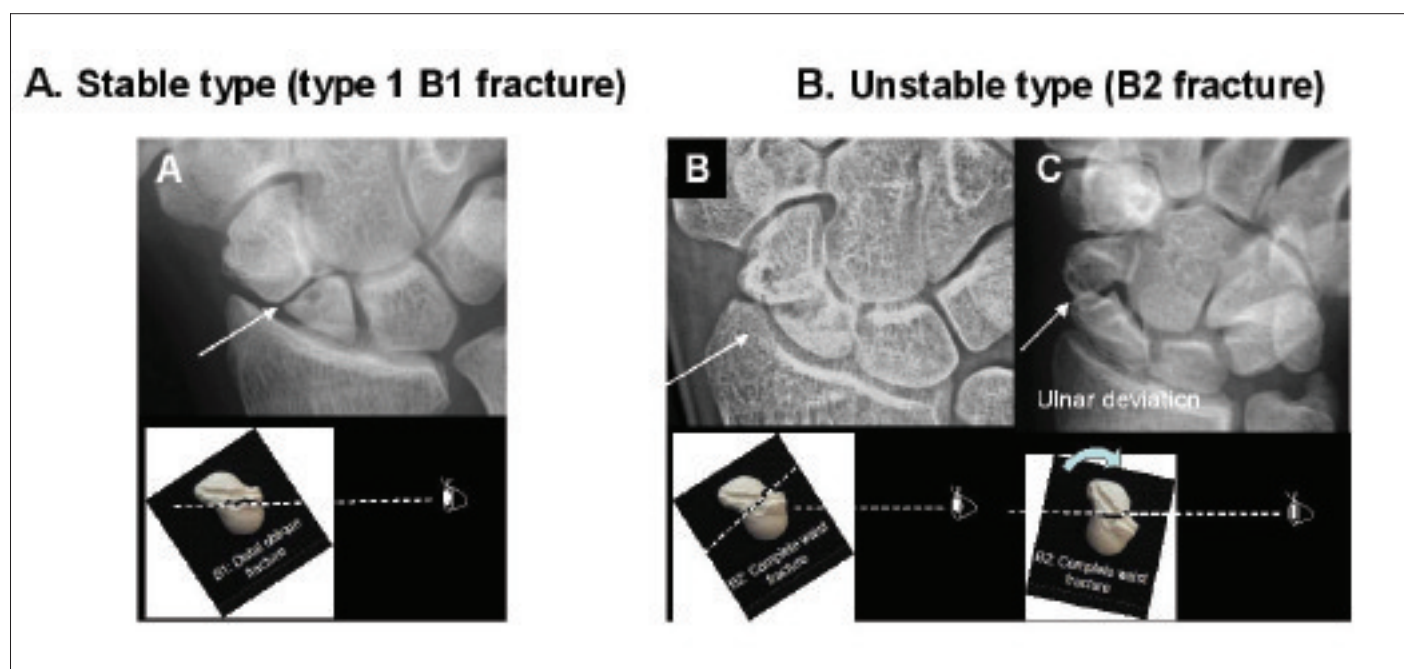


Figure 3: P-A view. A) In Type 1 B1 (stable fracture), fracture line usually is seen clearly because fracture line runs almost parallel to the X-ray beam. B) and C) In B2 (mobile fracture), fracture line is not often visible in neutral position because fracture line runs obliquely relative to the x-ray beam. In a P-A view with ulnar deviated position, however, fracture line becomes visible because scaphoid rotates dorsally.

“When symptom is brought only by osteophyte impingement, resection of osteophyte with styloidectomy would be enough, especially in elderly”

respectively. Second, stable fracture can be considered present when the fracture line is clearly visible on the P-A view with the wrist in neutral position (Fig. 3A). In Type 1 B1 (stable fracture), fracture line usually is seen clearly because fracture line runs almost parallel to the x-ray beam. In B2 (unstable fracture), fracture line is not often visible in neutral position because fracture line runs obliquely relative to the x-ray beam (Fig. 3B). In a P-A view with ulnar deviated position, however, fracture line becomes visible because scaphoid rotates dorsally and fracture line becomes parallel to the x-ray beam (Fig. 3C).

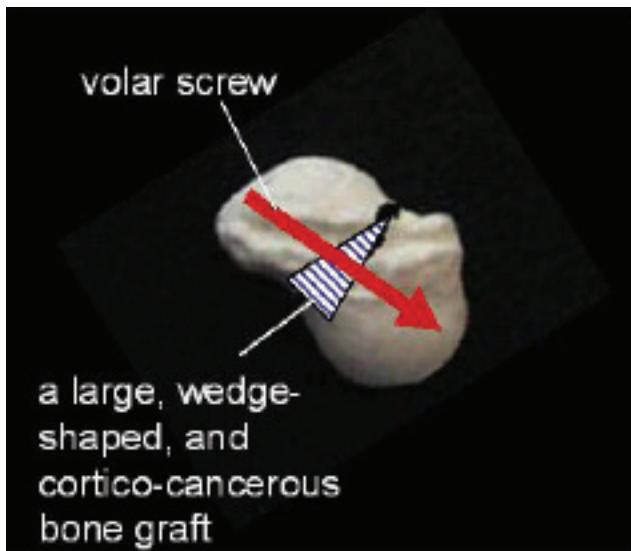
2. Appropriate treatment option for each stable and unstable scaphoid nonunion (Table 1)

Stable fractures essentially do not alter the equilibrium of forces between

the scaphoid and the lunate. Because wrist stability is not at risk, the bone defect should be smaller, and the patient should have fewer symptoms. Degenerative change develops slowly with massive osteophyte formation. When symptom is brought only by osteophyte impingement, resection of osteophyte with styloidectomy would be enough, especially in elderly. When the patient is young, ORIF with bone graft is applied. As fracture line runs transversely from volar to dorsal, volar screw risk eccentric placement in the proximal fragment with very few of the screws across the fracture line. Dorsal screw with small cancellous bone graft would be preferable even if the proximal fragment is relatively big because resection of dorsal osteophyte is often necessary.

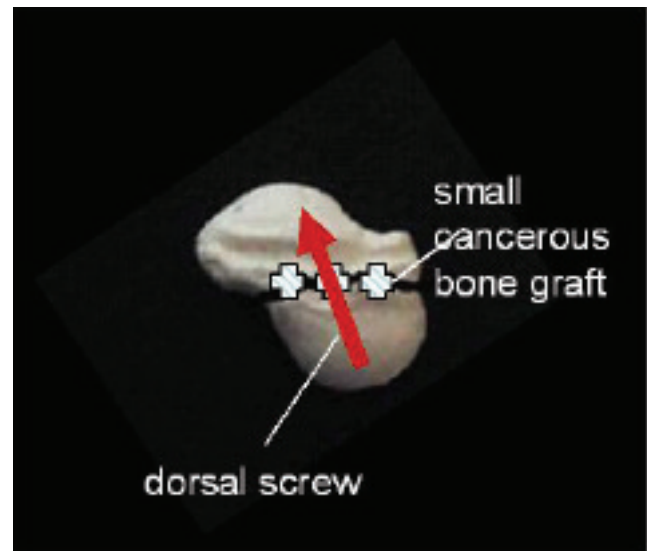
In unstable fracture, a humpback deformity of the scaphoid and a DISI

Unstable (mobile type)



- A humpback and a DISI deformity predominantly occurs.
- Very painful with large bone defect.
- Volar screw with a large wedge-shaped, and cortico-cancellous bone graft would be appropriate.

Stable type



- Do not alter the equilibrium of forces between the scaphoid and the lunate.
- The bone defect should be smaller with fewer symptoms.
- Styloidectomy and/or dorsal screw with small cancellous bone graft would be appropriate

Table 1: Comparison of pathology and recommended treatment for unstable and stable scaphoid nonunion.

deformity almost always occur because fractures distal to the insertion of the proximal fiber of the dorsal intercarpal ligament and the dorsal scapholunate interosseous ligament are destabilised and this allows the distal fragment to flex and the proximal fragment to extend creating a large bone defect. Pain is severe and bone defect develops rapidly. Therefore, immediate volar screw with a large, wedge-shaped, and cortico-cancellous bone graft would be appropriate regardless of age.

References

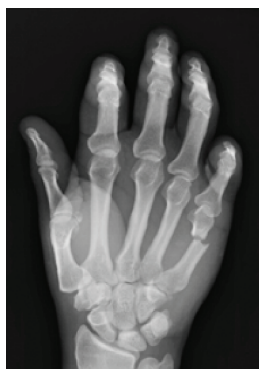1. Relationship between the fracture location and the kinematic pattern in scaphoid nonunion.
2. Moritomo H, Murase T, Oka K, Tanaka H, Yoshikawa H, Sugamoto K. *J Hand Surg [Am]*. 2008 Nov;33(9):1459-68.
3. Garcia-Elias M, Lluch A. Partial excision of scaphoid: is it ever indicated? *Hand Clin* 2001;17:687-95.
4. Patterns of bone defect in scaphoid nonunion: a 3-dimensional and quantitative analysis. Oka K, Murase T, Moritomo H, Goto A, Sugamoto K, Yoshikawa H. *J Hand Surg [Am]*. 30(2):359-65, 2005.
5. Does Three-dimensional Computer Simulation Improve Results of Scaphoid Nonunion Surgery? Murase T, Moritomo H, Goto A, Sugamoto K, Yoshikawa H. *Clin Orthop Relat Res*. 434:143-150, 2005.
6. Patterns of carpal deformity in scaphoid nonunion: a 3-dimensional and quantitative analysis. Oka K, Moritomo H, Murase T, Goto A, Sugamoto K, Yoshikawa H. *J Hand Surg [Am]*. 30A: 1136-1144, 2005.
7. Scaphoid nonunions: A 3-dimensional analysis of patterns of deformity. Moritomo, H., Viegas, S.F., Elder, K.W., Nakamura, K., DaSilva, M.F., Boyd, N.L., Patterson, R.M. *J Hand Surg*, 25A:520-528, 2000.



FRACTURE FIXATION USING A NOVEL SUBCONDYLAR PLATE

Preparation

1. Expose and Reduce Fracture or Osteotomy Site.



Instrumentation Tip: Instrumentation is provided to aid in bone and soft tissue manipulation, including 3 different Bone Clamps, Hohmann Retractors, Periosteal Elevators and a Sharp Hook.

Plate Preparation and Positioning


2. Select plate

Select the appropriate subcondylar plate size:
1.6mm, 2.0mm, 2.4mm.



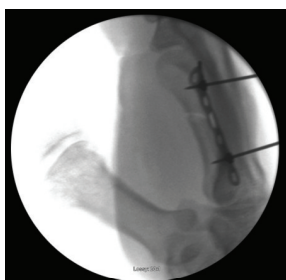3. Cut & Contour Plate

The plates may be cut using the Universal Plate Cutter and further contoured using the plate bender.



4. Position plate

Position the plate proximal to the condyle. The plate has a 12-degree bend that allows the screws to be placed at broader angles in order to fixate the fracture. Use fluoroscopy to check correct positioning.

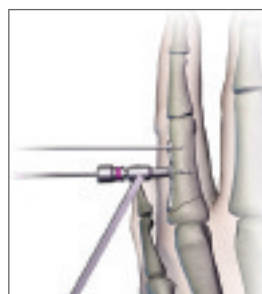


Instrumentation Tip: Utilize the Plate Holding Taks, Plate Holding Forceps or On Bone Plate Holders to help position and stabilize the plate onto the bone.

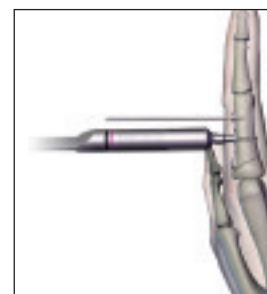
***For complete surgical technique and instrument instructions, see the Surgical Technique Guide and Instructions For Use**

(If using a cannulated screw please see the inset in the next page)

5. Drill & Measure



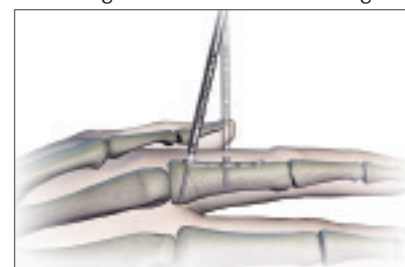
Drill



Measure

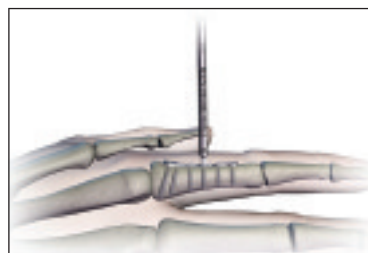
6. Insert screw

Select the desired Non-locking Screw diameter and length accordingly. Verify the screw length with gauge on block. Insert the screw into the positioning hole at the desired angle to fixate the plate onto the bone, but do not engage screw head with plate until metaphysis screws are placed.



7. Additional screw placement

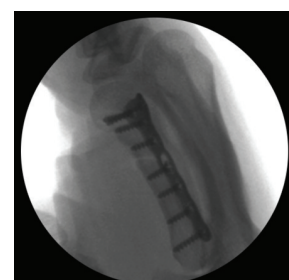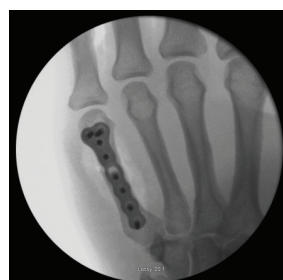Repeat steps 5 & 6 for screw placement at the metaphysis, followed by the shaft, until all the holes are filled. Angled Locking, Non locking and Lag screws may be used. Locking angle of the screws are controlled by the drill guide.



8. Fully seat screw in positioning hole

Closure

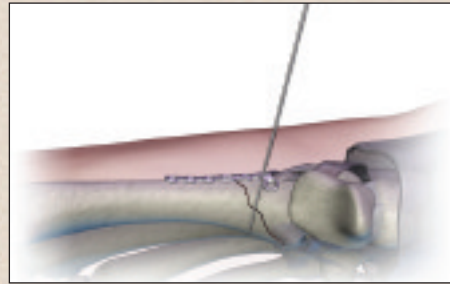
9. Close the treatment site using standard closure techniques.



If using a Cannulated Lag screw through a plate, it must be inserted first before any other screw. Only one Cannulated Lag screw can be used per plate. Follow steps 1-4 on the previous page. Then place your cannulated screw following steps A-E.

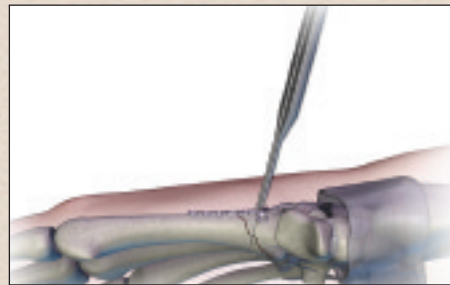
A. Insert K-wire

Insert the .035" K-wire through the center of the desired hole, perpendicular to the fracture. The 1.2mm Drill Guide for the 1.0mm Pilot Drill can be used as a K-wire guide.



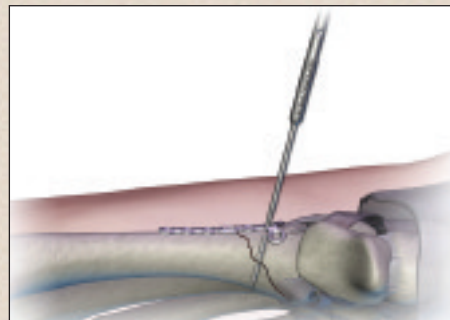
B. Measure

Slide the Cannulated Depth Gauge over the K-wire until the tip bottoms out on the plate; the end of the K-wire will indicate the screw length required.



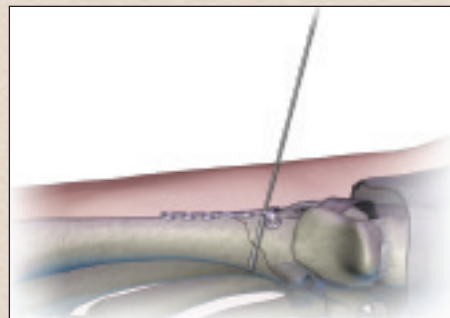
C. Drill

HPS Cannulated Screws are self drilling and self tapping, but drilling is recommended in cases of dense bone.



D. Insert screw

Select the diameter and length of the screw. Insert the cannulated screw over the K-wire through the plate hole to fixate the plate onto the bone and compress the fracture. Remove and discard the K-wire.



E. Continue with Step 7 for remaining screws



IFSHHT: Hand Therapy

Flexor Tendon Rehabilitation: Using the Literature to make informed decisions concerning Rehabilitation

Rebecca L. von der Heyde, PhD, OTR/L, CHT

Maryville University, St. Louis, Missouri

Over the past 20 years, the literature pertaining to flexor tendon repair and rehabilitation has markedly advanced from the Kleinert and Duran protocols of the 1970s. But have our methods of rehabilitation changed? Are we using this information to advance our practice and improve our collective outcomes? Before we can answer these questions, perhaps a simpler question is: what does the literature tell us that can influence our rehabilitation protocols?

1. The literature tells us that postoperative day 4-5 is preferable to begin rehabilitation.

The timing of rehabilitation following flexor tendon repair can readily be identified as a topic of historical and continued controversy. The study of tendon healing over time has demonstrated that early controlled motion is both beneficial

to tendon healing and preferable to immobilisation (Lundborg & Rank, 1980; Hitchcock et al., 1987; Gelberman et al., 1989). Timing of early motion continues to be researched and some consistency is evident. Postoperative day 4-5 is suggested as a time during which work of flexion is decreased and therefore a good time to initiate rehabilitation (Zhao et al., 2005; Amadio, 2005; Cao et al., 2008).

2. The literature tells us that two strand repairs are not limited to passive motion protocols.

As observed in Figure 1, the work of Urbaniak et al. (1975) and Strickland and Cannon (1993) has led most surgeons, and therefore therapists, to work under the assumption that a two-strand flexor tendon repair is not capable of withstanding any “active” motion. This assumption is faulty in that it fails to recognise the low force differentials of a multitude of exercises. For example, active wrist flexion and extension only provide as much force to the healing flexor tendon as Duran’s passive protected extension exercises: 400gm or less (Schuind et al., 1992). Evans and Thompson (1993) and Groth (2004) have suggested that synergistic place and hold exercises,

which include both wrist and digit motion, create approximately 900gm of force on the healing tendon. In addition, according to Greenwald et al. (1994), an active straight fist produces approximately 1100gm of force. The specificity of this information allows us to reconsider the parameters set by Urbaniak et al. and Strickland and Cannon, in that each of the exercises mentioned here falls within the force threshold allowed by a two-strand flexor tendon repair (Figure 2).

In addition to reconsidering our choices for the rehabilitation of patients with flexor tendon injuries, it is important to be cautious in the terminology we use to describe our interventions. “Place and hold synergistic motion” is certainly a more exact description than “early active motion”. The use of more descriptive words will facilitate both communication and outcomes in the pursuit of best practice for flexor tendon rehabilitation.

3. The literature tells us that synergistic motion facilitates excursion while decreasing force.

Traditional protocols have included immobilization of the wrist in a flexed position as a means to maintain slack on the healing flexor tendon. This position is often continued for at least

“The literature tells us that two strand repairs are not limited to passive motion protocols”



four weeks postoperatively whilst place/hold or active composite flexion is initiated in the splint. A multitude of articles have been published which bring this practice into question, both with regard to force and excursion of the healing flexor tendon.

As early as 1988, Savage measured the passive tension created in the extensor musculature as a means to analyze the minimal active tension required by the flexor system. In this study, Savage found that a position of metacarpophalangeal flexion coupled with wrist extension produced the least passive tension, therefore decreasing minimal active tension of the flexor tendons. Evans and Thompson (1993) concurred with this research, presenting a mathematical model of minimal active muscle tendon tension (MAMTT). Evans and Thompson suggest the following joint positions, which create MAMTT of the flexor tendons:

- 45 degrees of wrist extension
- 83 degrees of metacarpophalangeal flexion
- 75 degrees of proximal interphalangeal joint flexion
- 40 degrees of distal interphalangeal joint flexion

In 1989, Cooney et al. compared flexor

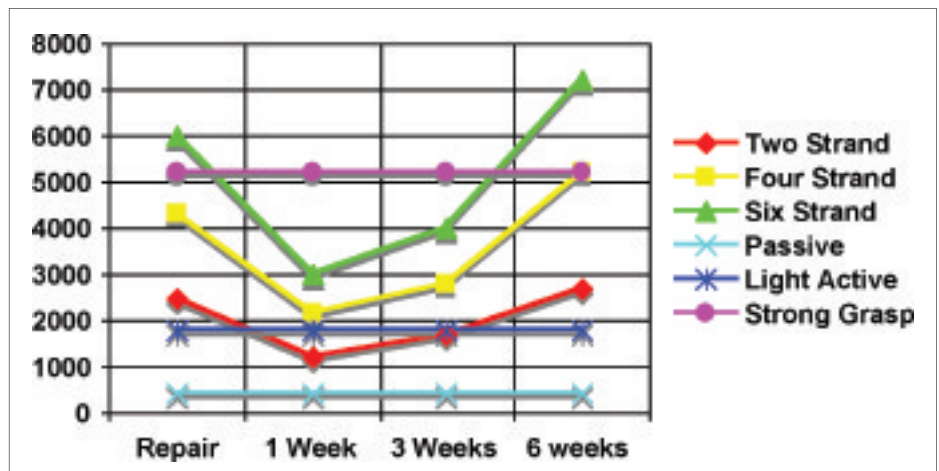


Figure 1: Force thresholds suggested by Urbaniak et al., 1975 and Strickland, 1993

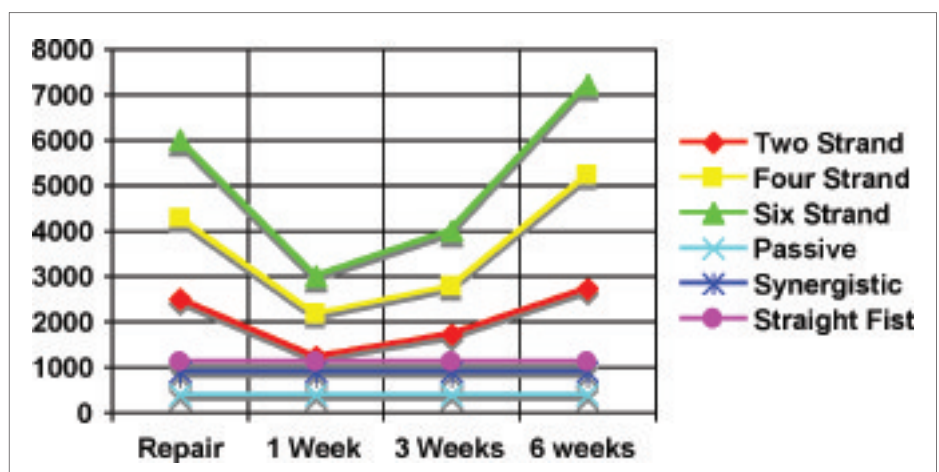


Figure 2: Modified force thresholds

tendon excursion using the Kleinert protocol (passive flexion and active extension against the resistance of the rubber band), the Brooke Army Hospital modification, and synergistic wrist extension with digital flexion. The researchers found that synergistic motion created the greatest amount of excursion of both flexor digitorum superficialis and flexor digitorum profundus. Furthermore, differential excursion (between the two tendons) was also more than with either of the two other protocols. Zhao et al. (2002) also suggested the benefits of wrist extension as an effective pulling force

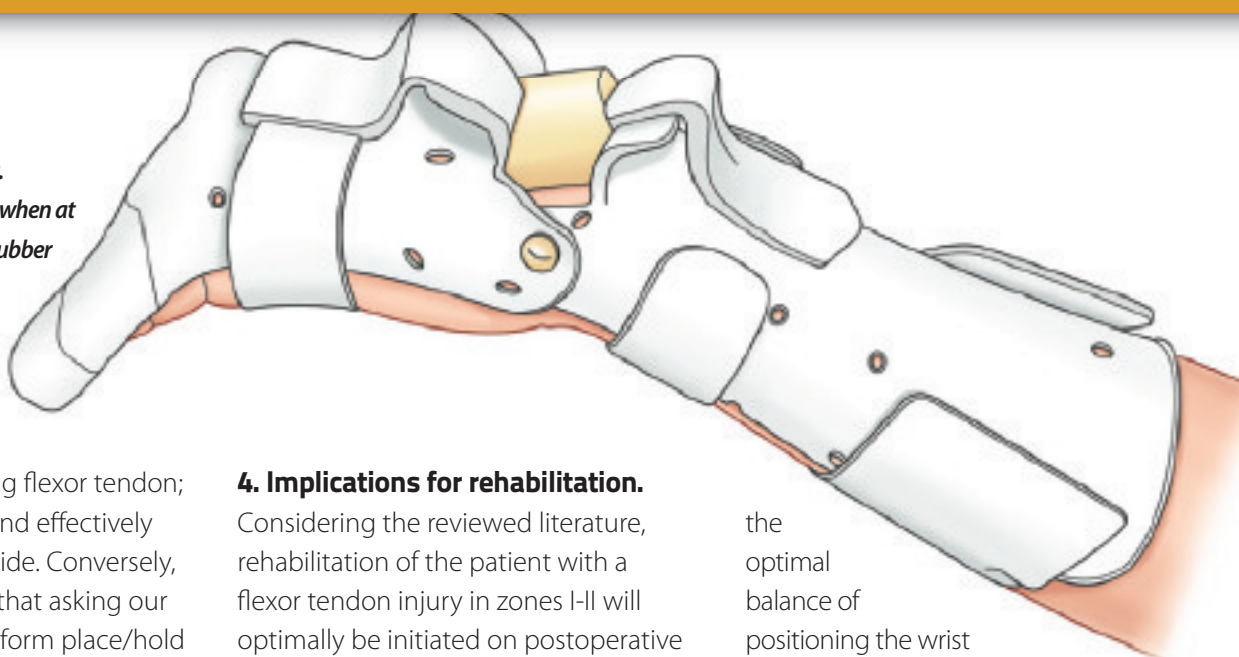
to create proximal glide.

Lieber et al. (1996, 1999) suggested that forces exerted on the flexor tendons are highly dependent on wrist position. The authors found that synergistic motion, or active wrist extension with digital flexion, resulted in low forces with high excursion.

The aforementioned studies encourage us to consider wrist motion, used both in conjunction with early place/hold and during progression of exercise, as a vital component of flexor tendon rehabilitation. It has been suggested that synergistic motion decreases both passive and active

Figure 3: Synergistic splint.

The wrist is held in flexion when at rest. During exercise, the rubber piece is removed and the wrist is extended.



tension on the healing flexor tendon; increases excursion and effectively facilitates proximal glide. Conversely, the literature tells us that asking our patients to either perform place/hold or active digital motion when the wrist is flexed, actually demands MORE force than the same motions performed with the wrist extended.

4. Implications for rehabilitation.

Considering the reviewed literature, rehabilitation of the patient with a flexor tendon injury in zones I-II will optimally be initiated on postoperative day 4-5 and include the following:

- Fabrication of a splint that the patient need not remove for completion of their home exercise program. A synergistic splint (Figure 3) provides

the optimal balance of positioning the wrist in flexion between exercise sessions, while allowing wrist extension during place and hold synergistic motion. This splint blocks the wrist in 10-20 degrees of flexion and positions the metacarpophalangeal joints in >70 degrees of flexion. With the block removed, the patient can accomplish 20-30 degrees of wrist extension during exercise. If a more simple splinting option is desired, a dorsal blocking splint with the wrist in a neutral position is an acceptable option.

- Initiation of passive protected extension (Figure 4) and place and hold synergistic motion (Figure 5). As previously stated, both of these exercises have been suggested to produce less than 1000g of force on the healing flexor tendon. In addition, passive protected extension allows for distal glide of the healing tendon while synergistic motion effectively produces proximal glide.
- Progression of exercise based on individual patient response. Decreased tendon glide is objectively quantified when passive range of motion is greater than active range of

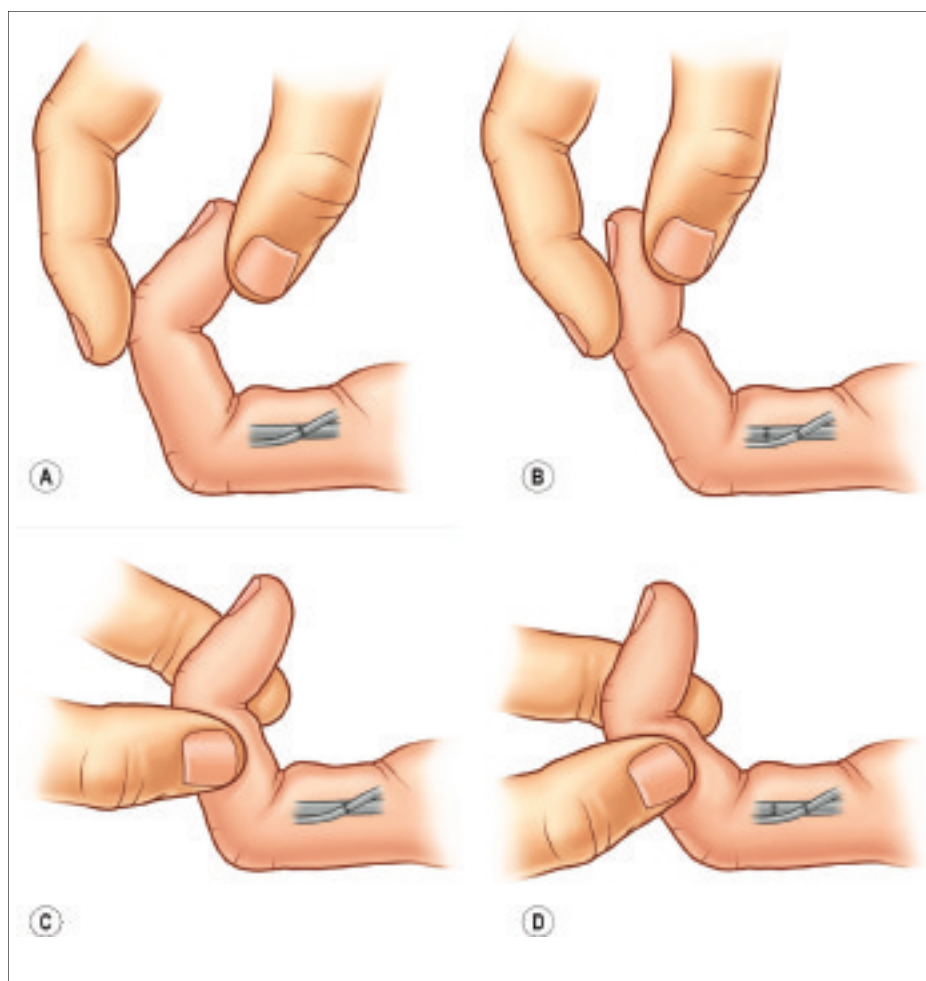


Figure 4: Passive, protected extension

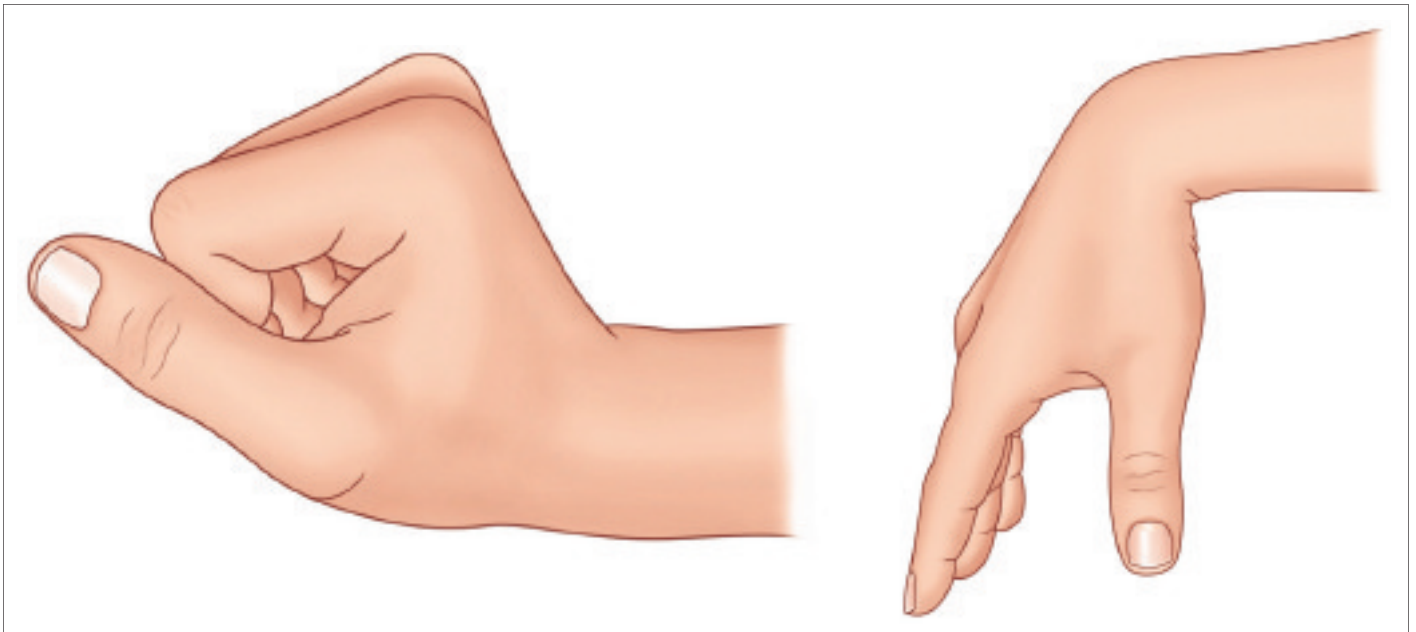


Figure 5: Place and hold synergistic motion

motion. When measurements do not change and tendon gliding is noted to be limited, exercises are added to increase force and/or excursion on the healing tendon within safe timeframes.

For the patient with a two-strand repair, it is safe to add active straight fist exercises within the first three weeks following repair. Active hook fist exercises can be safely added between weeks three and six, while active composite fist and isolated joint exercises should be added after the sixth postoperative week.

References

1. Lundborg, G. & Rank F. (1980). *Experimental studies on cellular mechanisms involved in healing of animal and human flexor tendon in synovial environment.* *Hand*, 12, 3-11.
2. Hitchcock, T. F., Light, T. R., & Bunch, W. H. (1987). *The effect of immediate constrained digital motion on the strength of flexor tendon repairs in chickens.* *J Hand Surg*, 12A, 590-595.
3. Gelberman, R. H., & Woo, S. L.-Y. (1989). *The physiological basis for application of controlled stress in the rehabilitation of flexor tendon injuries.* *J Hand Ther*, 2, 66-70.
4. Zhao, C., Amadio, P. C., Tanaka, T., Yang, C., Ettema, A. M., Zobitz, M. E., & An, K.-N. (2005). *Short-term assessment of optimal timing for postoperative rehabilitation after flexor digitorum profundus tendon repair in a canine model.* *J Hand Ther*, 18, 322-328.
5. Amadio, P. C. (2005). *Friction of the gliding surface: Implications for tendon surgery and rehabilitation.* *J Hand Ther*, 18, 112-119.
6. Cao, Y., Chen, C. H., Wu, Y. F., Xu, X. F., Xie, R. G., & Tang, J. B. (2008). *Digital oedema, adhesion formation and resistance to digital motion after primary flexor tendon repair.* *J Hand Surg*, 33E, 745-752.
7. Urbaniak, J. R., Cahill, J. D., Mortenson, R. A. (1975). *Tendon suturing methods: Analysis of tensile strengths.* In AAOS, *Symposium on tendon surgery in the hand* (pp. 70-80). St. Louis, MO: C. V. Mosby
8. Strickland, J. W., & Cannon, N. M. (1993, Spring). *Flexor tendon repair—Indiana method.* *The Indiana Hand Center Newsletter*, 1(1), 1-18.
9. Schuind, F., Garcia-Elias, M., Cooney III, W. P., & An, K.-N. (1992). *Flexor tendon forces: In vivo measurements.* *J Hand Surg*, 17A, 291-298.
10. Evans, R. B., & Thompson, D. E. (1993). *The application of force to the healing tendon.* *J Hand Ther*, 6(4), 266-284.
11. Groth, G. N. (2004). *Pyramid of progressive force exercises to the injured flexor tendon.* *J Hand Ther*, 17(1), 31-42.
12. Greenwald, D., Shumway, S., Allen, C., & Mass, D. (1994). *Dynamic analysis of profundus tendon function.* *J Hand Surg*, 19A, 626-635.
13. Savage, R. (1988). *The influence of wrist position on the minimum force required for active movement of the interphalangeal joints.* *J Hand Surg*, 13B(3), 262-268.
14. Cooney, W. P., Lin, G. T., & An, K.-N. (1989). *Improved tendon excursion following flexor tendon repair.* *J Hand Ther*, 2(2), 102-106.
15. Zhao, C., Amadio, P. C., Zobitz, M. E., Momose, T., Couvreur, P., & An, K.-N. (2002). *Effect of synergistic motion on flexor digitorum profundus tendon excursion.* *Clin Orthop and Rel Res*, 396, 223-230.
16. Lieber, R. L., Amiel, O., Kaufman, K. R., Whitney, J., & Gelberman, R. H., (1996). *Relationship between joint motion and flexor tendon force in the canine forelimb.* *J Hand Surg*, 21A, 957-962.
17. Lieber, R. L., Silva, M. J., Amiel, D., & Gelberman, R. H. (1999). *Wrist and digital joint motion produce unique flexor tendon force and excursion in the canine forelimb.* *J Biomech*, 32, 175-181.

Pioneers in Hand Surgery

IFSSH Pioneer profile:

J. William Littler, MD

Dr J William Littler, author, teacher, surgeon, and artist, came out of the Army Medical Corps after World War II as a leader and innovator of reconstructive surgery for the post-traumatic hand. He continued to lead in this area, particularly for reconstruction of the thumb.

Dr Littler received his Medical Doctorate from Duke University, Durham, North Carolina, completed a Surgical Internship at the Johns Hopkins Hospital, Baltimore, Maryland, a General Surgery Residency at the Roosevelt Hospital, New York, and a Plastic Surgery Residency at the Presbyterian Hospital, New York, under Jerome P. Webster. Dr Littler was a William S. Halsted Fellow in Surgery at Johns Hopkins Hospital (1943). He received the Bowen Brooks Fellowship Award (1946) and the Foundation Award of the American Society of Plastic and Reconstructive Surgery (1952).

Dr Littler served as a Major in the specialized Hand Center at the Cushing and Valley Forge General Hospital (1943-1947) and was a Civilian Consultant in Plastic and Reconstructive Surgery through the Korean War (1950-1954). He was a Volunteer Physician for South Vietnam to train Vietnamese surgeons in Hand Surgery and help take care of their wounded (1969).

Dr Littler was the Chief of Plastic and Reconstructive Surgery at Roosevelt Hospital, Professor of Clinical Surgery at Columbia University, Associate in Plastic Surgery at Lenox Hill Hospital, Consultant in Plastic Surgery at Sunnyview Eastern New York Orthopaedic Hospital and at the Sharon Hospital, Sharon, Connecticut.

Dr Littler gave the Sterling Bunnell Memorial Lecture in San Francisco (1965), the V.H. Kazanjian Lecture at New York University Medical Center (1969), the Sumner Koch Lecture in Chicago, Illinois (1970), the Elliot-Hurwitt Memorial Lecture at Montefiore Hospital, New York (1972), the Founder's Lecture of the American Society for Surgery of the



Hand in New Orleans (1976), the lecture honoring Emanuel B. Kaplan at New York Society for Surgery of the Hand New York Academy of Medicine (1978) and the George H. Monks Lecture at Harvard Medical School, Boston (1982).

Dr Littler was also a member of numerous National and International Societies, including the American Society for Plastic and Reconstructive Surgery, the American and British Associations of Plastic Surgeons, the American Society for Surgery of Trauma, the Caribbean Society of Hand Surgery. Dr Littler was a Founder Member of the American Society for Surgery of the Hand and was President in 1962. He

was also the President of the New York Society for Surgery of the Hand (1972-1973). Dr Littler was an honorary member of the French and the British Societies for Surgery of the Hand and of the American Academy of Orthopaedic Surgeons.

Dr Littler's achievements have been recognized through several distinctive awards. Dr Littler trained many young Hand Surgeons from around the world for many years

and they have honored him by forming the J. William Littler Society. He received the "Clinician of the Year Award" from the American Association of Plastic Surgeons (1977), the Special Achievement Award in Plastic Surgery from the American Society of Plastic and Reconstructive Surgeons (1983) and the Honorary Award from the American Association of Plastic Surgeons for "Contribution to Medicine" (1986).

Dr Littler was especially noted for his superb artistic drawing ability that he used to demonstrate his many original procedures in a clear and concise fashion. He was the author of numerous original articles and book chapters. Throughout his career he significantly contributed to the development of Hand Surgery internationally and particularly in Mexico.

IFSSH Pioneer profile:


Martin A Entin, MD

Dr Martin Entin's International Conference on Hand Surgery in Montreal in 1963 was one of the first formal seminars to encourage dialogue among Hand Surgeons from around the world. Dr Entin repeated this meeting at the Royal Victoria Hospital for many years.

Dr Entin was born in Simferopole, Crimea. He received his Bachelor of Arts degree from Temple University, Philadelphia and his Masters of Science and Doctorate Medicine from McGill University, Montreal, Canada. Following a General Surgery residency, he completed his training in Plastic Surgery at the Royal Victoria Hospital, Montreal. He was a National Research Council Fellow at McGill University, and at Stanford University Hospital, San Francisco, California, under the aegis of Dr Sterling Bunnell. He won the American Educational Foundation Traveling Fellowship to European Centers in 1955. Early in

his career Dr Entin became interested in research and made major contributions to Hand Surgery including studies of thermal burns, cold injuries, roller and wringer injuries, transplantation of autogenous joints and congenital anomalies of the upper limb.

Dr Entin has spent most of his career in affiliation with the Plastic Surgery Sub-Department of the Royal Victoria Hospital where he served as Acting Surgeon-in-Charge, Surgeon-in-Charge as well as Honorary Attending Surgeon. He has been a longtime Lecturer and Associate Professor of Surgery at McGill University. He has published a great number of articles on Hand Surgery and has been a Visiting Professor in many countries in the world including the United States,



Israel, China and South America.

Dr Entin has received many honors and awards for his contributions to the field of Plastic Surgery and Hand Surgery. He was President of the American Society

for Surgery of the Hand (1973-1974), President of the Montreal Medical Chirurgical Society (1982-83), and North American Chairman of the Pan American Medical Association – Plastic Surgery section (1983). He has been honored by the Quebec Society of Plastic and Reconstructive Surgeons for meritorious contribution to the field of Plastic Surgery.

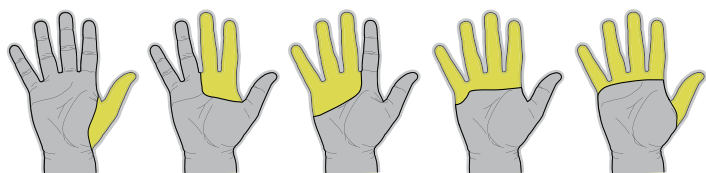
Dr Entin had a special interest in photography, sculpture, anthropology and writing. He and his supportive wife Laura resided in Montreal, P.Q., Canada.

i-limbtm digits

The powered prosthetic finger solution



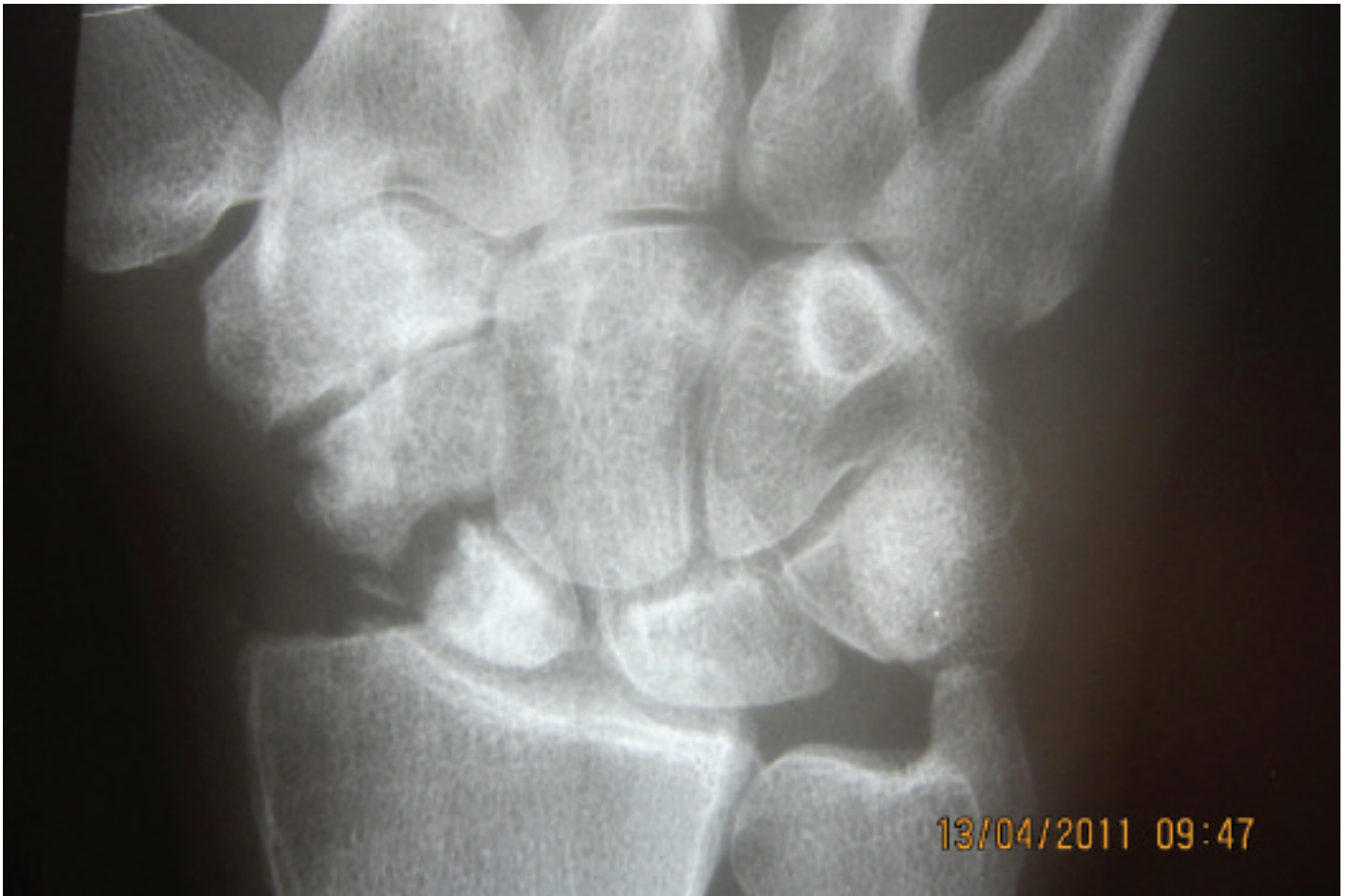- Fully customized to accommodate each patient's level of absence
- Suitable for patients missing between one and five fingers
- Provides partial hand patients with a return to function never previously available with prosthetics



Interested to know more about
i-limb digits? Working with a patient
who may be a candidate?

Click here to contact us today.

Case Study



HISTORY: 25 year old, male, right dominant, auditor, enjoys sport

Injury: fell on left hand. November 2007

Diagnosis: Scaphoid fracture

First operation: 2008 screw fixation

Second operation: 2009 screw fixation & bone grafting

Third operation: 2010 K-wire fixation & bone grafting and radius styloidectomy

Now: avascular necrosis proximal pole left scaphoid non-union

Clinically: slight discomfort, more with axial pressure

no pain

wrist extension 0-30°

wrist flexion 0-35°

Present x-ray: see above

QUESTION: What further management?

CLICK HERE
TO SUBMIT
YOUR
ANSWER

Methotrexate therapy proves to be effective in treating keloid formation

Australia

A recent study led by Professor Michael Tonkin, Department of Hand Surgery and Peripheral Nerve Surgery, Royal North Shore Hospital investigated the management of keloid formation after syndactyly release in patients with associated macrodactyly with methotrexate therapy.

"Keloid formation following surgery in the hand is rare. However, when it occurs it is a complication which is unsightly, may interfere with function and is difficult to treat. The incidence of keloid formation is greater when surgery is performed for syndactyly release when the syndactyly is accompanied by digital overgrowth (macrodactyly)," explained Professor Tonkin.

The clinical study undertaken in this article was to assess the authors' experience with the use of methotrexate to suppress the recurrence of keloid formation following excision of keloid scar and the effect of methotrexate as a prophylaxis to prevent keloid scarring in patients with a high risk, particularly those with foot syndactyly accompanied by macrodactyly.

For Tonkin, the most interesting outcomes of the study was that keloid formation following surgery for syndactyly in association with macrodactyly occurred in patients with delayed healing and/or loss of skin grafts. "This led us to wonder whether the extended inflammatory process associated with delayed healing played a role in keloid

"In this small series, methotrexate therapy appeared to dampen the keloid response in patients who were undergoing surgery to excise keloid scars in patients with syndactyly and overgrowth"

formation," Tonkin elaborated.

In this small series, methotrexate therapy appeared to dampen the keloid response in patients who were undergoing surgery to excise keloid scars in patients with syndactyly and overgrowth. Suppression of keloid formation was not complete but the clinical observation was of diminished keloid formation in these patients.

"The appearance of a spontaneous syndactyly in an unoperated second web secondary to keloid formation, which occurred from friction of a glove used to suppress scar formation in the adjacent third web, is a previously undocumented occurrence. In this patient, the keloid formation in the third web diminished over a long time period prior to institution of methotrexate therapy for the second web surgery," he continued.

According to Tonkin, this study and those of previous authors indicate that methotrexate has some effect in the

suppression of keloid formation in susceptible patients. It may be considered for those patients requiring revision surgery following keloid formation and possibly in those patients undergoing primary surgery who exhibit risk factors such as previous keloid formation elsewhere in the body and/or surgery for syndactyly in association with macrodactyly, particularly in the feet.

"However, methotrexate is an anti-neoplastic agent and, although commonly used in children with inflammatory arthropathy, should be instituted only after discussion of possible risks and possible benefits, with the assistance of a paediatric rheumatologist or paediatrician to oversee treatment, and with regular monitoring of full blood count and liver function tests," he concluded.

The authors will continue to use low-dose methotrexate in high-risk patients, particularly for revision surgery. However, no further trials or studies are envisaged currently.

JOURNAL REFERENCE

Keloid formation after syndactyly release in patients with associated macrodactyly: management with methotrexate therapy
S. K. Tolerton and M. A. Tonkin
J Hand Surg Eur Vol July 2011 vol. 36 no. 6 490-497
[<http://jhs.sagepub.com/content/36/6/490.abstract>]

New study highlights triarticular forearm complex

France

In a recent article in the European Volume of the Journal of Hand Surgery, Marc Soubeyrand, Orthopaedic & Traumatology Surgeon and Assistant Professor of Anatomy at CHU Kremlin-Bicêtre, APHParis, discussed the middle radioulnar joint and triarticular forearm complex.

"We believe the conventional concept in which the forearm is viewed as part of either the elbow or the wrist is out-dated and that a more relevant concept describes the forearm as a triarticular complex that functions as a full-fledged entity. In this concept, the three forearm radioulnar joints (proximal, middle, distal) work together to provide stability, mobility and load transfer. In the paper we argued for the relevance of the triarticular complex concept based on published data about forearm biomechanics and pathological conditions," Soubeyrand explained.

Seven years ago, while a resident at the Department of Upper Limb Surgery (Hôpital Bichat, Paris, France), Professor Oberlin proposed the idea to develop a ligamentoplasty of the forearm. "I started to work on that idea and we published the first paper dealing with the pathology of the interosseous membrane. The last paper was the outcome of several years of reflection about the forearm's pathology and physiology," he continued.

For him, the most interesting observations of this paper was how complex and intricate the human forearm actually is with its pronosupination motion. Soubeyrand believes all hand surgeons should understand the following: "Firstly, the forearm is not only composed of two joints (proximal and distal radioulnar joints). In fact, there is a third joint, the biggest one, composed of the radial and ulnar shafts and the interosseous membrane. Secondly, these three joints must be considered as an inseparable unit when considering it in both normal and pathological contexts," he added.

The team will continue to work in this area in the future. "We want to contribute towards improving methods of diagnosing the forearm's instability in the acute phase of trauma using dynamic ultrasonography. In addition we will continue to develop surgical techniques that allow the long-term restoration of the forearm stability in both longitudinal and axial directions.

"the conventional concept in which the forearm is viewed as part of either the elbow or the wrist is out-dated"

JOURNAL REFERENCE

The middle radioulnar joint and triarticular forearm complex
M. Soubeyrand, V. Wassermann, C. Hirsch
J Hand Surg Eur Vol July 2011 vol. 36 no. 6 447-454
[<http://jhs.sagepub.com/content/36/6/447.abstract>]

IFSSH 2010 SEOUL
10th Triennial Congress of the International Federation of
Societies for Surgery of the Hand
October ~ 4 November 2010 | Sheraton Grand Walkerhill Hotel, Seoul, Korea



For the members by the members...

The **IFSSH ezine** is created with the intention of engaging the global hand surgery community and to promote the profession through the sharing of knowledge.

In order for the IFSSH ezine to remain relevant and topical, we rely on you, our readers, to:

- Subscribe to receive the ezine
FREE OF CHARGE 4 times per year
- Submit letters to the editor
- Provide us with feedback about the ezine

CLICK HERE
TO COMPLETE A
5 MINUTE SURVEY
ABOUT THE
IFSSH EZINE

Journal Highlights

Below is a selection of contents pages from the latest issues of the following leading hand surgery journals. Hover your mouse over each article heading and click to go to the original abstract page of the article

Journal of Hand Surgery: American volume October 2011, Vol. 36, No. 10

■ Prevention of Anastomotic Thrombosis by Botulinum Toxin B After Acute Injury in a Rat Model. Brian A. Janz, Peter R. Thomas, Sione P. Fanua, Reginald E. Dunn, E.F. Shaw Wilgis, Kenneth R. Means

■ The Limits of Medial Femoral Condyle Corticoperiosteal Flaps. Matthew L. Iorio, Derek L. Masden, James P. Higgins

■ Reconstruction of Thumb Pulp Defects Using a Modified Kite Flap. Xu Zhang, Xinzhong Shao, Chunzhen Ren, Zhijie Zhang, Sumin Wen, Jianxin Sun

■ Repair of Flexor Digitorum Profundus to Distal Phalanx: A Biomechanical Evaluation of Four Techniques. Steve K. Lee, Marc Fajardo, George Kardashian, Jason Klein, Peter Tsai, Dimitrios Christoforou

■ Multicentric Giant Cell Tumor of the Upper Extremities: 16 Years of Ongoing Disease. Eduardo N. Novais, Alexander Y. Shin, Allen T. Bishop, Thomas C. Shives

■ Analysis of the Complications of Palmar Plating Versus External Fixation for Fractures of the Distal Radius. Pages 1614-1620. Marc J. Richard, Daniel A. Wartinbee, Jonathan Riboh, Michael Miller, Fraser J. Leversedge, David S. Ruch

■ Ligament Contribution to Patterns of Articular Fractures of the Distal Radius. Daniel G. Mandziak, Adam C. Watts, Gregory I. Bain

■ The Biomechanical Effect of the Distal Interosseous Membrane on Distal Radioulnar Joint Stability: A Preliminary Anatomic Study. Takashi Kitamura, Hisao Moritomo, Sayuri Arimitsu, Lawrence J. Berglund, Kristin D. Zhao, Kai-Nan An, Marco Rizzo

■ Reverse End-to-Side Nerve Transfer: From Animal Model to Clinical Use. Santosh S. Kale, Simone W. Glaus, Andrew Yee, Michael C. Nicoson, Daniel A. Hunter, Susan E. Mackinnon, Philip J. Johnson

■ Cubital Tunnel Syndrome Caused by Amyloid Elbow Arthropathy in Long-term Hemodialysis Patients: Report of 4 Cases. Takaki Shinohara, Masahiro Tatebe, Nobuyuki Okui, Michiro Yamamoto, Shigeru Kurimoto, Hitoshi Hirata

■ Computer Simulation of Nerve Transfer Strategies for Restoring Shoulder Function After Adult C5 and C6 Root Avulsion Injuries. Dustin L. Crouch, Zhongyu Li, Jonathan C. Barnwell, Johannes F. Plate, Melissa Daly, Katherine R. Saul

■ Capsulectomy and Debridement for Primary Osteoarthritis of the Elbow Through a Medial Trans-Flexor Approach. Yasunori Hattori, Kazuteru Doi, Soutetsu Sakamoto, Shushi Hoshino, Chaitanya Dodakundi

■ Potential Dangers of Tension Band Wiring of Olecranon Fractures: An Anatomic Study. Louis W. Catalano III, Keith Crivello, Marissa Purcelli Lafer, Benjamin Chia, O. Alton Barron, Steven Z. Glickel

■ Chronic Psychological and Functional Sequelae After Emergent Hand Surgery. Todd Richards, Donn W. Garvert, Elizabeth McDade, Eve Carlson, Catherine Curtin

■ A Comparison of 2 Methods for Scaphoid Central Screw Placement From a Volar Approach. Geert Meermans, Frederik Verstreken

■ Treatment of Kienböck Disease by Lunate Core Decompression. Saeed Reza Mehrpour, Reza Shahriar Kamrani, Mohamad Reza Aghamirsalim, Reza Sorbi, Alper Kaya

■ Bilateral Avascular Necrosis of the Trapezoid. Priscilla D'Agostino, William Arthur Townley, Eric Roulot

Journal of Hand Surgery: European Volume

J Hand Surg Eur Vol September 2011; 36 (7)

■ Outcome of axillary nerve injuries treated with nerve grafts. M. Okazaki, A. Al-Shawi, C. R. Gschwind, D. J. Warwick, and M. A. Tonkin

■ Shoulder arthrodesis in adult brachial plexus injury: what is the optimal position? R. Sousa, A. Pereira, M. Massada, M. Trigueiros, R. Lemos, and C. Silva

■ Percutaneous needle fasciotomy for primary Dupuytren's contracture. L. Rahr, P. Søndergaard, T. Bisgaard, and T. Baad-Hansen

■ Effects of forearm muscles on carpal stability. G. Salva-Coll, M. Garcia-Elias, M. T. Leon-Lopez, M. Llusa-Perez, and A. Rodríguez-Baeza

■ Biomechanical comparison of three fixation techniques used for four-corner arthrodesis. J. Kraissarin, D. G. Dennison, L. J. Berglund, K. N. An, and A. Y. Shin

■ Fractures of the distal radius in women aged 50 to 75 years: natural course of patient-reported outcome, wrist motion and grip strength between 1 year and 2–4 years after fracture. E. Brogren, M. Hofer, M. Petranek, L. B. Dahlin, and I. Atroshi

■ Displaced unstable transverse fractures of the shaft of the proximal phalanx of the fingers in industrial workers: reduction and K-wire fixation leaving the metacarpophalangeal and proximal interphalangeal joints free. Mohammad M. Al-Qattan

■ The biomechanical assessment of gap formation after flexor tendon repair using partial interlocking cross-stitch peripheral sutures. N. Takeuchi, H. Mitsuyasu, K. Kikuchi, T. Shimoto, H. Higaki, and Y. Iwamoto

■ Ten years follow-up of health and disability in people with acute traumatic hand injury: pain and cold sensitivity are long-standing problems. M. Gustafsson, L. Hagberg, and M. Holmefur

■ Failures of the RM finger prosthesis joint replacement system. A. Middleton, R. Lakshminpathy, and L. R. Irwin

Journal of Hand Therapy

Volume 24, Issue 3, Pages 183-290 (July-September 2011)

■ A Randomized Clinical Controlled Study Comparing the Effect of Modified Manual Edema Mobilization Treatment with Traditional Edema Technique in Patients with a Fracture of the Distal Radius, 03 January 2011. Karin Knygsand-Roenhoej, Thomas Maribo

■ Dynamic Splinting for the Stiff Hand after Trauma: Predictors of Contracture Resolution, 20 May 2011. Celeste Glasgow, Leigh R. Tooth, Jenny Fleming, Susan Peters

■ Muscle Activation during Hand Dexterity Tasks in Women with Hand Osteoarthritis and Control Subjects, 10 February 2011. Kristina M. Calder, Victoria Galea, Jean Wessel, Joy C. MacDermid, Norma J. MacIntyre

■ Comparison of Two Carpometacarpal Stabilizing Splints for Individuals with Thumb Osteoarthritis, 21 March 2011. Helia Sillem, Catherine L. Backman, William C. Miller, Linda C. Li

■ Clinical Commentary in Response to: Comparison of Two Carpometacarpal Stabilizing Splints for Individuals with Thumb Osteoarthritis, 13 June 2011. Virginia H. O'Brien

■ Static Versus Dynamic Splinting for Proximal Interphalangeal Joint Pyrocarbon Implant Arthroplasty: A Comparison of Current and Historical Cohorts, 09 June 2011. Jeanne M. Riggs, Angela K. Lyden, Kevin C. Chung, Susan L. Murphy

■ Progress in Vibrotactile Threshold Evaluation Techniques: A Review, 28 March 2011. Minu Shikha Gandhi, Richard Sesek, Robert Tuckett, Stacy J. Morris Bamberg

■ Upper Extremity Function in Stroke Subjects: Relationships between the International Classification of Functioning, Disability, and Health Domains, 21 March 2011. Iza Faria-Fortini, Stella Maris Michaelsen, Janine Gomes Cassiano, Luci Fuscaldi Teixeira-Salmela

■ A Test Case: Does the Availability of Visual Feedback Impact Grip Strength Scores When Using a Digital Dynamometer?, 01 April 2011. Gwen Weinstock-Zlotnick, Jane Bear-Lehman, Tzu-Ying Yu

HAND

Volume 6 / 2011 Issue 3 pages 235-347

- A systematic review of outcomes of toe-to-thumb transfers for isolated traumatic thumb amputation. Pao-Yuan Lin, Sandeep Jacob Sebastin, Shimpei Ono, Lillian T. Bellfi and Kate Wan-Chu Chang, et al.
- Giant cell tumour of tendon sheath of the digits. A systematic review. Elias Fotiadis, Alexis Papadopoulos, Theodoros Svarnas, Panagiotis Akritopoulos and Nick P. Sachinis, et al.
- A systematic review of outcomes of fasciotomy, aponeurotomy, and collagenase treatments for Dupuytren's contracture. Neal C. Chen, Ramesh C. Srinivasan, Melissa J. Shauver and Kevin C. Chung
- Minimally invasive technique for release of Dupuytren's contracture: segmental fasciectomy through multiple transverse incisions. Eon Kyu Shin and Neil Ford Jones
- A functional outcomes survey of elderly patients who sustained distal radius fractures. Louis F. Amorosa, Mark A. Vitale, Shervondalonn Brown and Robert A. Kaufmann
- The resurgence of barbed suture and connecting devices for use in flexor tendon tenorrhaphy. Yazeed Mazen Gussous, Chunfeng Zhao, Peter C. Amadio and Kai-Nan An
- Modified Brunelli pull-out technique in flexor tendon repair for zone II: a study on 58 cases. Alexandru Valentin Georgescu, Ileana R. Matei, Irina M. Capota, Filip Ardelean and Octavian D. Olariu
- Complications with the use of Artelon in thumb CMC joint arthritis. Sylvan Clarke, William Hagberg, Robert A. Kaufmann, Aaron Grand and Ronit Wollstein
- Complex and rare fracture patterns in perilunate dislocations. John G. Apostolides, Scott D. Lifchez and Michael R. Christy
- A novel model for evaluating nerve regeneration in the composite tissue transplant: the murine heterotopic limb transplant. Ying Yan, Philip J. Johnson, Simone W. Glaus, Daniel A. Hunter and Susan E. Mackinnon, et al.
- Case report: intraneural ganglion cyst of the ulnar nerve at the wrist. Stephen H. Colbert and MyChi H. Le
- Metastasis of parotid basal cell adenocarcinoma to the hand—a case report. Michael H. Elvey, Maurice Aghasi, Ziv Wasrbrou and Erez Avisar
- Salvage reconstruction of failed pollicization by distraction lengthening. Michael Ly Nguyen and Neil F. Jones
- Unusual presentation of hemochromatosis as isolated metacarpophalangeal joint osteoarthritis: a case report. Sunishka M. Wimalawansa and Rannie AlSamkari
- Isolated capitate fracture with dorsal dislocation of proximal pole: a case report. Dhananjaya Sabat, Sumit Arora and Anil Dhal
- Pediatric compartment syndrome following an insect bite: a case report. Aisha J. McKnight, John C. Koshy, Amy S. Xue, Megan Shetty and Jamal M. Bullocks
- Bilateral proximal delta phalanges: an unusual presentation of familial congenital clinodactyly. Steven B. Albright, Amy S. Xue, John C. Koshy, Robert C. Orth and Larry H. Hollier
- Posterior interosseus palsy with an incidental Froment–Raubert nerve presenting as a pseudoclaw hand. Bev Y. Guo, D. R. Ayyar and John A. I. Grossman

Journal of Brachial Plexus and Peripheral Nerve Injury

6:4 – 6:6 August– October 2011

- A Quantitative Evaluation of Gross Versus Histologic Neuroma Formation in a Rabbit Forelimb Amputation Model: Potential Implications for the Operative Treatment and Study of Neuromas. Jason H Ko, Peter S Kim, Kristina D O'Shaughnessy, Xianzhong Ding, Todd A Kuiken, Gregory A Dumanian
- Atrophy of the brachialis muscle after a displaced clavicle fracture in an Ironman triathlete: Case report. Rust Christoph Alexander, Knechtle Beat, Knechtle Patrizia, Rosemann Thomas
- Complex regional pain syndrome with associated chest wall dystonia: a case report. David J Irwin, Robert J Schwartzman
- Paresthesia and forearm pain after phlebotomy due to medial antebrachial cutaneous nerve injury. Mahsa Asheghian, Amidoddin Khatibi, Mohammad Holisaz
- Acute nerve stretch and the compound motor action potential. Mark M Stecker, Kelly Baylor, Jacob Wolfe, Matthew Stevenson

IFSSH-IFSHT 2013

The Indian Society for Surgery of Hand considers it a privilege to host the 12th Triennial Congress of the International Federation of Societies for Surgery of Hand (IFSSH) and 9th Triennial Congress of the International Federation of Societies for Hand Therapists (IFSHT) in New Delhi from 4th to 8th March 2013.

Preparations are under way to make your visit a memorable one. We are keen that the academic content of the meeting be excellent and to make a good programme, we need your help. I will be very grateful if you could send me a list of prominent Hand Surgeons from your country who could be invited as faculty and their field of specialisation. They would be listed in the website as invited speakers and will have more time to present their work than other delegates. As is



the practice in the IFSSH congresses, the invited speakers will have to take care of their registration and accommodation. The website of the meeting www.ifssh-ifsht2013.com is on and we will frequently be updating the website.

Welcome to Incredible India

*Dr. S. Raja Sabapathy, MS, M.Ch, DNB, FRCS(Ed), MAMS
Organising Chairman, IFSSH - IFSHT 2013,
Chairman, Division of Plastic Surgery, Hand Surgery,
Reconstructive Microsurgery and Burns
Ganga Hospital, India
E-mail: chairman@ifssh-ifsht2013.com
Website: www.ifssh-ifsht2013.com*



**2012 World Symposium on Congenital Malformations
of the Hand and Upper Limb**

MARCH 22-24, 2012

Congress Chairs:

Scott N. Oishi, M.D. and Marybeth Ezaki, M.D.

**After March 2011 registration and
more information will be available at
community.tsrhc.org/worldhandsymposium.**



**Texas Scottish Rite Hospital for Children
T. Boone Pickens Training and Conference Center
2222 Welborn Street • Dallas, Texas • 75219**

Make Your Plans Now to Attend the 2012 American Association for Hand Surgery Annual Meeting

In Collaboration with the Brazilian Society for Surgery of the Hand (Sociedade Brasileira De Cirurgia Da Mão)

The Red Rock Casino Resort & Spa 11-14 January 2012

Preliminary Program & Registration Brochure

View all of the exciting programming that will take place throughout the week. Preview the Scientific Sessions and Social Events being offered.

Meeting Highlights:

Invited Guest Lecture- Wednesday, 11 January 2012

James Chang, MD – More Unfortunate Lessons from War: Current Research on Unsolved Hand Trauma Problems

The specialty of hand surgery began as a result of the influx of hand trauma from World War II. In recent wars, advances in military medical care have dramatically increased survival rates for injured soldiers. With lives saved, the reconstruction of traumatized extremities has again become a priority, this time for Federal research funding. In this lecture, the unsolved problems in reconstruction of hand trauma will be presented with a special focus on cutting edge research.

Invited Guest Lecture - Thursday, 12 January 2012

Mandayam A. Srinivasan, PhD

Haptics: Science, Technology and Applications

Dr. Mandayam Srinivasan is Director of the MIT Touch Lab and Senior Scientist in the Department of Mechanical Engineering and the Research Laboratory of Electronics at MIT. Dr. Srinivasan will describe the scientific and technological underpinnings of the emerging field of Haptics. This will entail a brief overview of our recent advances in skin biomechanics, tactile neuroscience, human haptic perception, robotic hardware and real-time simulation software, all of which have helped establish Haptics as an exciting area of research.

Danyo Lecture – Friday, 13 January 2012

Terry Light, MD

Digital Education - Where Have All the Books Gone?

Terry R. Light, M.D. is the Dr. William M. Scholl Professor and Chairman of the Department of Orthopaedic Surgery and Rehabilitation at Loyola University Stritch School of Medicine. Dr. Light directs the educational programs

of students, resident and hand fellows at the school. Dr. Light's interactive presentation will share his perspective on "Digital Education - Where have all the books gone?" He will consider how internet based resources and tools will facilitate our education of the next generation of hand surgeons. Bring your smart phone or PDA so that you can be part of the conversation.

Joint Presidential Keynote Lecture (Joint with ASPN and ASRM) - Saturday, 14 January 2012

Steven D. Levitt

Steven Levitt is an American economist who is a brilliant but uncomplicated man who uses simple questions to reach startling conclusions. Though he has no political agenda his theories have set off a firestorm of controversy and had both conservatives and liberals up in arms. Winner of the 2004 John Bates Clark Medal, he is currently the William B. Ogden Distinguished Service Professor of Economics at the University of Chicago. He co-authored the best-selling book *Freakonomics* and its sequel *Superfreakonomics*.

Registration Now Available Online: <http://handsurgery.org/meeting/>
Be sure to register for the AAHS meeting before Friday, 11 November 2011 to receive the Early Bird Registration Rates!

The Red Rock Casino Resort & Spa:

<http://meeting.handsurgery.org/housing.cgi>

Make your hotel reservation online or contact the hotel directly at 1-866-767-7773 and refer to group code: AAHS/ASPN/ASRM.

Hand surgeons and hand therapists from around the world are invited to attend – We look forward to seeing you in Las Vegas, Nevada, USA!

AAHS Future Meetings:

AAHS 2013 Annual Meeting

Naples Grande Resort & Club, Naples, Florida
9-12 January 2013

AAHS 2014 Annual Meeting

Grand Hyatt Kauai Resort & Spa, Kauai, Hawaii
8-11 January 2014

AAHS 2015 Annual Meeting

Atlantis Resort, Paradise Island, Bahamas, 21-24 January 2015

