

## MEMBERS NEWS

- Paul R Manske Award winner announced
- An update from the Secretary General



# Lessons from Julius Casserius:

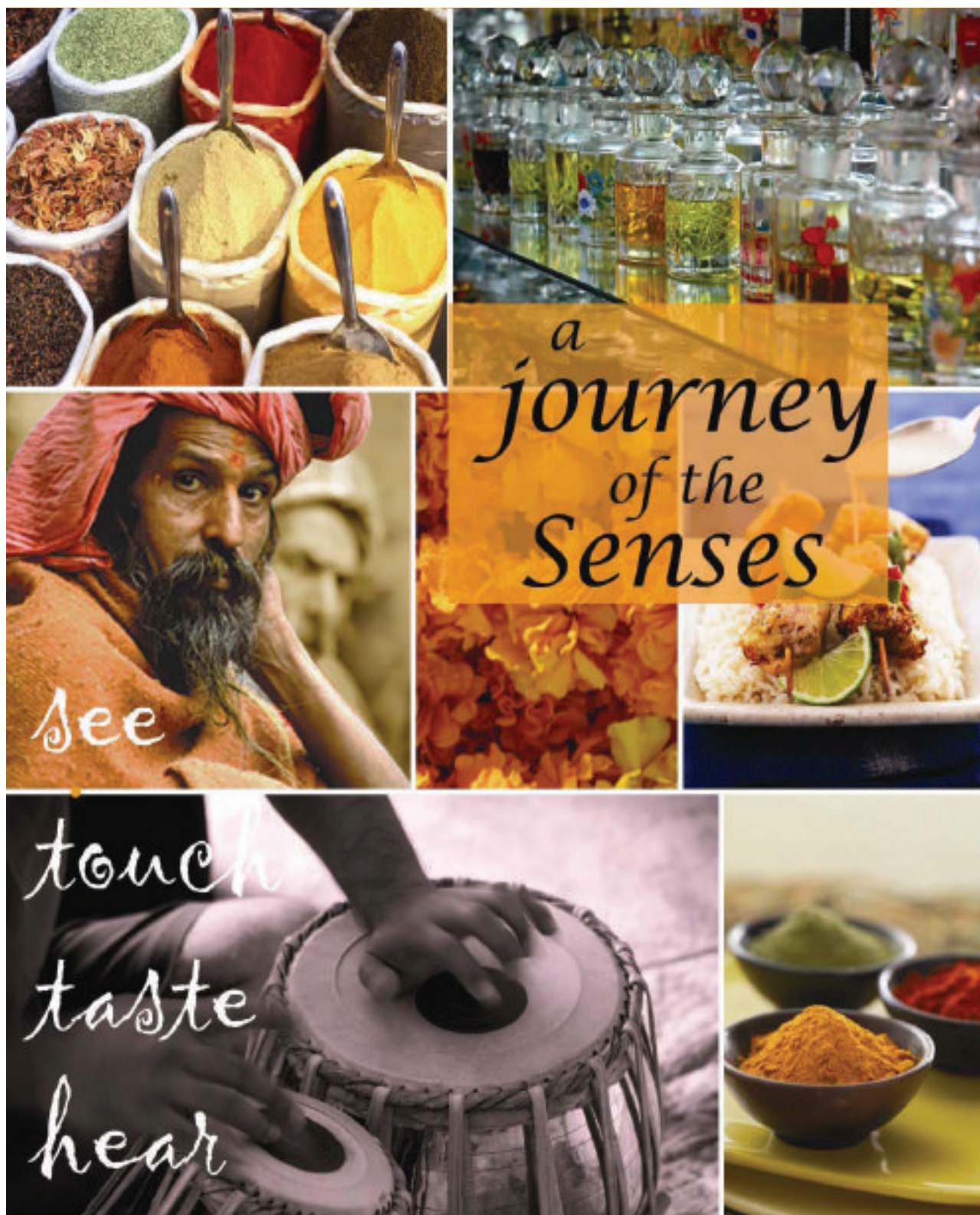
Discoveries and innovations  
by 17th Century hand surgeon

PAIN GUIDED HAND THERAPY FOR HAND  
FRACTURES: THE SAINT JOHN PROTOCOL

ANATOMY AND FUNCTION OF  
THE THENAR MUSCLES







12th Triennial Congress of the IFSSH  
&  
9th Triennial Congress of the IFSHT

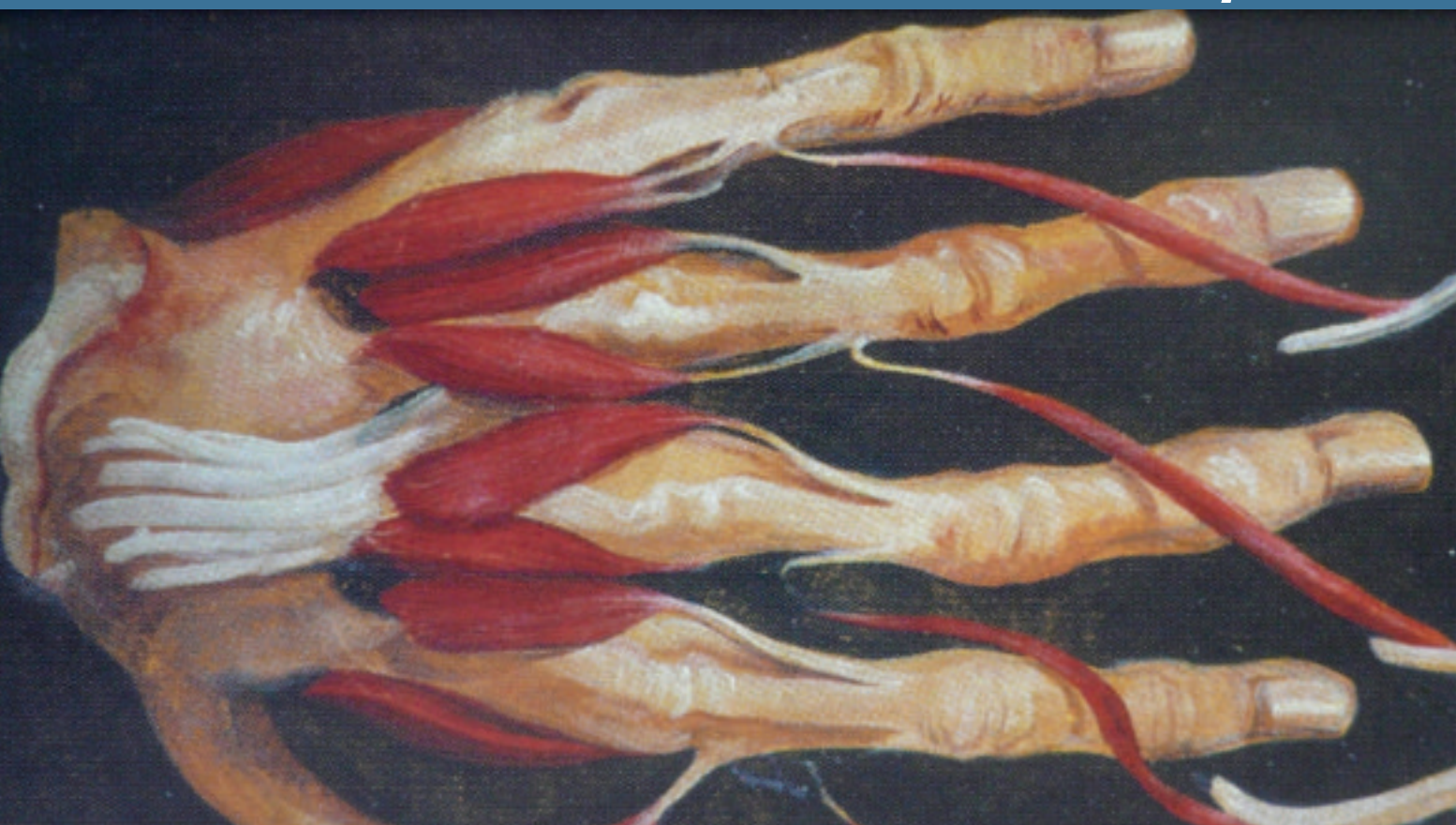See you in New Delhi 4th – 8th March 2013



Congress Chairman  
Dr. S. Raja Sabapathy

Website  
[www.ifssh-ifsht2013.com](http://www.ifssh-ifsht2013.com)





# Contents

## 4 Editorial

By Professor Ulrich Mennen, editor of the IFSSH ezine

## 5 Members news

Paul R Manske Award for the best upper extremity congenital research manuscript  
An update from the Secretary General

## 8 Hand Surgery focus

Lessons from Julius Casserius, the most prominent hand surgeon of the 17th Century

## 14 IFSHT

Pain Guided Hand Therapy for Hand Fractures: the Saint John Protocol

## 18 Pioneer Profiles

Professors Erik Moberg and Johan Landsmeer

## 20 Research Roundup

Rheumatoid hand surgery  
Anatomy and function of the thenar muscles  
Anatomy and function of lumbrical muscles

## 23 Journal Highlights

Tables of Contents from leading journals such as The Journal of Wrist Surgery, The American Journal of Hand Surgery, Journal of Hand Surgery Asian Volume, Journal of Hand Surgery European Volume and the Journal of Hand Therapy.

## 27 Upcoming events

List of global learning events and conferences for hand surgeons

## No pain, nore gain

Nobody wants the curse of pain. The feeling is sore, obnoxious, depressing and incapacitating. It negatively affects our emotions, logic and attitude. On the other hand, the ability to feel pain is a blessing; it is essential for our wellbeing, for life itself. People without this ability, this 'gift' to sense pain (e.g. familial pain insensitivity, leprosy) mutilate themselves, have fractures and severe infections without the slightest discomfort. But PAIN is the alarm bell that starts ringing. It tells us that something is wrong, that damage is being caused. Pain 'screams', it begs to stop whatever activity causes the hurting. Pain even has various characteristics. It comes in various forms. Colic-type pain indicates an obstruction of a hollow organ e.g. stone blocking an ureter. Deep burning, constant-agony pain, points to ischaemia of a muscle. Throbbing pain indicates vasodilatation e.g. migraine or inflammation. Nerve pain is not alleviated by painkillers, whereas pain due to inflammatory irritation (e.g. osteoarthritis) responds to anti-inflammatory drugs.

**Inflammation is a normal response** by our bodies to any kind of trauma e.g. mechanical, infection, metabolic, thermal, chemical, etc. It is an essential reaction by the tissues to the effect of the trauma. It is essential for the healing process. Inflammation is an essential part of living. Without it we would all die, because without it infection cannot be fought and tissue damage cannot be healed. The classic signs of inflammation are throbbing pain, swelling, redness, tenderness and function loss.

As therapists we have to address the cause of these signs, i.e. vasodilatation and extravasations of fluid. This causes

the pain, swelling, redness and function loss. Oedema fluid is protein rich and is foreign to the interstitial tissue where it lies. It irritates the tissue because of its protein content, and therefore causes MORE inflammation. A vicious cycle begins. We can counter the inflammatory process by getting rid of the oedema fluid. Elevation, massage and pressure garments are mechanical means of reducing oedema. Anti-inflammatory drugs do it chemically.

This brings us back to our alarm system, pain sensation. Therapy which causes pain causes tissue damage, causes inflammation, causes more tissue reaction. It counters all the logical healing efforts. It is anti-therapy. Any person (and I do not want to call them therapists) who subscribe to the irresponsible dictum: 'no pain no gain' should be excommunicated from the health profession.

These quacks do not have the slightest knowledge of physiology, pathology and the healing process. They have a sadistic nature, which causes their patients and the therapy profession much harm.

**All therapy should be done gently, within the limits of pain.** This approach will encourage wellbeing and gain the confidence of your patient. After all, we want to rid our patient of inflammation, promote function and make them pain free. Then, I believe we have succeeded in our mission. **No pain, is more gain!**



Ulrich Mennen  
President: IFSSH.  
Editor: IFSSHazine

**IFSSH disclaimer:** The IFSSH ezine is the official mouthpiece of the International Federation of Societies for Surgery of the Hand. The IFSSH does not endorse the commercial advertising in this publication, nor the content or views of the contributors to the publication. Subscription to the IFSSH ezine is free of charge and the ezine is distributed on a quarterly basis. To subscribe, please **click here**. Should you wish to support this publication through advertising, please **click here**.

### IFSSH ezine editorial team:

**Editor:** Professor Ulrich Mennen (President of the IFSSH)

**Deputy Editor:** Professor Michael Tonkin (President-elect of the IFSSH)

**Publication coordinator:** Marita Kritzing (Apex ezines)

**Graphic Designer:** Andy Garside

SUBSCRIBE TO THE  
ezine  
**ifssh**  
FOR FREE

# Paul R Manske Award for the best upper extremity congenital research manuscript

In honour of the late Paul R Manske (please see obituary in the IFSSHazine of May 2011) the USA based Pediatric Hand Study Group has established an annual Paul R Manske Award (which includes a monetary honorarium) for the best upper extremity congenital research manuscript.

The four member panel (Charles A. Goldfarb, MD, Ann Van Heest, MD, Michelle James, MD, H. Relton McCarroll, MD), recently selected the paper by GB Andersson, C Gillberg, E Fernell, M Johansson and A Nachemson, entitled: "Children with surgically corrected hand deformities and upper limb deficiencies: self-concept and psychological well-being", in the Journal of Hand Surgery (European) 2011.36: 795-801, as the 2011 winner.

The winner was chosen after careful review of the scientific manuscripts in 6 journals including the Journal of Hand Surgery (American and European), the Journal Bone Joint Surgery (American and British), the Journal Pediatric Orthopedics (American), and the Journal of Plastic and Reconstructive Surgery. They felt that this manuscript was the most impactful and relevant for the field of children's hand surgery and the care of patients with congenital hand anomalies.

The manuscript describes a study about the self-concept and psychological well-being

in 92 children with either mild or severe hand deformities and upper limb deficiencies. Testing for self-esteem and wellbeing showed 'good' overall self-concept, equal to a comparative group of healthy children. Interestingly, those with severe deformities had higher (better) self-concept than those with mild deformities.

This study provides new information for those who care for children with congenital anomalies. It will help to improve care as it will allow more informed discussions with families. The IFSSH congratulates the winners on their contribution to the profession.

*The inaugural Paul R Manske 2011 Award was presented by Dr. Claire Manske, (daughter of Paul, who is presently an Orthopaedic Resident at the Washington University in St. Louis, USA) to Dr. Ann Nachemson (Sweden), one of the authors, at the 10th World Congenital Hand Anomalies Congress which was held in March 2012 in Dallas, Texas, USA.*





# Secretary General's Report

## 2012 DELEGATES' COUNCIL MEETING

The 2012 IFSSH Delegates' Council meeting will be held on Friday 22nd June, 2012 10:15am-12:00pm. This will take place in Antwerp, in conjunction with the FESSH annual congress. We look forward to welcoming the delegates from all IFSSH member nations and discussing the activities and plans of our Federation. An agenda and relevant documentation will be forwarded to all delegates in the near future. If your society has updated its contact details or appointed a new delegate, please ensure the IFSSH secretariat has been notified (email: [administration@ifssh.info](mailto:administration@ifssh.info)). If your delegate is unable to attend could you nominate an alternative member to represent your society.

Further information regarding the 2012 FESSH Congress is available via the website: [www.fessh2012.org](http://www.fessh2012.org).

## BURSARIES AND GRANTS

As discussed at the 2011 Delegates' Council Meeting, one of the goals of the IFSSH is to support worthy hand surgery proposals with financial assistance. Examples of previous projects/recipients have included the Baragwanath Hospital

Hand Fellowship, production of the Terminology for Hand Surgery publication in five languages, and an educational DVD on Pollicization. To increase the profile of this programme, the IFSSH Executive and Delegates have initiated the 'IFSSH Special Committee on Educational Sponsorship', chaired by Marc Garcia-Elias (IFSSH Secretary-Elect). The full details of this committee and the process for applications are detailed on the IFSSH website ([www.ifssh.info](http://www.ifssh.info)). If you have a relevant project, please consider applying for an IFSSH grant.

## TRIENNIAL CONGRESS: INDIA 2013

With only one year remaining until India hosts the 2013 triennial IFSSH Congress, Zsolt Szabo (IFSSH Secretary General) and Lynne Feehan (IFSHT President) visited Delhi last month to perform the site inspection and discuss the conference plans and progress with the Indian Society's Organising Committee.

Dr Raja Sabapathy, Organising Chairman, and his committee have prepared an informative scientific programme, accompanied by memorable social events and we look forward to joining the Indian Society for the triennial IFSSH Congress –

March 4-8, 2013. Further information is available via [www.ifssh-ifsht2013.com](http://www.ifssh-ifsht2013.com).

## REGIONAL EDUCATION PROGRAMME: EASTERN EUROPE, 2012

At the 2011 meeting, the Delegates' Council approved a new education programme which will start this year. The IFSSH will financially assist (up to US\$20,000) a hand surgery teaching programme in economically handicapped regions. This is to be organised on an annual rotation basis (through Europe, America, Asia and Africa). The IFSSH also hopes to assist by providing the experience and knowledge of its members to the faculty of these courses.

The format will entail a 2-3 day course with a number of young hand surgeons (under 45 years) from the region participating for free. These surgeons will be selected by their own national societies within the geographical region of that year's course. The number of free participation possibilities will be influenced by the budget, but will be announced at least four months prior to the event. Beyond this, the course will be open for registrations from hand surgeons within the region for a reduced fee. The course

organisers should attract sponsors, other educational grants and support in order to significantly reduce the cost of participation, accommodation and catering. The scientific programme of the course must be approved by the IFSSH ExCo. The Delegates' Council will consider the region/host society options for the following year at each annual Council meeting.

This Regional Education Programme will commence in 2012 with the Eastern European Course, sponsored and endorsed by the IFSSH and FESSH. This course will be organised in Debrecen, Hungary, close to the Romanian border, allowing participants from all Eastern European countries to come by car or train. Each national society from Eastern Europe will have the option to nominate four delegates for free (registration, accommodation and catering). In this way, a total of 50 participants may attend for free and another 50 will have the chance to register for a reduced fee of 300 Euro (all inclusive). The course will have two days of theoretical education on 'highlights in hand surgery' and one cadaveric workshop day involving ten internationally well-known experienced hand surgeons presenting their favourite operations

to small groups the 'masters at work'. The Eastern European course aims to provide the possibility to see and learn from the best. The complete course programme will be available on the IFSSH website and presented during the Antwerp Delegates' Council meeting.

## NEW HORIZONS

The IFSSH ExCo launched a programme to involve societies, hand surgeons from all around the world who still now were not part of our great family. One of the first societies, with a tradition, knowledge and significant history, to be included in this project was the Russian Society for Surgery of the Hand. As a first step the President and Secretary General of IFSSH were invited to discuss the possibility of collaboration in the future with the Russian Society members.

On 14-16 September 2011 an Instructional Course was held entitled 'Topical issues of Hand Surgery' at the St. Petersburg Orthopaedic Institute (1200 beds) under the Directorship of Professor J Kocsis. Professor Igor Golobev, President of the Russian Society for Surgery of the Hand, was responsible for organising the course and the IFSSH was invited to participate in this event. President

Ulrich Mennen and Secretary-General Zsolt Szabo presented some of the lectures and demonstrated surgical procedures in the very well-equipped Department of Anatomy. A group of 150 hand surgeons from around Russia attended this course.

A great interest was shown from both parties to develop a collaboration, and everybody agreed that such events should be continued.

## FUTURE MEETINGS

A detailed list of national and regional hand surgery meetings is available on the IFSSH website. The triennial IFSSH Congresses are as follows:

- XIIth IFSSH - IXth IFSHT Congress - New Delhi, India.
- 4th - 8th March, 2013
- XIIIth IFSSH - Xth IFSHT Congress - Buenos Aires, Argentina
- 2016



**Zsolt Szabo**  
**Secretary General,**  
**IFSSH**  
**Email: [secretary@ifssh.info](mailto:secretary@ifssh.info)**

# Lessons from Julius Casserius: Discoveries and innovations by 17th Century hand surgeon

**Authors:** A. Landi, L. Garagnani, M. Mancini

## A logo with a history

The Italian Society for Surgery of the Hand (Società Italiana di Chirurgia della Mano, SICM) was founded in December 1962. The origin of the logo of SICM has been a subject of much debate. Prof. Augusto Bonola, father of the Modena Hand Surgery school, became the first President of SICM. Neither Prof. Bonola, nor Prof. Ezio Morelli, who was honoured with the title of 'Pioneer of Hand Surgery' by the IFSSH, recall who commissioned the SICM logo and how it was accepted. Also no records can be found in the archives of the SICM.

We reviewed the proceedings of the first meetings of our Society's council in the 'Brown Book' that is kept in the secretariat headquarters in Florence, where the Secretary, Prof. P. Bedeschi (who is also honoured as an

IFSSH 'Pioneer of Hand Surgery'), always accurately recorded the activities of the SICM. Even he makes no mention of the origin of the logo.

The concept of the SICM logo was most likely influenced by Prof. Bonola's environment: the Ospedale Civile (Civil Hospital) Sant'Agostino in Modena, especially by its gate, through which



**Logo of the Italian Society for Surgery of the Hand (SICM).**

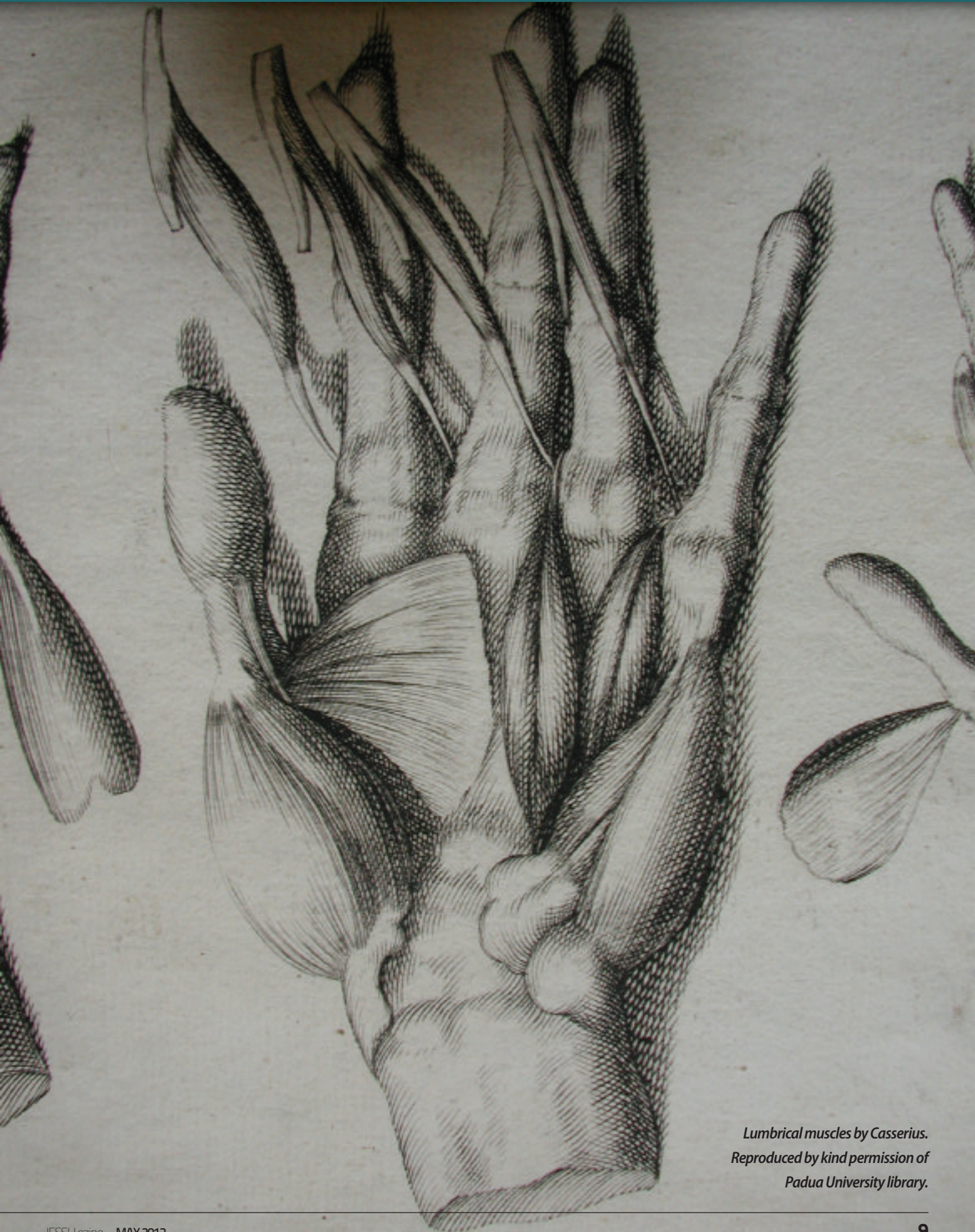he used to enter every morning to reach his clinic (Figure 1).

The SICM logo, which has a simple and graceful geometry, is a copy of the logo on this gate. Underneath this logo is a quotation by Julius Casserius: "Rimatur manus apta manum: mens erue mentem"

This gate, in the entrance hall of the Ospedale Civile di Modena, (Figures 1 and 2) was handcrafted by the blacksmith Giambattista Malagoli of Modena, distinguished craftsman of the 18th century. The logo on this gate was chosen by Prof. Bonola, and he copied it in black on a white background, as the logo for the SICM (Figures 2 and 3)

Julius Casserius, at the age of 39 years, is depicted on the cover page of his first publication, dissecting a hand (Figure 4). The meaning of





*Lumbrical muscles by Casserius.  
Reproduced by kind permission of  
Padua University library.*





**Top left:** The Malagoli gate, main entrance of ex-Hospital Sant'Agostino, Modena.

**Bottom left:** The coping of the gate by Giambattista Malagoli.

**Right:** Front page of "De vocis auditusque organi historia anatomica" by Julius Casserius with the portrait of the Author at the age of 39, in the act of performing a hand dissection. The famous sentence "Rimatur manus apta manum: mens erue mentem" can be found below the portrait.



the sentence which accompanies the image of Casserius is somewhat unclear: "De vocis auditusque organi historia anatomica". Prof. Bonola, in 1960, sought the help from Domenico Melli, Professor of Literature and Latin at LA Muratori Lyceum in Modena, who was an eminent Latinist and literature scholar, (especially on subjects related to Dante, which still remain memorable). He interpreted the sentence as follows: "The skillful hand of the surgeon dissects the hand; the mind supports its comprehension"<sup>1</sup>.

### A keen student

A rare booklet by Dr Giuseppe Sterzi, Professor at Padua Institute of Anatomy, contains one of the most comprehensive and interesting historical researches on Julius Casserius (1552-1616). As a young man, Casserius moved from Piacenza to Padua, probably as a servant for a medical student from Piacenza<sup>1,2</sup>. In his new city he worked as a house servant for

Girolamo Fabrici D'Acquapendente, who was lecturer of Anatomy and Surgery at Padua University. Fabrici used to partially dissect the cadavers before the official demonstrations in the lecture theatre. Casserius, who used to assist him, soon became as skilful as his master. Fabrici supported his young servant's aptitude and helped him become a university student.

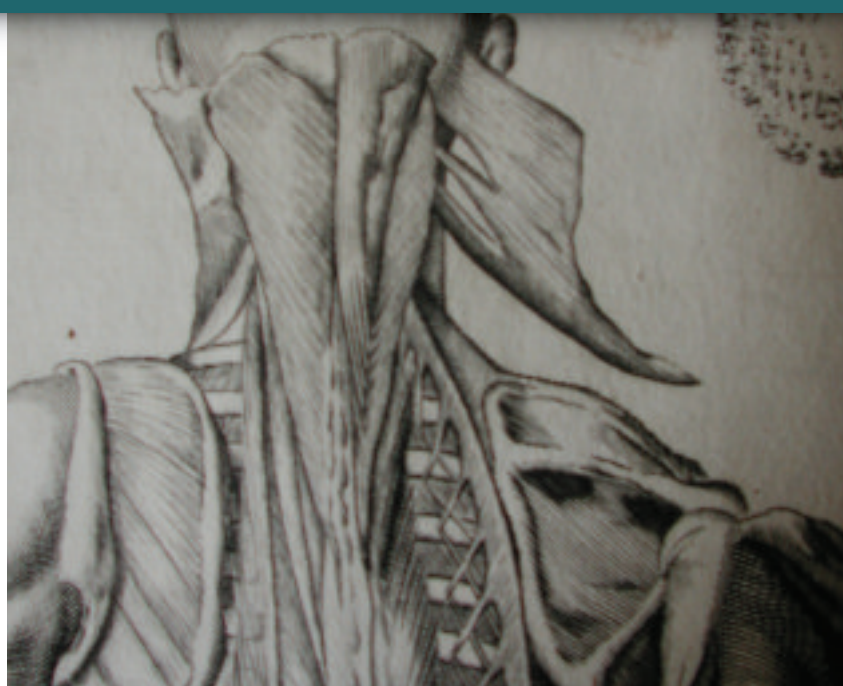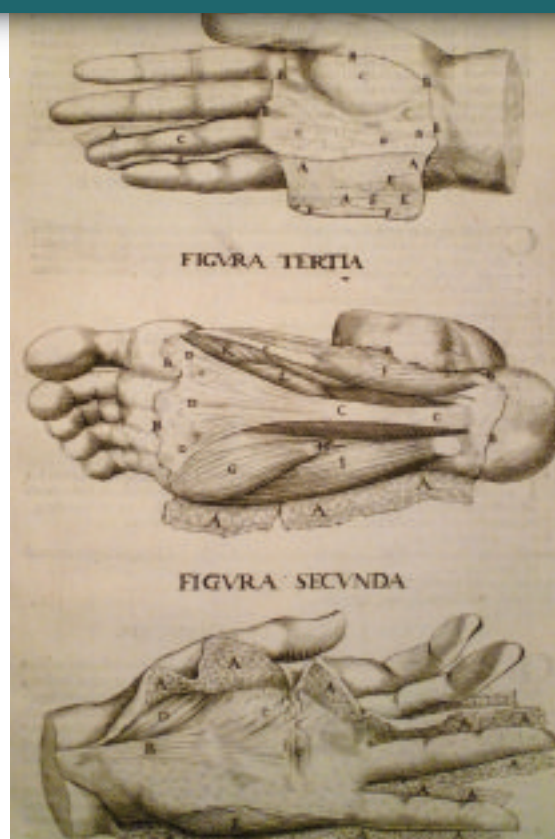
Casserius graduated at Padua University around 1580 after studying Latin and Greek: the knowledge of these subjects constituted a necessary requirement to obtain a degree in Medicine. Casserius started his postgraduate career in Padua, and, unlike Fabrici who was a public man who did not like to expose himself to risks, he was able to create a network for procuring bodies with the connivance of clergymen and gravediggers. The cadavers were stolen from churches before burial, or just after burial. It is true that the judicial authority used to supply the university with bodies, but it

also holds true that two students were selected by the Rector and the Council members of the 'Nations' (national corporations of university students) and given a special mandate to find other cadavers. These students were called 'Massari dell'anatomia' (literally, the farmers of anatomy!).

Casserius managed to dissect a large number of bodies in his own house. He gained respect and was held in high regard by the students and their lobbies, in particular the most powerful one: the Natio Germanica (German Nation). Fabrici had not been able to keep good relationships with this Nation due to the conclusion which he drew following his comparative anatomy studies that the German students would never be able to pronounce Italian well because of anatomical differences!

### Inspired lecturer

Due to ill health, Fabrici's productivity slowed, but, in the beginning of



**Left:** Palmar and plantar cutaneous innervation and aponeuroses according to Casserius. Reproduced by kind permission, private collection.

**Above:** Neck musculature and levator scapulae according to Casserius. Reproduced by kind permission of Padua University library.

the academic year of 1608-9, he managed to dissect the bodies of two hanged men. Casserius had inevitably gained the support of the academic environment. This became more obvious when the 'Collegio dei Riformatori' (Reformers Council) on 25/08/1609 decided to split the teachings of anatomy, which was then allocated to Fabrici, and surgery, which was assigned to Casserius.

Julius Casserius had now become a public lecturer at Padua University. What was still missing was an up to date textbook of anatomy. The university students were forced to study the treatise by Mondino, which was almost three hundred years old.

Casserius hired the Swiss German painter, Joseph Murer, who stayed at his home, and later also Edoardo Fialetti, a painter from Bologna, to create large anatomical drawings. These were engraved by Francesco Valleri, from Veneto. Casserius published three pieces of work: De

**"Julius Casserius's contribution as an anatomist and surgeon rates him amongst the greatest persons of hand surgery, belonging to the scientific community of the hand surgeons of all continents."**

*Reproduced by kind permission of Marciana Library, Venice*

vocis auditusque organis historia anatomica, Pentaestheion, hoc est, De quinque sensibus liber, and Tabulae anatomicae. Even to present day hand surgeons, these works are full of interesting information.

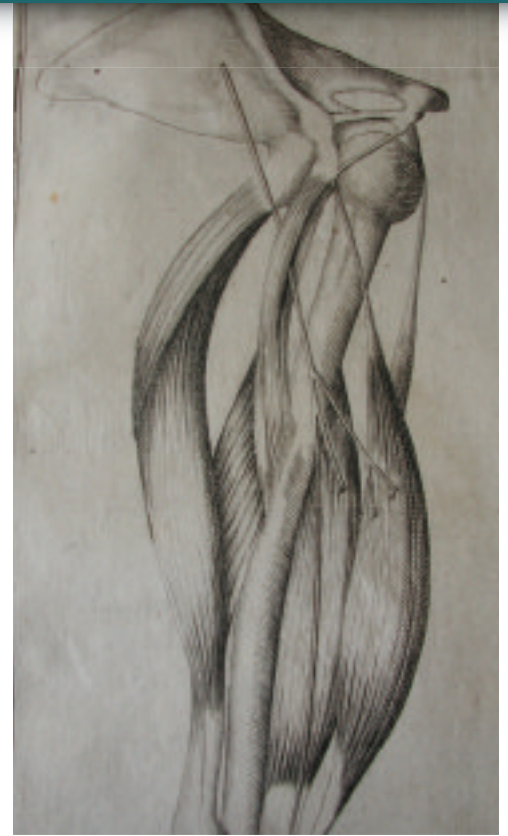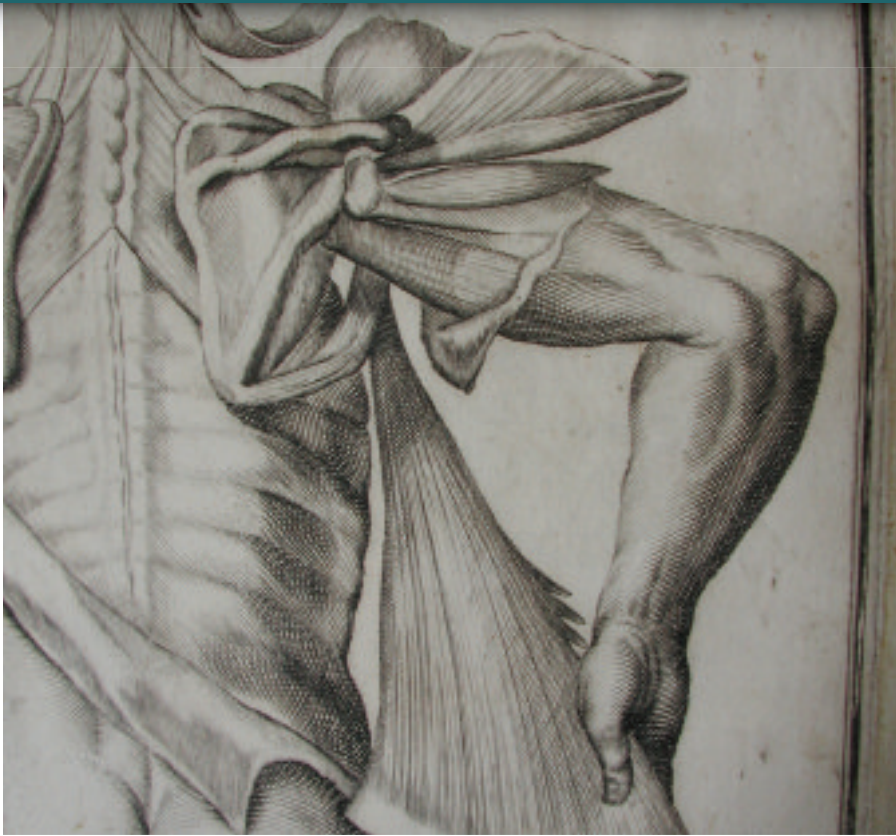Casserius in his Pentaestheion, discusses the key role that is played by the skin and, against the common belief in his times, locates the sense of touch in the dermis instead of the epidermis.

Palmar and plantar aponeuroses are wonderfully represented in two drawings<sup>2</sup> (Figure 5).

Casserius claims that touch is to be considered the fundamental sense from which all others derive, and that all sensations converge to the brain, in line with the statement on the front page.

The main edition of Tabulae anatomicae was printed in Venice in 1627. Sterzi's research on Casserius not only found his last will in the archives of Padua in 1910, but also 51 anatomical charts, some with annotations written by Casserius himself. The eminent





Morgagni owned these charts for some time. They are now kept and preserved in the university library of Padua, where we were able to review them and reproduce the anatomical charts. They most certainly contribute to redefining

the history of upper limb anatomy. These Tabulae represent a magnificent piece of work that has been quoted and discussed by several experts in the history of medicine.

which many of us know as 'perforator of Casserius' (Figure 8), was in fact already known to Vesalius and Colombo. Casserius was the first to provide an accurate representation of the extensor carpi radialis longus (ECRL) and brevis (ECRB) muscles. Canano<sup>3</sup> in his treatise makes an imprecise description of these two muscles. Canano is the author of a rare 'notomia' (notomia meant an accurate and detailed anatomical description) book<sup>4</sup>. Among the many things that have been found in the ex Libreria Contabile in Ferrara, there is a rare copy of his famous book entitled *Musculorum umani corporis picturata dissectio* by Joannis Baptista Cananum Ferrariensis med, with 27 anatomical charts by Girolamo di Carpi. Another copy of this book was brought back to Italy by Vittorio Putti, in 1927. We have been able to review it at the Rizzoli Orthopedic Institute library, with kind permission of the Putti Foundation. This allowed us to better define and

## About the authors

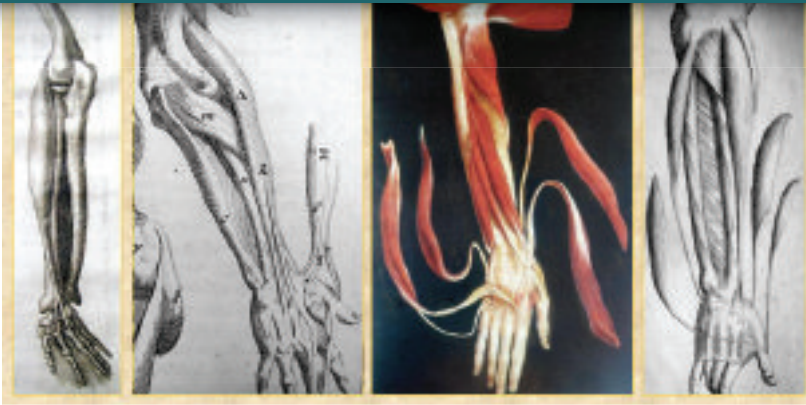- **Landi, Head of the Hand Surgery and Microsurgery Unit, Azienda Ospedaliero-Universitaria Policlinico, Modena, Italy, e-mail: landi.antonio@policlinico.mo.it**
- **L. Garagnani, Hand Surgeon, Hand Surgery and Microsurgery Unit, Azienda Ospedaliero-Universitaria Policlinico, Modena, Italy**
- **M. Mancini, Manager of the Hand Surgery digital archive, Azienda Ospedaliero-Universitaria, Policlinico, Modena, Italy**

### A pioneer in understanding anatomy

The muscles of the back have also been thoroughly described by Casserius, but despite this, their exact anatomy remained largely unknown during the 17th century. The rhomboid muscles, levator scapulae, serratus, splenius capitis, and latissimus dorsi are clearly reproduced here (Figures 6 and 7).

The levator scapulae was named the 'patience' muscle in the 17th century. It is interesting to try and understand the reason behind this nickname: this is most probably because the act of lifting the shoulders was considered alike asking the other person to be patient! The levator was also named after Spigelius, but it is now clear that Casserius described it first.

The musculocutaneous nerve,



**Far left:** Shoulder musculature according to Casserius. Reproduced by kind permission of Padua University library.

**Left:** Musculocutaneous nerve (perforator of Casserius). Reproduced by kind permission of Padua University library.

**Above:** ECRL and ECRB: anatomical description by the Anatomists of the XVI-XVII century. Anatomic drawing by Canano (left) reproduced by kind permission of Fondazione V. Putti and Rizzoli Orthopedic Institute library, Bologna (Dr P. Picci, Dr A. Viganò, P. Tomba).

**Right:** Lumbrical muscles by Casserius. Reproduced by kind permission of Padua University library.



understand the role and greatness of Casserius in the 'vesalian era'. According to the biographer Brunet, this book was printed in 1541, hence it would antecede Vesalius's anatomical drawings<sup>5</sup>. Canano describes extensor carpi radialis longus and brevis as originating from a common muscle belly, with two separate tendons ('Musculus duplici tendine carpu extendens') (Figure 9). The same description was given also by Vesalius and Fabrizio D'Acquapendente<sup>6</sup>. Casserius alone appears to be clear in his mind that these muscles are separate, and that in the case of an anatomical anomaly, even three muscle bellies could be found (Figure 9).

Nancy H. McKee described the structure of these muscles in 2004<sup>7</sup>. Their different architecture was thoroughly analysed: extensor carpi radialis longus is composed by longer fibres at a small angle that makes it ideal for long excursion, while extensor carpi radialis brevis is a wrist stabilizer with a small excursion. Its anatomical

and functional autonomy from its neighbour is the reason why ECRL transfer is the procedure of choice to restore digital flexion in eg. tetraplegia.

The lumbrical muscles have been reproduced by Canano, but accurate comparisons cannot be made with the reproduction made by Fialetti in his anatomical drawing for Casserius (Figure 10). It is interesting to note how the style of the volar representation by Casserius (Figure 10) and the dorsal one by Fabrizio D'Acquapendente (Figure 11) appears almost identical.

In the light of the above reflections one can understand the great respect Bonola had for Casserius and the reasons why he chose Casserius's inscription "Rimatur manus apta manum: mens erue mentem" to be included in the SICM logo. Julius Casserius's contribution as an anatomist and surgeon rates him amongst the greatest persons of hand surgery, belonging to the scientific community of the hand surgeons of all continents.

## REFERENCES:

1. Riva A., Orrù B, Pirino A, Testa Riva F. Iulius Casserius. The self-made anatomist of Padua's Golden age. *The anatomical Record (new anat.)* 2001; 265(4):168-175.
2. Sterzi G. Giulio Casseri: anatomico e chirurgo. Istituto Veneto di Arti Grafiche ed., Venezia, 1909.
3. Canano GB, Girolamo da Carpi. *Musculorum humani corporis picturata dissectio*. Lier ed., Firenze, 1925.
4. Società Medico Chirurgica di Bologna. *Un libro raro di notomia*. Bollettino delle Scienze Mediche 1857; Vol. IV(7):480.
5. Castiglioni A. *Storia della medicina*. Unitas ed., Milano, 1927.
6. Rippa Bonati M. *Manuum munus: per una iconografia del toccar con mano*. In Olivieri A, Rinaldi M and Rippa Bonati M eds, *All'incrocio dei saperi: la mano*, CLEUP ed., Padova, 2004:325-336.
7. McKee N, et al. Extensor carpi radialis longus and brevis: A 3-D study of musculotendinous architecture. *American Society for Peripheral Nerve Annual Meeting, Rancho Mirage, CA, USA, January 17-18, 2004*. Abstract published on *J Reconstr Microsurg*, 2004; 20:340.

# Pain guided hand therapy for hand fractures: the Saint John Protocol

**Authors:** D. Lalonde MD, FRCSC, A. Higgins BSc. OT

Dr D Lalonde (hand surgeon) and Ms Amanda Higgins (hand therapist) work at the St John Hospital in New Brunswick, Canada. They have developed an early protective motion rehabilitation protocol for patients with fractures of the hand. This protocol was developed to prevent long bouts of immobilisation and prevent finger stiffness. The results have been very good. Amanda shares their protocol with members of the hand rehabilitation team

## Introduction

Early controlled mobilisation of tissues surrounding a healing fracture has the potential to enhance the quality and rate of fracture healing and therefore improve the functional range of motion of the hand<sup>1</sup>. Early mobilisation has certainly been accepted as the treatment of choice for flexor tendon repair. This is well-supported by the Cochrane review on this subject<sup>2</sup>.

The risk of tendon rupture has not dampened the interest in early

protected movement for flexor tendon repair. This is because it is widely accepted that early protected movement of the finger results in improved mobility. Other protocols did not give similar results and many fingers became stiff when other tendon rehabilitation protocols were used. All therapists know that a stiff finger is a useless finger<sup>3,4</sup>.

Although there is a risk of loss of finger fracture reduction with early protected movement, it is generally accepted that this is much easier to repair than a ruptured tendon.

The following protocol of early protected movement for finger fractures has been developed over many years in our unit with good success. Success was measured based on the following:

- Patient's functional range of motion
- Patient satisfaction
- Surgeon and therapist satisfaction.

Using this protocol, we have found that the patients' fingers remain supple and stiffness has been avoided. Loss of fracture reduction has been minimal.

The protocol is based on two guiding principles:

1. Early protected movement is just as important in finger and metacarpal fractures as it is in flexor tendon repair. The reason is the same: stiff fingers are not an acceptable good result. In our experience, the risk of clinically significant loss of fracture reduction with this protocol has been lower than the risk of tendon rupture in early protected movement with flexor tendon repair.
2. The patients should be off all analgesics, so that they are guided by their pain. If it hurts, they may be doing damage. This may result in the loss of fracture reduction.

We tell our patients the following:

"We did not spend two billion years evolving pain because it is not good for us. It is nature's only way for our bodies to tell us: "Hey, don't do that; I'm trying to heal in here!". Get off of all pain killers including acetaminophen and ibuprophen as soon as possible, and let your pain tell you what you can



and cannot do. Your body is very clever and it will let you know when you are pushing it. If you listen to your body, you will get better faster"

This concept is well understood and accepted by all our patients.

Amanda Higgins has submitted an extensive protocol, which covers fractures of all the bones of the hand. The principles are the same. The following early protected motion protocol has been worked out for fractures of the proximal phalanx.

## 1. Proximal Phalanx Fracture

- Can be unfixated or k-wire fixated. If there is a K wire, determine when k-wire needs to be removed with surgeon. K wires are usually removed when the fracture is no longer tender to palpation and the patient is off of analgesics.
- There is not much point in moving fractures in the first 2-3 days after injury, as collagen formation does not start until day 3. Besides, very early movement will cause bleeding, which will generate more scar and callus.



- Treat oedema with Coban until the finger is no longer swollen
- Let the pain of the fracture be the main guide for allowing movement during the healing phase, unless the patient is unreliable. No movement is allowed while the patient is on analgesics. The hand is kept elevated. Once the patient is completely off analgesics, he is allowed to move the finger, but he is not allowed to use it. If he does something that hurts significantly, he should not try that again for 2-3 days. When it no longer hurts to move it, he can use it. The rule is: Don't baby it but don't do what hurts.
- If the fracture is unstable or if unsure when to start ROM, discuss with surgeon.
- If stable fracture with no K wire, then buddy tape finger to neighbouring finger and start early active ROM when patient is off analgesics. He should just move it but not use it stressfully in activities of daily living. It should not hurt him to move it. The pain guides the movement. Buddy tape until no longer sore to use the finger, which is usually 2-3 weeks. Re-assess the patient at 7 days to be sure there is no unacceptable rotation (scissoring) or angulation at the fracture site.
- If unstable fracture with no K wire, or fracture with a K wire, safest is to elevate hand and splint MP in flexion and PIP in extension until the fracture is no longer hurting with gentle finger movement with the patient off all analgesics (usually 3-10 days). If there are no K wires across joints, actively move

any or all of the MP, PIP and DIP joints as much as possible while stabilising the proximal and/or middle phalanges with the fingers of the other hand. A splint may be used to stabilise the proximal phalanx. The patient is allowed to do this movement frequently (up to hourly) as long as

- he is off all analgesics,
- he is just moving it but not using it stressfully with activities of daily living,
- it does not hurt him to move it.

The pain guides the movement.

Splint the MP and/or PIP joints during possible stress activities of daily living and during sleep. Re-assess the patient at 7 days to be sure there is still no unacceptable rotation (scissoring) or angulation of the fracture. A splint is no longer required when it does not hurt to use the finger, which is usually 2-4 weeks post injury or reduction. It may be that the intermittent splinting described above will only need to immobilise one of the MP or PIP joints (and not both joints). Be guided by the patient's pain. The DIP should always be kept actively moving from day 2-3 onward. This will help to keep the flexor digitorum profundus gliding. Continue with active ROM exercises, 10 reps every waking hour. If joint mobility does not improve with active ROM, add passive ROM exercises at 4 weeks.

- Subluxed intra-articular fractures of the MP or PIP are all treated individually and will require surgeon guidance. These may require a Schenk, Banjo, or other distraction splint. The surgeon will let you know. He will insert a K-wire, which will pass through the

head of the middle phalanx distal to the fracture site. You will have to fabricate banjo splint to hook onto this k-wire. The patient will usually wear this splint full time for six weeks. Bring back to clinic for 6 week follow up (if not seen earlier).

- When the fracture is solidly healed, usually at 6-10 weeks, forceful very frequent active movement (several times per hour with sustained holding and the patient counting to 10), to get the last few degrees of ROM, can be initiated. At this point, pain is allowed as it is no longer the pain of fracture fragments moving, but it is the pain of stretching shortened ligaments. If frequent forceful active movement is not improving joint mobility after 4 weeks, passive forces may be applied.

The full protocol, covering fractures of the distal and middle phalanges and metacarpals, is available from Amanda Higgins at [grashay@nb.sympatico.ca](mailto:grashay@nb.sympatico.ca)

## References

1. Feehan, L. Early controlled mobilization of potentially unstable extra-articular hand fracture. *Journal of Hand Therapy* Volume 16, Issue 2, Pages 161-170.
2. Thien TB, Becker JH, Theis JC. Rehabilitation after surgery for flexor tendon injuries in the hand. *Cochrane Database Syst Rev.* 2004 Oct 18;(4)
3. Higgins, A, Lalonde, DH, Bell, M, McKee, D, Lalonde, J. Avoiding flexor tendon repair rupture with intraoperative total active movement examination. *Plast Reconstr Surg* 2010. 126(3):941-945
4. Tang JB. Indications, methods, postoperative motion and outcome evaluation of primary flexor tendon repairs in Zone 2. *J Hand Surg (European Volume)* 2007; 32E : 2 :118-129.



IFSSH 2010 SEOUL  
13th Triennial Congress of the International Federation of  
Societies for Surgery of the Hand  
October ~ 4 November 2010 | Sheraton Grand Walkerhill Hotel, Seoul, Korea



## For the members by the members...

The **IFSSH ezine** is created with the intention of engaging the global hand surgery community and to promote the profession through the sharing of knowledge.

In order for the IFSSH ezine to remain relevant and topical, we rely on you, our readers, to:

- Subscribe to receive the ezine  
FREE OF CHARGE 4 times per year
- Submit letters to the editor
- Provide us with feedback about the ezine

**CLICK HERE**  
TO COMPLETE A  
5 MINUTE SURVEY  
ABOUT THE  
IFSSH EZINE



# Pioneers in Hand Surgery

## IFSSH Pioneer profile:

### Professor Erik Moberg

Professor Moberg's work and observations, particularly his studies on sensitivity in the hand and its importance for function, have been recognised and honored for many years. The objective methods that he developed to determine the functional value of sensitivity in the hand are used everywhere by Hand Surgeons and have stimulated



continuing research for improved methods of nerve repair. His concise and accurate descriptions of diseases and injuries of the hand are classical. He trained many Hand Surgeons in Sweden and worldwide through his participation in numerous international symposia.

Professor Moberg was born in Lund, Sweden. He received his Medical Doctorate and his PhD degree from the University of Lund where he became Assistant Professor of Experimental Pathology. He was later appointed Assistant Professor of General Surgery at the University of Göteborg (1945). In 1946, Professor Moberg created the first Department of Hand Surgery in Scandinavia at the University of Göteborg. He further studied Hand Surgery in the United States under the aegis of Drs. Sterling Bunnell, Sumner L. Koch, Allen Kanavel, Michael L. Mason, and Harvey S. Allen in 1947. He was appointed Professor of Orthopaedic and Hand Surgery at the University of Göteborg in 1958.

Professor Moberg had the honor to deliver the first Sterling Bunnell Memorial Lecture in San Francisco in 1962. He was President of the Swedish Surgical Society in 1968. He was a founding member of the Scandinavian Society for Surgery of the Hand and of the International Federation of Societies for Surgery of the Hand which he served as first President in 1968-1969. Professor Moberg was a Visiting Professor at the University of California (Irvine) and arranged International Conferences on the Surgical Rehabilitation of the Upper Limb in Tetraplegia in Edinburgh (1978) and Giens, France (1984).

Professor Moberg was honorary or corresponding member of 15 medical societies abroad and in Sweden. He published many books and articles in the field of Hand Surgery and Medicine.

Professor Moberg loved the sea and was an avid sailor. He and his wife Marta resided in Göteborg, Sweden.

## IFSSH Pioneer profile:

### Professor Johan MF Landsmeer

Professor Johan Matthijs (Hans) Landsmeer dedicated his career to Basic Sciences and especially to the Anatomy or Human Morphology as applied to Hand Surgery. He made enormous contributions to the understanding of the function of the hand, its deformities, and the biomechanical and anatomical basis for its action. His thorough investigations on the precise anatomical basis for movement have made his work recognised and appreciated worldwide.

Professor Landsmeer was a native of Rotterdam, Holland and obtained his Doctorate in Medicine in 1947. In 1960, he was appointed Professor at the Department of Anatomy and Embryology of the University of Leiden. He was appointed Consultant in Hand Anatomy on the project of the Ampersand Research Group (Charles Long, Director, Cleveland, Ohio), and also at the Hospital for Joint Diseases, New York. Professor Landsmeer gave the Founders Lecture at the annual meeting of the American Society for Surgery of the Hand in 1965. In 1976 his work as anatomist was published in: Landsmeer's Atlas of Anatomy



of the Hand. Professor Landsmeer was Chairman of the International Committee of the "International Conference on Biomechanics and Clinical Kinesiology of Hand and Foot" held in Madras, India in 1985. He was the Guest Professor Anatomy at the Kasturba Medical College, Manipal, India (1986).

Professor Landsmeer was an honorary member of the American,

British, and Dutch Societies for Surgery of the Hand. He was a member of the French and of the Argentinian Societies for Surgery of the Hand and of the Anatomical Society of Great Britain and Ireland. Professor Landsmeer was the author of many scientific publications.

He and his wife Annelies resided in Oegstgeest, The Netherlands.

# Differing approaches to rheumatoid hand surgery in the United Kingdom

## United Kingdom

A recent study, led by Professor Frank Burke from the Pulvertaft Hand Centre at the Derbyshire Royal Infirmary in Derby, aimed to assess the differences in perception about rheumatoid hand surgery between rheumatologists, hand surgeons and hand therapists in the UK. The team used a postal questionnaire to assess commonly performed rheumatoid hand operations and for each procedure, respondents rated the most important indication for surgery and scored effectiveness at reducing pain, improving function and aesthetics, and preventing deformity.

"The reason we undertook the study was to see if there was a consistent view on the outcomes of eight surgical procedures for the rheumatoid hand amongst surgeons, rheumatologists and hand therapists.

Studies in America showed rheumatologists and hand surgeons had fairly widely differing views on the outcome of these procedures. This inevitably leads to significantly differing advice on specific procedures, depending on the speciality of the doctor offering the advice," Professor Burke explained.

Statistically significant differences were found between all three groups with regards to expected outcome and main indications for surgery.

"Attitudes between specialities in the UK was less polarised than in the USA with the therapists by and large holding opinions between the two medical groups. To some extent that situation was more reassuring

for patients, but it is clear that more work needs to be done in terms of better outcome assessment for these procedures and sharing those results with healthcare workers who advise rheumatoid patients," Burke concluded.

**"more work needs to be done in terms of better outcome assessment for these procedures and sharing those results with healthcare workers who advise rheumatoid patients"**

## JOURNAL REFERENCE

Rheumatoid hand surgery: differing perceptions amongst surgeons, rheumatologists and therapists in the UK (J Hand Surg Eur Vol October 2011 vol. 36 no. 8 632-641)



# Anatomy and function of lumbrical muscles

## Israel

In a recent paper in *Hand Clinics*, Dr Mordechai Vigler from the Department of Orthopaedic Surgery at the Rabin Medical Center in Israel, conducted a study to better understand the relationship between the lumbrical muscle anatomy and the significant impact on hand and digit function.

"The lumbrical muscles are unique having both origin and insertion on tendon. No other muscle in the human body shares the same characteristic," Dr Vigler explains.

For Vigler, the most important observations of the study from an anatomical point of view, are the highly specialised architectural properties including small physiologic cross-sectional area but long fibre length, which indicate that the lumbricals are important in fast, alternating movements and fine-tuning motion. "Modern society habits today, involve chronic repetitive digit motion such as prolonged typing. The lumbricals play an important role in such activity. Better understanding of their anatomy and function may assist patients having difficulty performing prolonged, repetitive tasks," he Vigler added.

He believes it is essential for hand surgeons to understand how the lumbricals assist in metacarpophalangeal joint flexion and contribute to interphalangeal joint extension. Secondly, from a functional point-of-view, the role of the lumbricals in performing fast, alternating movements and fine-tuning motion.

Future research will involve understanding better the relationship between the lumbricals and the interossei muscles in regard to the unique functional ability of the human hand and digits.

**"Better understanding of their anatomy and function may assist patients having difficulty performing prolonged, repetitive tasks"**

## JOURNAL REFERENCE

Anatomy and function of lumbrical muscles, Ram Palti, MD, Mordechai Vigler, MD. *Hand Clinics*: February 2012 (Volume 28, Issue 1)



# Anatomy and function of the thenar muscles

## USA

Dr Salil Gupta, from the Department of Orthopedic Surgery at the NYU-Hospital for Joint Diseases in New York, recently wrote the paper to provide a review of the anatomy and function of the thenar muscles for hand surgeons and training surgeons.

The four thenar muscles make up the intrinsic muscles of the thumb. They include the abductor pollicis, adductor pollicis, opponens pollicis, and flexor pollicis brevis. Thumb motion is facilitated through the coordination of these intrinsic muscles. The thumb musculature dynamically allows for precision pinching and power gripping.

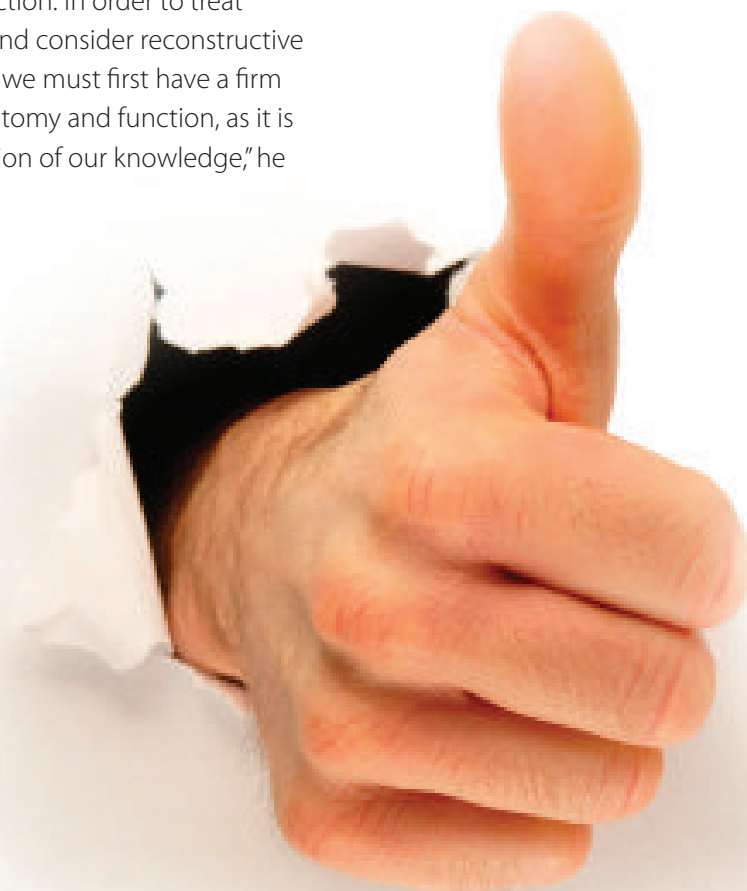"I was surprised to learn of the great variability in the innervation of the thumb intrinsic muscles as well as the vast number of anatomic variations present in the thenar region. In addition, I was impressed by the intrinsic muscle contribution to the interphalangeal joint extension," Dr Gupta explained.

Gupta believes it is important to understand the anatomy as it pertains to muscle position within the hand as well as to function. In addition, it is critical to understand the relationship to the neurovascular structures. "The mobility of the thumb is critical to hand function. To understand the physiological anatomy only helps further our understanding of hand function. In order to treat pathology and consider reconstructive procedures, we must first have a firm grasp of anatomy and function, as it is the foundation of our knowledge," he concluded.

**"To understand the physiological anatomy only helps further our understanding of hand function"**

## JOURNAL REFERENCE

Anatomy and Function of the Thenar Muscles, Salil Gupta, MD, Heidi Michelsen-Jost, MD in *Hand Clinics*: February 2012 (Volume 28, Issue 1)



# Journal Highlights

Below is a selection of contents pages from the latest issues of the following leading hand surgery journals. Hover your mouse over each article heading and click to go to the original abstract page of the article.

## Hand Clinics

**Latest issue is: Volume 28 ■ Issue 1 February 2012**

- Anatomy and Function of the Thenar Muscles Salil Gupta, Heidi Michelsen-Jost
- The Interosseous Muscles: The Foundation of Hand Function Frederic E. Liss
- Anatomy and Function of Lumbrical Muscles Ram Palti, Mordechai Vigler
- Anatomy and Function of the Hypothenar Muscles John A. Pasquella, Pam Levine
- Restoration of Opposition Martin A. Posner, Deepak Kapila
- Restoration of Pinch in Intrinsic Muscles of the Hand Steve K. Lee, Jamie R. Wisser
- Correction of the Claw Hand Anthony Sapienza, Steven Green
- Intrinsic Contractures of the Thumb Jack Choueka, Susan Craig Scott
- Intrinsic Contractures of the Hand Nader Paksima, Basil R. Besh
- Hand Therapy for Dysfunction of the Intrinsic Muscles Monica Seu, Michele Pasqualetto

**Coming soon**

## Journal of Wrist Surgery

**Editor in Chief: Dr David Slutsky, MD, Assistant Clinical Professor, Department of Orthopaedic Surgery, UCLA School of Medicine, Los Angeles, CA**

**CLICK HERE TO FIND OUT MORE**

## Hand

**Volume 7 / 2012**

- Epithelioid hemangioendothelioma of the pisiform Isidre A. Gracia, Ignacio R. Proubasta, Ana I. Peiró, Laura T. Trullols and Jaume Llauger, et al.
- Early versus delayed imaginal exposure for the treatment of posttraumatic stress disorder following accidental upper extremity injury Jo M. Weis, Brad K. Grunert and Heidi Fowell Christianson
- Re: End-of-skin grafts in syndactyly release: description of a new flap for web space resurfacing and primary closure of finger defects Kresimir Bulic
- Spindle cell hemangioma reoccurrence in the hand: case report Sylvia S. Gray, Mahmoud A. Eltoky, Roy F. Riascos and Richard D. Montilla
- Patient-reported outcomes after acute carpal tunnel release in patients with distal radius open reduction internal fixation Aakash Chauhan, Timothy C. Bowlin, Alexander D. Mih and Gregory A. Merrell
- Management of digital tendon avulsion at the musculotendinous junction of the forearm: a systematic review Jessica Collins, Yoshihiro Ishihara and Achilles Thoma
- Nonsurgical treatment of Dupuytren's contracture: 1-year US post-marketing safety data for collagenase clostridium histolyticum C. A. Peimer, C. A. McGoldrick and G. J. Fiore
- Wrong site surgery – where are we and what is the next step Tyson K. Cobb
- Moberg Modification using the first web space: thumb reconstruction following distal amputation Stéphanie Thibaudeau, Dominique M. Tremblay, Michèle Tardif and André Chollet
- Psychological factors predict unexpected diagnoses Ana-Maria Vranceanu and David Ring
- The free lateral arm flap – a reliable option for reconstruction of the forearm and hand M. Sauerbier, G. Germann, G. A. Giessler, M. Sedigh Salakdeh and M. Döll
- High impact articles in hand surgery Kyle R. Eberlin, Brian I. Labow, Joseph Upton and Amir H. Taghinia



## Hand surgery: Asia Pacific

### Volume 17, Issue 1 2012

■ Simultaneous Gradual Lengthening of Proximal and Distal Nerve Stumps for Repair of Chronic Peripheral Nerve Defect in Rats. Yoshiko Nakajima, Yasumasa Nishiura, Yuki Hara, Sharula and Naoyuki Ochiai

■ Role of the Hyaluronan-Producing Tenosynovium in Preventing Adhesion Formation During Healing of Flexor Tendon Injuries Masaharu Yagi, Yasuhiro Mitsui, Masafumi Gotoh, Naoto Sato, Kenji Yoshida and Kensei Nagata

■ Alteration of the End-Plane Angle in Press-Fit Cylindrical Stem Radial Head Prosthesis: An In Vitro Study - Suriya Luenam, Piti Chalongviriyalert, Arkaphat Kosiyatrakul and Chusak Thanawattano

■ Prevention of Instability of the Proximal End of the Radius after Radial Head Resection Using an Anconeus Muscle Flap Kinya Nishida, Norimasa Iwasaki, Tadanao Funakoshi, Makoto Motomiya and Akio Minami

■ Radial Head Dislocation as a Rare Complication of Obstetric Brachial Plexus Palsy: Literature Review and Five Case Series – Cecilia W. Huo

■ Open Extensor Tendon Injuries: An Epidemiologic Study – Dominic Patillo and Ghazi M. Rayan

■ Extensor Tendo Rupture in Rheumatoid Arthritis: A Survey of Patients Between 2005 and 2010 at Five Korean Hospitals - Hyun Sik Gong, Joon Oh Lee, Goo Hyun

## Journal of Hand Surgery: American volume

### Volume 37, Issue 4, April 2012

■ Opioid Consumption Following Outpatient Upper Extremity Surgery Jeffrey Rodgers, M.D, Kimberly Cunningham, Keely Fitzgerald, Edward Finnerty

■ Results of Needle Aponeurotomy for Dupuytren Contracture in over 1,000 Fingers Gary M. Pess, Rebecca M. Pess, Rachel A. Pess

■ Surgical and Nonsurgical Treatment of Cubital Tunnel Syndrome in Pediatric and Adolescent Patients Christopher M. Stutz, Ryan P. Calfee, Jennifer A. Steffen, Charles A. Goldfarb

■ Arthroscopic Ulnar Nerve Decompression in the Setting of Elbow Osteoarthritis – Rudy Kovachevich, M.D., Scott P. Steinmann, MD

■ Radial Nerve Injury During Double Plating of a Displaced Intercondylar Fracture - Rebecca Lim, Shian Chao Tay, Andrew Yam

■ Lateral Antebrachial Cutaneous Neuropathy Following the Long Head of the Biceps Rupture – David M. Brogan, Allen T. Bishop, Robert J. Spinner,

Alexander Y. Shin

■ Simultaneous Intercostal Nerve Transfers to Deltoid and Triceps Muscle Through the Posterior Approach - Kanchai Malungpaishrope, Somsak Leechavengvongs, Kiat Witoonchart, Chairaj Uerpairojkit, Artit Boonyalapa, Disorn Janesaksrisakul

■ Functional Outcome of Glenohumeral Fusion in Brachial Plexus Palsy: A Report of 54 Cases Franck Atlan, Sébastien Durand, Michael Fox, Pierre Levy, Zoubir Belkheyr, Christophe Oberlin

■ Carpal Tunnel Release Using the MANOS CTR System: Preliminary Results in 52 Patients Bruce McCormack, William Bowen, Stephen Gunther, Jonathan Linthicum, Michael Kaplan, Edward Eyster

■ Palmaris Profundus Tendon Prohibiting Endoscopic Carpal Tunnel Release: Case Report - Walter B. McClelland Jr, Kenneth R. Means Jr Walter B Mc Clelland Jr, MD, Kenneth R. Means Jr

■ Early Trapeziometacarpal Osteoarthritis: A Biomechanical Investigation of Radial

Subluxation, Contact Area, and Contact Pressure Tahseen Cheema, MD, Christina Salas, MS, Nathan Morrell, MD, Letitia Lansing, MD, Mahmoud M. Reda Taha, PhD, Deana Mercer, MD

■ Innervation Patterns of Thumb Trapeziometacarpal Joint Ligaments Elisabet Hagert, MD, PhD

■ Percutaneous Screw and Axial Kirschner Wire Fixation for Acute Transscaphoid Perilunate Fracture Dislocation Ying-Chao Chou, MD, Yung-Heng Hsu, MD, Chun-Ying Cheng, MD, Chi-Chuan Wu, MD

■ The Mechanism of Ulnar-sided Perilunate Instability of the Wrist: A Cadaveric Study and 6 Clinical Cases Peter M. Murray, MD, Christopher G. Palmer, MD, Alexander Y. Shin, MD

■ Ulnar Variance: Its Relationship to Ulnar Foveal Morphology and Forearm Kinematics - Toshiyuki Kataoka, MD, Hisao Moritomo, MD, PhD, Shohei Omokawa, MD, PhD, Akio Iida, MD, Tsuyoshi Murase, MD, PhD, Kazuomi Sugamoto, MD, PhD

■ Use of Standard and Anatomic-Tilt

Baek, Byung Sung Kim, Jin Young Kim, Jae Seong Lee and Choel Ho Song

■ The Carpal Stretch Test at the Rheumatoid Wrist - Hiroyuki Shimizu, Moroe Beppu, Kazuhiko Matsusita, Takeshi Arai and Noriyuki Yoshida

■ The Current Practice of the Management of Little Finger Metacarpal Fractures – A Review of the Literature and Results of a Survey Conducted Among Upper Limb Surgeons in the United Kingdom - A. Sahu, S. S. Gujral, S. Batra, S. P. Mills and M. S.

Srinivasan

■ Curettage and Calcium Phosphate Bone Cement Injection for the Treatment of Enchondroma of the Finger - Jae Kwang Kim and Nam Ki Kim

■ Negative Pressure Therapy with Irrigation for Digits and Hands: Pressure Management and Clinical Application - Yuki Matsushita, Masao Fujiwara, Takeshi Nagata, Tatsuya Noda and Hidekazu Fukamizu

■ Preventing Postoperative Congestion in Reverse Pedicle Digital Island Flaps When Reconstructing Composite Tissue Defects in the Fingertip: A Patient Series - Hironori Matsuzaki, Hisao Kouda and Haruyoshi Yamashita

Lateral X-rays to Determine Distal Radius Volar Angulation - Ju Won Yi, MD, Rag Gyu Kim, MD, Jin Ha Choi, MD, Jae Kwang Kim, MD, PhD

■ Comparison of 2 Forearm Reconstructions for Longitudinal Radioulnar Disassociation: A Cadaver Study - Christopher M. Jones, MD, , Check C. Kam, MD, E. Anne Ouellette, MD, MBA, Edward L. Milne, BSc, David Kaimrajh, MS, Loren L. Latta, PhD

■ Radiocapitellar Cartilage Injuries Associated With Tennis Elbow Syndrome - Koichi Sasaki, MD, Kazunori Onda, MD, Gosuke Ohki, MD, Tomoko Sonoda, DDS, Toshihiko Yamashita, MD, Takuro Wada, MD

■ Radiographic Arthrosis After Elbow Trauma: Interobserver Reliability - Anneluuk Lindenhovius, MD, PhD, Paul Jack Karanicolas, MD, PhD, Mohit Bhandari, MD, MSc, David Ring, MD, PhD

■ Metacarpal Hypoplasia Associated With Congenital Constriction Band Syndrome - Hiroshi Satake, MD, PhD, Toshihiko Ogino, MD, PhD, Kousuke Iba, MD, PhD, Tadayoshi

Watanabe, MD, Jun Eto, MD

■ Long-term Donor Site Morbidity After Free Nonvascularized Toe Phalangeal Transfer - Lorenzo Garagnani, MD, Marc Gibson, MBBS, Paul J. Smith, MBBS, Gillian D. Smith, MBBS

■ Radiation Therapy for Infiltrative Giant Cell Tumor of the Tendon Sheath - Christopher J. Coroneos, MD, Brian O'Sullivan, MD, Peter C. Ferguson, MD, Peter W. Chung, MD, Dimitri J. Anastakis, MD

■ Recurrence of a Giant Cell Tumor of the Hand After 42 Years: Case Report - Keith Jackson, MD, Charles Key, MD, Michelle Fontaine, MD, Richard Pope, MD

■ Cutaneous Mucormycosis of the Upper Extremity in an Immunocompetent Host: Case Report - Kyle D. Lineberry, BS, Adam K. Boettcher, MD, Andrew L. Blount, MD, Scott D. Burgess, MD

■ Multiple Neurilemmomas in Birt-Hogg-Dubé Syndrome: Case Report Kevin J. Renfree, MD, Kara L. Lawless, BS

■ The Effect of Botulinum Neurotoxin-A on

Blood Flow in Rats: A Potential Mechanism for Treatment of Raynaud Phenomenon - Austin V. Stone, MD, L. Andrew Koman, MD, Michael F. Callahan, PhD, Delrae M. Eckman, PhD, Beth P. Smith, PhD, Johannes F. Plate, MD, Thomas L. Smith, PhD

■ Nonoperative Management of Scleroderma of the Hand With Tadalafil and Subatmospheric Pressure Wound Therapy: Case Report - Ronak M. Patel, MD, Daniel J. Nagle, MD

■ Conservative Management of Dieterich Disease: Case Report Malin D. Wijeratna, MBBS, BSc, James A. Hopkinson-Woolley, MBBS, MSc

■ Magnetic Resonance Imaging in Evaluating Workers' Compensation Patients - Daniel Babbel, Ghazi Rayan



## Journal of Hand Surgery (European Volume)

### May 2012 J Hand Surg Eur Vol 37, Issue 4

■ Joint replacement in 131 painful osteoarthritic and post-traumatic distal interphalangeal joint Sierakowski, C. Zwiefel, M., Sirotakova, S. Sauerland and D. Elliot

■ Relative contribution of tissue oedema and the presence of an A2 pulley to resistance to flexor tendon movement: an in vitro and in vivo study Y.F. Wu, Y.L. Zhou and J.B. Tang

■ The effect of core suture flexor tendon repair techniques on gliding resistance during static cycle motion and load to failure: a human cadaver study T. Moriya, M.C Larson, C. Zhao, K.-N. An, and P.C. Amadio

■ Simultaneous powering of forearm pronation and key pinch in tetraplegia using a single muscle-tendon unit J. Fridén, C. Reinholdt, A. Gohritz, W.J. Peace, S.R. Ward and R.L. Lieber

■ Finger replantations after ring avulsion amputations K. Özaksar, T. Toros, T.S. Sığün, M. Kayalar, I. Kaplan, and S. Ada

■ Trabecular microstructure of the human lunate in Kienböck's disease K.-J. Han, J. Y. Kim, N.-S. Chung, H. R. Lee, and Y. S. Lee

■ Experience of using the bioresorbable copolyester poly(DL-lactide-ε-caprolactone) nerve conduit guide Neurolac™ for nerve repair in peripheral nerve defects: Report on a series of 28 lesions S. Chiriac, S. Facca, M. Diaconu, S. Gouzou, P. Liverneaux

■ A randomised controlled trial of absorbable versus non-absorbable sutures for skin closure after open carpal tunnel release C. Theopold, S. Potter, M. Dempsey, and M. O'Shaughnessy

■ The effect of radial osteotomy on the position of the posterior interosseous nerve J.M. Itamura, S.A. Papadakis, E. Ziv, S. Vaishnav, N. Roidis

## Journal of Hand Therapy

### Volume 25, Issue 2, April 2012

■ Understanding the Biomechanical Nature of Musculoskeletal Tissue - Andrew R. Karduna

■ Specialized Connective Tissue: Bone, the Structural Framework of the Upper Extremity – Alyssa M. Weatherholt, Robyn K. Fuchs, Stuart J. Warden

■ Tendon Biomechanics and Mechanobiology – A mini review of Basic Concepts and Recent Advancements - James H-C Wang

■ Target-focused Exercise Regime: A Motivational Strategy to Improve Patient's Adherence to Treatment of a Stiff Thumb Interphalangeal Joint - G. Sudhagar, Monique LeBlanc

■ Using the "Visual Target Grip Test" to Identify Sincerity of Effort during Grip Strength Testing – Orit Schechtman, PhD OTR/L, Bhagwant S. Sindu, PhD OTR/L, Paul W. Davenport, PhD

# Upcoming events

## 22nd ETRS Meeting by the European Tissue Repair Society (ETRS)

**Date:** October 4th -5th, 2012

Venue: Royal Olympic Hotel (Across the Ancient Temple of Zeus)

**Host city:** Athens

The meeting will be hosted in Athens, a city of great importance since ancient times for culture, philosophy and scientific thinking. Strolling through Athens, the visitor discovers this rich history as Ancient, Roman, Byzantine and modern monuments abound. Take advantage of this unique feature and enjoy a trip into the course of history.

**Host country:** Greece

The country is considered to be the birthplace of modern western culture and democracy. In addition to rich historical offerings, Greece has gorgeous coastlines and mountains.

[www.etr2012.org](http://www.etr2012.org)

## 12th Triennial Congress of the IFSSH and 9th Triennial Congress of the IFSHT

**Date:** 4th – 8th March 2013

**Location:** New Delhi, India





