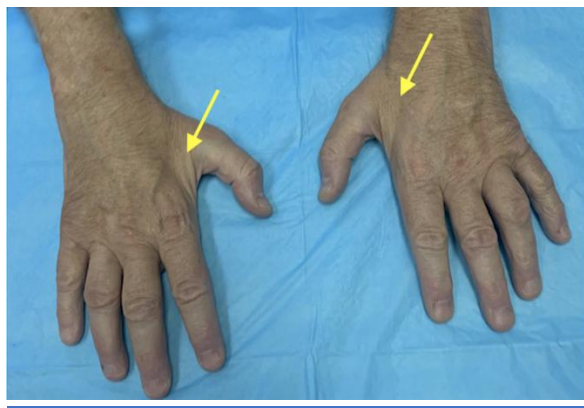




Hand Surgery Source ©

Version 2.0!

Check out this free educational web site from
Hand Surgery Resource at:
www.handsurgeryresource.com



Charcot Marie Tooth Disease

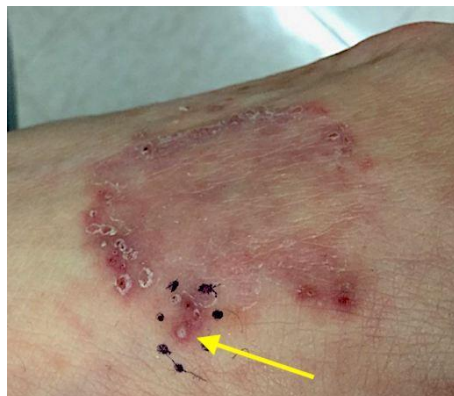See -

Hand Surgery Source

Version 2.0

Launches for January, 2020!

Version 2.0 includes **18 new** diagnostic guides with many new skin related guides. For example –

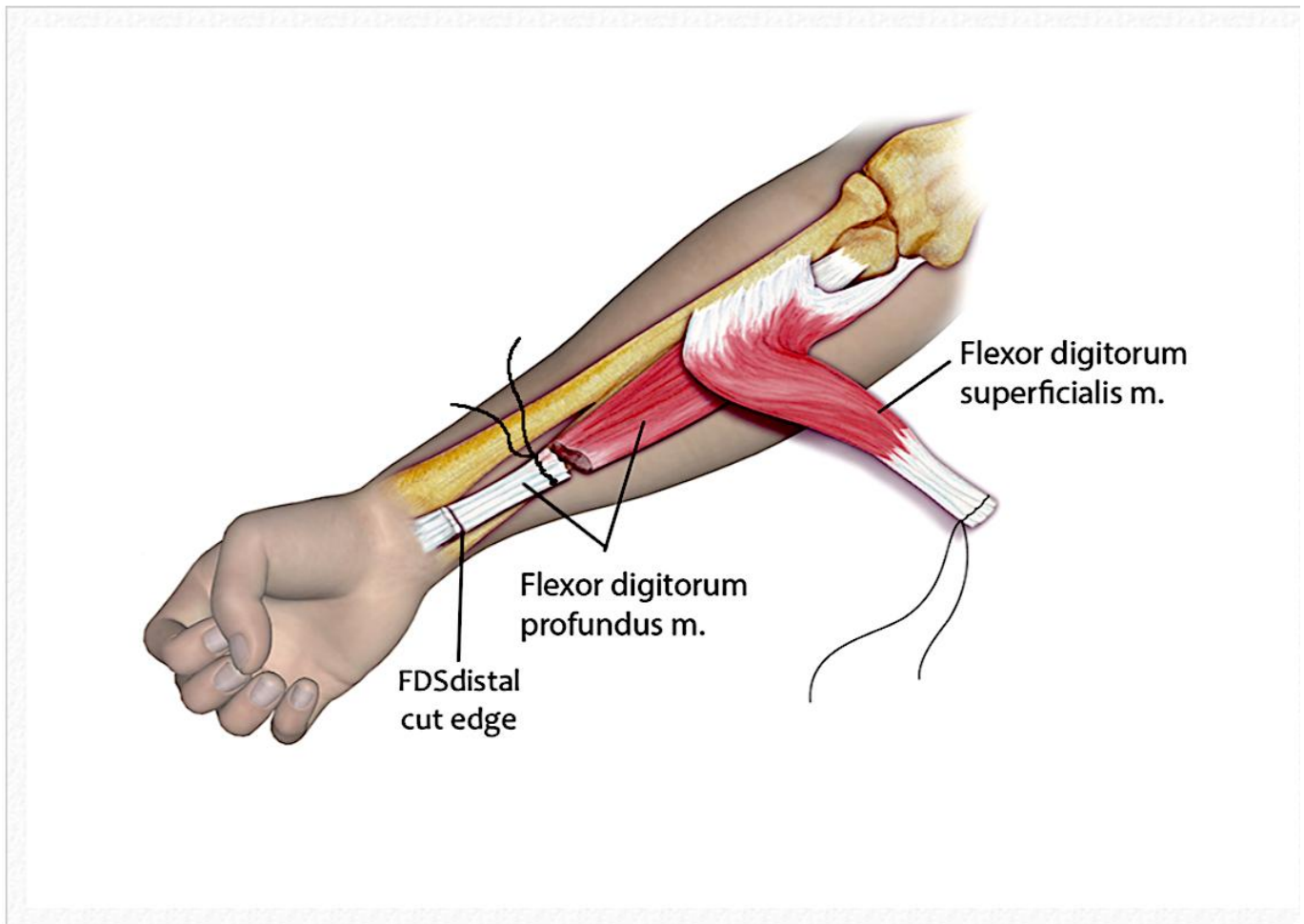


Dermatophytosis (Tinea Manuum) on dorsal right hand (arrow)

**Hand Surgery Source 2.0 adds 164 new references
and 207 new Pub Med links.**

In addition, **Version 2.0 adds 56 new images and 1 new video** to the visual learning opportunities available at **Hand Surgery Source**

For example-



The first step of a Superficialis to Profundus Transfer is to suture all four FDS tendons together and all four FDP tendons together before cutting the FDS tendons distally and the FDP tendons proximally. The FPL (not shown) requires z-lengthening.

Hand Surgery Source VERSION 2.0

contains:

- **250 diagnostic guides sections**
- **160 exams, tests and signs sections**
- **25 diagnostic studies sections**

- **2,156 photos** and drawings make visualizing the teaching points easy
 - **123 videos** also support the text
- Hand Surgery Source content is supported by **3,897 references** and **3,209 direct links to PubMed.**
- **A Strong Search Option for Hand Surgery Source**

So what are you waiting for –
Become a registered user now and
Take advantage of potential rewards
During our Campaign 2020.
Sign up for FREE today.